



THE 31ST MEETING OF THE
EUROPEAN SOCIETY & COLLEGE
OF VETERINARY PATHOLOGISTS
LONDON 2013

**31st Meeting of the
European Society of Veterinary Pathology
and the
European College of Veterinary Pathologists
4th – 7th September 2013**

Programme

**The Institute of Education
University of London
London, UK**



Brighten up your day

with Abcam cell
imaging reagents

CytoPainter kits

Fluorescent dyes

Secondary antibodies

Discover more at abcam.com/multicolor



Image courtesy of an Abreview by Dr. Shaohua Li, UMDNJ-Robert Wood Johnson Medical School

abcam[®]
discover more

Table of Contents

Welcome	4
Committees	5
General Information	6
Floor Plans	10
Social Events	12
Sponsors	14
Programme Overview	15
Programme	19
Keynote Lectures	30
Keynote Lecturers - Biographies	39
Oral Presentations	
Session A: Degenerative & Infectious Disease	44
Session B: Infectious Disease	51
Session C: Infectious Disease	55
Session D: Infectious, Wildlife & Neoplastic Disease	61
Session E: Neoplastic Disease	67
Session F: Neoplastic Disease	75
Session G: Cardiovascular & Forensic Disease	79
Session H: Inflammatory, Skin & Wildlife Disease	85
Poster Abstracts	
Degenerative Disease	91
Infectious Disease	100
Neoplastic Disease	142
Other	189
Wildlife Disease	223
Other (late submission)	231
ISVD Mystery Slide Session	232

Dear Friends and Colleagues

On behalf of the scientific and local organising committees and the Royal Veterinary College, it is a pleasure and honour to welcome you to the 31st meeting of the European Society of Veterinary Pathology (ESVP), a joint event with the European College of Veterinary Pathologists (ECVP).

As at previous joint meetings of the Society and College the London 2013 conference aims to provide an ideal setting for both experienced pathologists and trainees travelling from the UK, Europe and further afield to have an opportunity to update their knowledge on recent scientific developments, exchange experiences, make new friends and have an enjoyable stay in one of the most exciting cities in the world.

The conference has a full programme of keynote sessions with internationally renowned veterinary and medical speakers. These sessions will be complemented by oral communications, posters and an interactive slide session. We are particularly pleased that less experienced pathologists are able to make their first oral presentations in an encouraging and supportive environment and prizes will be awarded for the best oral communications and posters.

Other sessions include:

A Workshop on Scientific Writing - "Top Tips for Publishing Case Reports in the Journal of Comparative Pathology and the Journal of Veterinary Internal Medicine" - covering the key points to consider in preparing and submitting a manuscript for publication.

Test your Diagnostic Skills in Veterinary Neuropathology - an interactive workshop involving a series of 'What is your diagnosis' challenges in neuropathology, using cases from an extensive archive.

European Pathosurveillance Network - sessions are open to all delegates, especially those who are currently engaged in diagnostic investigation, research or training in farm animal pathology.

International Society of Veterinary Dermatopathology (ISVD) - including the ever popular "Mystery Slide Sessions".

Socially, there will be ample opportunity for you to explore London; the conference venue is in London's fashionable Bloomsbury district, close to Russell Square and the British Museum, where there are a wealth of cultural and historic places of interest, shops and entertainment venues a short walk away.

The organisation of this conference would not have been possible without the generous support from sponsors and exhibitors. I would like to thank them all very much and I urge you to visit the exhibitions.

Finally, I would like to thank all of the colleagues in the ESVP and ECVP who have contributed freely of their time and expertise in making this conference possible. I am especially grateful to the Local Organising Committee, ESVP/ECVP Scientific Committee, ECVP Council and ESVP Council. Enjoy London!

Ken Smith, Chairman of the Local Organising Committee



Committees

ESVP Council

Roderick Else (President), University of Edinburgh (Great Britain)
 Sanja Aleksic-Kovacevic, University of Belgrado (Serbia)
 Cinzia Benazzi, University of Bologna (Italy)
 Felix Ehrensperger, University of Zürich (Switzerland)
 Juan Francisco García Marín, University of León (Spain)
 Carl Härd af Segerstad, National Veterinary Institute, Uppsala (Sweden)
 Ken Smith, Royal Veterinary College, University of London (Great Britain)
 Jacob Walter, Bayer Schering Pharma AG, Berlin (Germany)

ECVP Council

Mona Aleksandersen, (President), University of Oslo, (Norway)
 Chiara Brachelente, Perugia (Italy)
 Sean Callanan, University of Dublin (Ireland)
 Flavio Crameri, Basel (Switzerland)
 Anja Kipar, University of Liverpool (Great Britain) and University of Helsinki (Finland)
 Xavier Palazzi, Alfortville (France)
 Laura Peña, University of Madrid (Spain)
 Gabriele Pohlmeyer-Esch, Saint Louis (France)
 Paola Roccabianca, University of Milan (Italy)

ESVP/ECVP Scientific Committee

Lluís Luján, (Chairperson), University of Zaragoza (Spain)
 Sean Callanan, University College of Dublin (Ireland)
 Ken Smith, Royal Veterinary College, University of London (Great Britain)
 Roderick Else, University of Edinburgh (Great Britain)
 Juan Francisco García Marín, University of León (Spain)
 Federico Valenza, University of Torino (Italy)
 Achim Gruber, University of Berlin (Germany)

Local Organising Committee

Ken Smith, (Chairperson), Royal Veterinary College, University of London (Great Britain)
 Simon Priestnall, Royal Veterinary College, University of London (Great Britain)
 Henny Martineau, Royal Veterinary College, University of London (Great Britain)
 Norelene Harrington, Royal Veterinary College, University of London (Great Britain)
 Bevan McWilliam, Royal Veterinary College, University of London (Great Britain)
 Cheryl Scudamore, MRC Harwell (Great Britain)
 Sue Lyons, VPEC Organisation Ltd (Great Britain)



General Information

Conference Venue

The Institute of Education (IOE)
20 Bedford Way
London WC1H 0AL
Tel: +44 (0)20 7612 6000

All sessions (except the ESPN sessions) will be held on the lower ground floor (Level 1) where the ESVP/ECVP will have exclusive use. The ESPN sessions will be held on Level 3.

Access is available for those with limited mobility.

Official language

The official language of the conference is English.

Registration and Conference Secretariat

The registration desk will open at the IOE, Level 1 on Wednesday 4th September. From 4th September the Conference Secretariat (including registration) will be located on Level 1 for the duration of the conference.

Conference Dates and Opening Hours

Wednesday 4th September 2013	16.30 – 20.30
Thursday 5th September 2013	08.00 – 18.00
Friday 6th September 2013	08.00 – 17.00
Saturday 7th September 2013	08.00 – 12.30

All presentations will start at 08.30.

Contact: Conference Secretariat - 07710 547770 or email: esvp2013@gmail.com

WiFi

Free WiFi is available on Level 1 (Jeffery Hall, the Drama Studio, Elvin Hall and all the foyer areas):

SSID: VeterinaryWiFi
Password: London2013

Environmental Impact

The Local Organising Committee have sought to reduce the environmental impact of this conference by not providing conference specific materials such as lanyards, delegate bags, etc., and have reduced the size of the (paper) conference programme/abstract booklet.



General Information

Conference Programme

An abridged conference booklet will be available to all delegates on arrival at the meeting containing the programme details and abstracts for the keynote lectures. A full copy of the programme, including abstracts of oral and poster presentations will be available electronically, on a USB memory stick, provided by **The Journal of Comparative Pathology**: <http://www.journals.elsevier.com/journal-of-comparative-pathology>

The full conference programme, including abstracts, will be available on the “members only area” of the ESVP and ECVP websites.

The full conference programme, including abstracts, will also be available to non-members of the ESVP and ECVP websites by Dropbox: <https://www.dropbox.com>

Name Badges

Your name badge is your admission to the scientific sessions and to refreshment breaks and lunches. Name badges should be worn at all times whilst at the conference venue.

Delegate bags

Delegate bags provided by **Abcam**: <http://www.abcam.com>

Delegate Materials

Pens and notepads provided by **Kaleidis**: gpe@kaleidis-consultancy.com

Presentations

Presentations should be handed to the Conference Secretariat on morning of your talk.

Posters

The poster area will be located in The Drama Studio and Crush Hall.

Poster viewing times are detailed in the programme. Posters may be mounted from 16.30 to 20.30 on Wednesday 4th September and from 08.00 - 08.30 on Thursday 5th September. All posters must be taken down by 12.30 on Saturday 7th September.

The organisers will not accept any responsibility for posters that are not removed in time.

Poster panels provided by: <http://www.x-hibit.com>



General Information

Exhibition/Sponsors

Abcam and **Leica** will be located in the Crush Hall area of Level 1. The exhibitors are supporting the conference and we encourage you to go along and speak to them.

Refreshment Breaks and Lunches

Refreshments and lunches will be served in Crush Hall and Jeffery Hall Foyer at times detailed in the programme. You may need to show your name badge as a ticket for refreshments.

Currency and Banking

GBP is the official currency in the UK.

Currency can be exchanged from most banks and Post Offices as well as the network of Bureaux de Change located throughout London. Major international credit cards are accepted in most hotels, shops and restaurants.

Electricity

In the UK the electrical voltage used is 230v.

Smoking

Smoking is not allowed in the conference venue or in any other public indoor establishments such as restaurants and bars etc.

International Calls

Dial 00 + country code + area code + phone number i.e. to the US dial 00 1 +, to Germany dial 00 49 +.

Tourist Information

There are Tourist Information Centres all over London. You can pick up free brochures and maps, and buy London guide books. You can also book theatre, tour and attractions tickets at some Tourist Information Centres. The nearest Tourist Information Centres to the IOE are the King's Cross St Pancras Travel Information Centre; the Euston Travel Information Centre and the Holborn Information Kiosk.



General Information

Emergency Services and Medical Care in London

The National Health Service (NHS) is the main healthcare provider in the UK. NHS treatment is free for UK residents. Overseas nationals are not eligible for free NHS treatment except if they need emergency treatment while in the UK.

If you come from a country that holds a UK healthcare agreement, you are entitled to free or reduced-cost medical treatment if needed immediately for a condition that started after your arrival in the UK.

If you're visiting from Europe, you should carry a valid EHIC (European Health Insurance Card) in case you need immediate and necessary medical treatment in an NHS hospital. Without this you can be charged for treatment.

There are a large number of pharmacies in London, the main ones being "Lloyds Pharmacy" and "Boots".

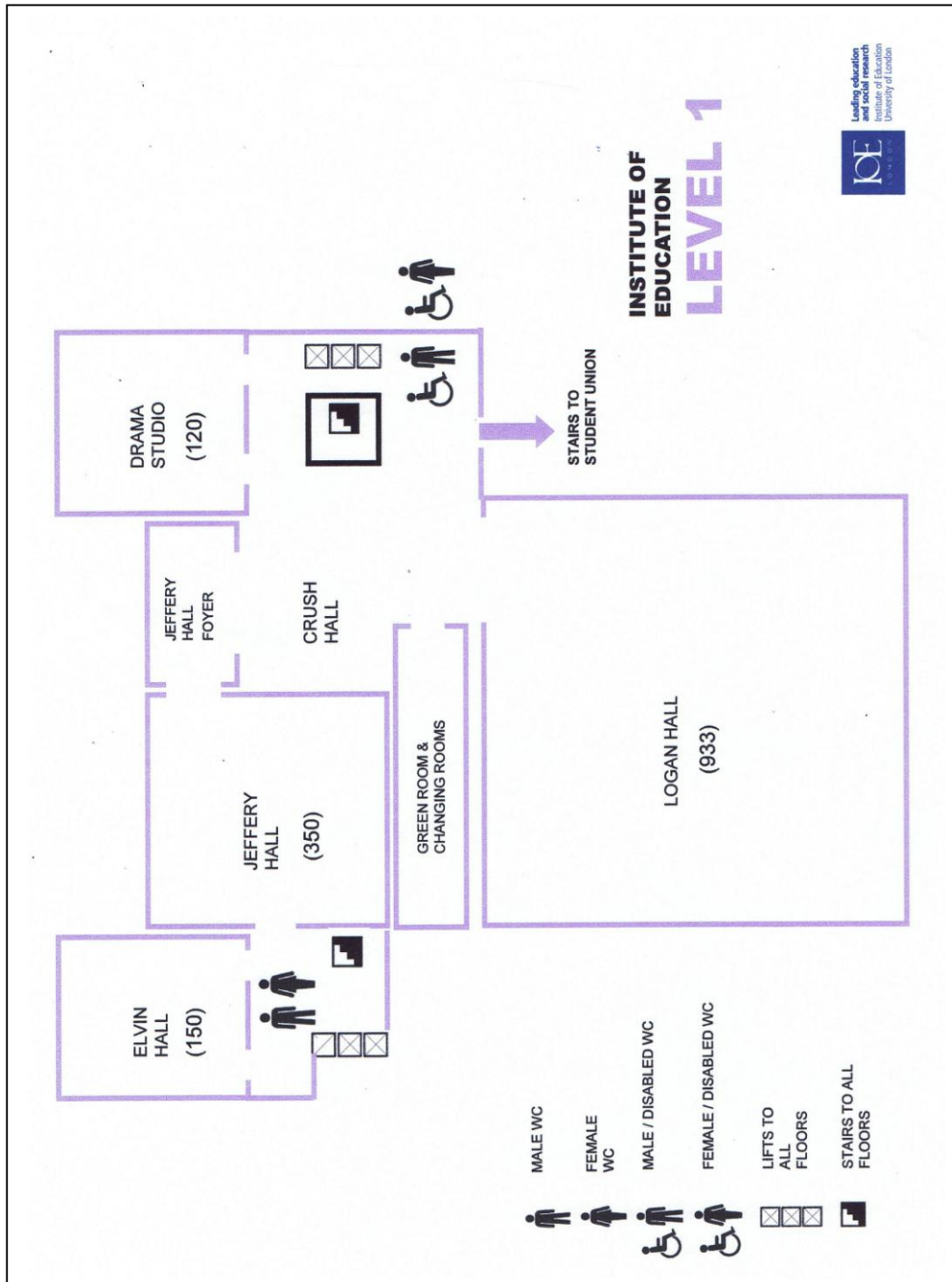
In the UK call 112 or 999 for the emergency services (police, fire and ambulance).



THE 31ST MEETING OF THE
EUROPEAN SOCIETY & COLLEGE
OF VETERINARY PATHOLOGISTS
LONDON 2013

10:

Floor Plan – Level 1

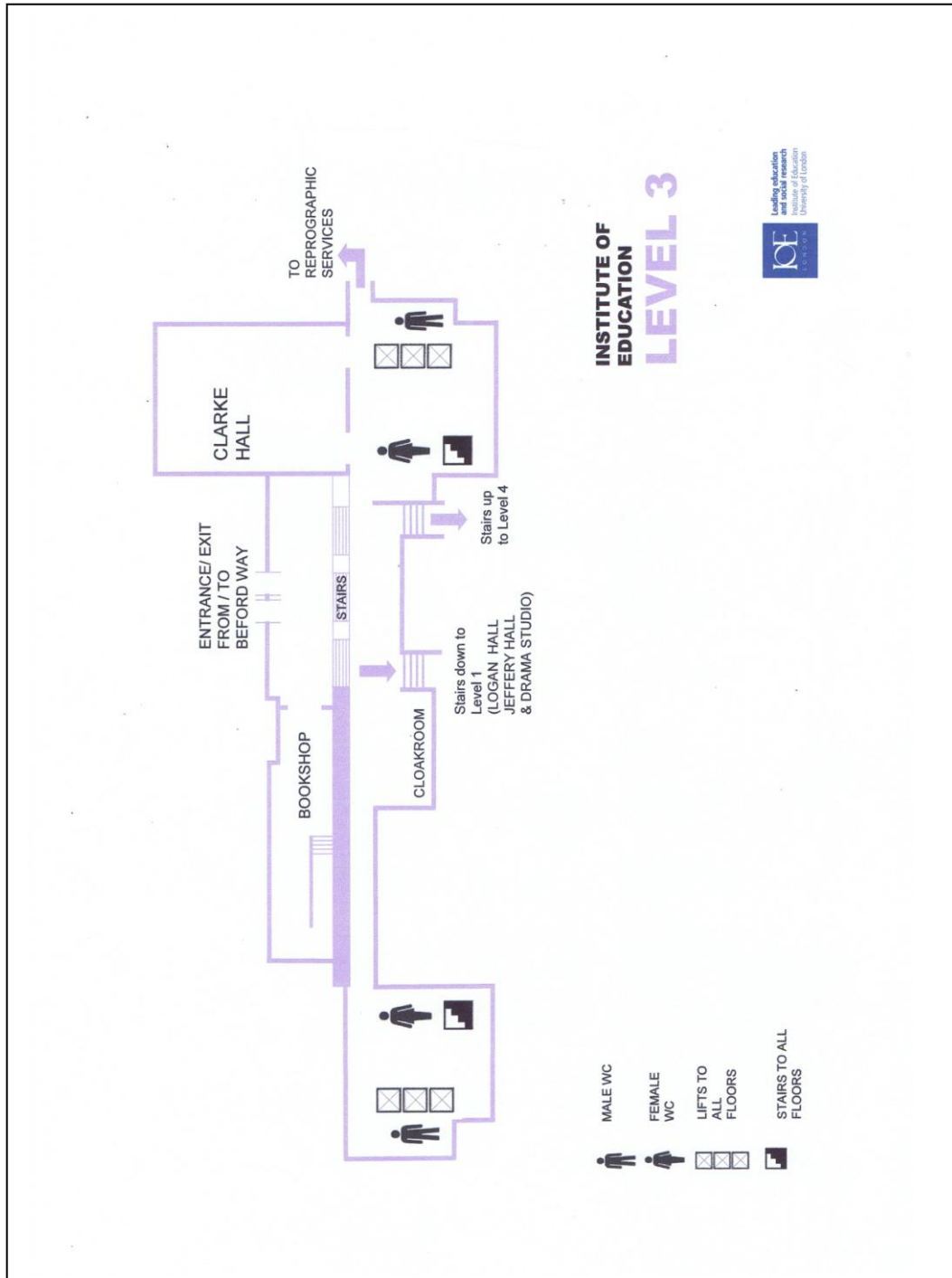




THE 31ST MEETING OF THE
EUROPEAN SOCIETY & COLLEGE
OF VETERINARY PATHOLOGISTS
LONDON 2013

11:

Floor Plan – Level 3



Social Events

The Opening Ceremony for the conference will take place in Jeffery Hall, Level 1 at the IOE on **Wednesday 4th September at 18.30** with the **Welcome Reception** following on immediately afterwards (*this is a pre-booked event*).



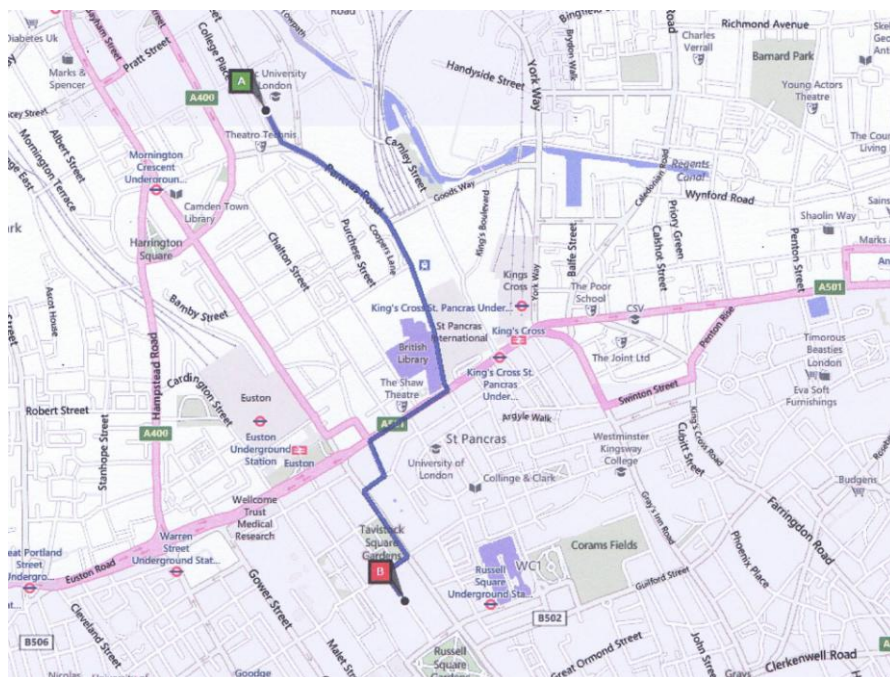
Visit to the Royal Veterinary College (*this is a pre-booked event*). During this tour you will learn how the Veterinary College, London, was born in 1791, and how during the first 100 years of its existence the College progressed from a horse infirmary with a handful of students to a science based institution, producing veterinarians and scientists with reputations acknowledged all over the world.

The Royal Veterinary College, Royal College Street, London is situated in Camden. The Camden Campus itself is within

walking distance from Kings Cross, St Pancras and Euston train stations, and Mornington Crescent and Camden Town Underground Stations.

On **Thursday 5th September at 19.00** you need to arrive at the front door of the RVC where you will be met and taken on a tour to hear about the foundation of The Veterinary College, London, in 1791.

The RVC is approximately 2 km from the Institute of Education (IOE), with the IOE marked **A** and the RVC marked **B**.

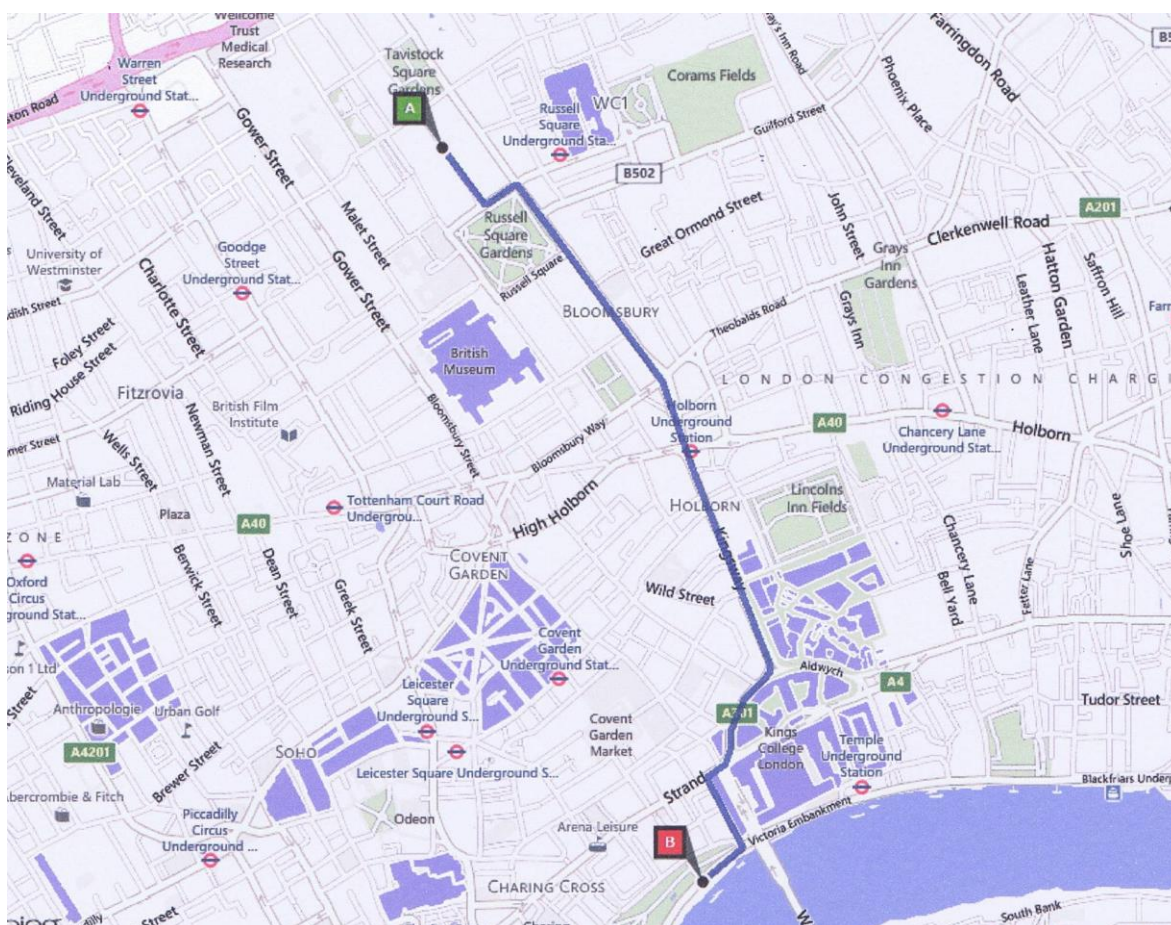


Social Events

The **Conference Dinner** (*this is a pre-booked event*) on board the **Silver Sturgeon**, will take place on **Friday 6th September 2013**. You will be picked up by coach from the IOE at 17.45 with boarding of the Silver Sturgeon starting at 18.30 hours; the boat will depart from its moorings at the Savoy Pier at 19.00 hours. You will sail up and down the River Thames, where you will be treated to a unique moving luxurious setting to view the sights of London such as the Houses of Parliament, the London Eye, the South Bank, Tower Bridge, Canary Wharf, Greenwich and the Thames Barrier, whilst enjoying a three course dinner which celebrates great British produce. You will return at approximately 22.00 hours with disembarkation completed by 22.30. You will be required to make your own way back to your hotel from the Savoy Pier.



The Savoy Pier, on the Thames Embankment, near to Cleopatra's Needle is approximately 2.1 km from the Institute of Education (IOE), with the IOE marked **A** and the Savoy Pier marked **B**.



Thank you to our sponsors

abcam[®]
discover more

Beaufort Cottage Laboratories

 **ROSSDALES**
VETERINARY SURGEONS

Journal of Comparative
Pathology

ELSEVIER

IDEXX
LABORATORIES

KALEIDIS 
Consultancy in Histopathology

Leica
BIOSYSTEMS

Pixel.2
print digital printing

 The Royal College of **Pathologists**
Pathology: the science behind the cure

RVC Royal
Veterinary
College
University of London

XHIBIT
EXHIBITION DISPLAY SOLUTIONS



RVC Royal
Veterinary
College
University of London

Programme Overview

Wednesday 4th September 2013

16.30	Registration
18.30	Opening Ceremony
19.00	Opening Reception

Thursday 5th September 2013

08.00 - 08.30	Registration		
08.30 - 10.00	Keynote Lecture 1: The role of the pathologist in biosecurity <i>Location: Jeffery Hall</i>		
10.00 - 10.30	Refreshments <i>Location: Crush Hall & Jeffery Hall Foyer</i>		
10.30 - 11.30	Poster Viewing <i>Location: The Drama Studio and Crush Hall</i>		
10.30 - 11.30	A Workshop on Scientific Writing <i>Location: Jeffery Hall</i>	Oral Presentations - Session A - <i>Location: Elvin Hall</i>	European Pathosurveillance Network <i>Location: Clarke Hall</i>
11.30 - 12.30	Oral Presentations - Session B <i>Location: Jeffery Hall</i>		
12.30 - 13.30	Lunch <i>Location: Crush Hall & Jeffery Hall Foyer</i>		
13.30 - 15.00	Keynote Lecture 2: Orthopaedic pathology in athletes <i>Location: Jeffery Hall</i>		
15.00 - 15.30	Refreshments <i>Location: Crush Hall & Jeffery Hall Foyer</i>		
15.30 - 17.00	Poster Viewing <i>Location: The Drama Studio and Crush Hall</i>		
15.30 - 17.00	Oral Presentations - Session C <i>Location: Jeffery Hall</i>	Oral Presentations - Session D <i>Location: Elvin Hall</i>	European Pathosurveillance Network <i>Location: Clarke Hall</i>
17.00 - 18.00	ECVP AGM & new ECVP Diplomate Awards <i>Location: Jeffery Hall</i>		
19.00 - 21.00	Visit to the Royal Veterinary College		

Programme Overview

Friday 6th September 2013

08.30 - 09.45	Keynote Lecture 3: Tuberculosis <i>Location: Jeffery Hall</i>	
09.45 - 10.10	Refreshments <i>Location: Crush Hall & Jeffery Hall Foyer</i> Poster Viewing <i>Location: The Drama Studio and Crush Hall</i>	
10.10 - 11.10	Test your diagnostic skills in veterinary neuropathology <i>Location: Jeffery Hall</i>	Oral Presentations - Session E <i>Location: Elvin Hall</i>
11.10 - 12.10	Oral Presentations - Session F <i>Location: Jeffery Hall</i>	
12.10 - 13.05	Lunch <i>Location: Crush Hall & Jeffery Hall Foyer</i>	
13.05 - 14.20	Keynote Lecture 4: Pathology in rabbits and hares <i>Location: Jeffery Hall</i>	
14.20 - 14.45	Refreshments <i>Location: Crush Hall & Jeffery Hall Foyer</i> Poster Viewing <i>Location: The Drama Studio and Crush Hall</i>	
14.45 - 16.15	Oral Presentations - Session G <i>Location: Jeffery Hall</i>	Oral Presentations - Session H <i>Location: Elvin Hall</i>
16.15 - 17.00	ESVP AGM <i>Location: Jeffery Hall</i>	
18.30 - 22.30	Conference Dinner onboard the Silver Sturgeon <i>Location: Savoy Pier</i>	

Programme Overview

Saturday 7th September 2013

08.30 - 09.30	Keynote Lecture 5: Papillomaviruses in people and animals <i>Location: Jeffery Hall</i>
09.30 - 10.10	British Society of Veterinary Pathology (BSVP) AGM <i>Location: Jeffery Hall</i>
11.10 - 10.40	Refreshments <i>Location: Crush Hall & Jeffery Hall Foyer</i> Final Poster Viewing <i>Location: The Drama Studio and Crush Hall</i>
10.40 - 11.40	Prize Giving and Closing Ceremony <i>Location: Jeffery Hall</i>
11.40 - 12.30	Poster Board Take-down <i>Location: The Drama Studio and Crush Hall</i>

Programme Overview

Saturday 7th September 2013

<i>International Society of Veterinary Dermatopathology (ISVD)</i>	
09.30 - 09.40	Introduction: Judith Nimmo, President ISVD <i>Location: Elvin Hall</i>
09.40 - 09.55	Mystery Slide Session: Judith Nimmo <i>Location: Elvin Hall</i>
09.55 - 10.10	Mystery Slide Session: Christina McCowan <i>Location: Elvin Hall</i>
10.10 - 10.40	Refreshments <i>Location: Crush Hall & Jeffery Hall Foyer</i>
10.40 - 10.55	Mystery Slide Session: Dominique Wiener <i>Location: Elvin Hall</i>
10.55 - 11.10	Mystery Slide Session: Judith Nimmo <i>Location: Elvin Hall</i>
11.10 - 11.25	Mystery Slide Session: Monika Welle <i>Location: Elvin Hall</i>
11.25 - 11.40	Mystery Slide Session: Nadine Meertens <i>Location: Elvin Hall</i>
11.40 - 11.55	Mystery Slide Session: Verena Affolter <i>Location: Elvin Hall</i>
11.55 - 12.10	Mystery Slide Session: Emily Walder <i>Location: Elvin Hall</i>
12.10 - 12.25	Mystery Slide Session: Emily Walder <i>Location: Elvin Hall</i>
12.25 - 14.00	Lunch
14.00 - 15.30	State of the Art Lecture: "The Hair Follicle – a Mammalian Regenerative Tool Kit?" <i>Location: Elvin Hall</i>
15.30 - 16.00	Refreshments <i>Location: Crush Hall & Jeffery Hall Foyer</i>
16.00 - 16.30	Sebaceous gland topic: Sebaceous dysplasia/dysplasia and Sebaceous tumours <i>Location: Elvin Hall</i>
16.30 - 17.00	Hot Topics: Review of selected recent topical journal articles <i>Location: Elvin Hall</i>
17.00 - 18.00	Short Communications: Gaucher lamb ichthyosis; Histiocytic vasculitis associated with pulmonary nematode larvae; and Porocarcinoma in a dog <i>Location: Elvin Hall</i>

Programme

Thursday 5th September 2013

Location: Jeffery Hall, Level 1

08.30 - 10.00 **Keynote Lecture 1: The role of the pathologist in biosecurity**

Chair: Simon Priestnall and Sandra Scholes

Welcome from Neil Smith - President of the Royal College of Veterinary Surgeons, UK

Royal College of Pathologists Kettle and Cameron Lectures

Introduced by Archie Prentice, President of the Royal College of Pathologists, UK

BETWEEN THE DEVIL AND THE DEEP BLUE SEA: PREPARING FOR DISEASE EMERGENCE FROM WILDLIFE

Karrie Rose, Taronga Conservation Society, Australia

THE PATH TO A HENDRA VIRUS VACCINE FOR HORSES "...CHANCE FAVOURS ONLY THE PREPARED MIND" PASTEUR 1854

Deborah Middleton, CSIRO Australian Animal Health Laboratory, Australia

10.00 - 10.30 **Refreshment Break and Poster Viewing**

10.30 - 11.30 **A Workshop on Scientific Writing - "Top Tips for Publishing Case Reports in the Journal of Comparative Pathology and the Journal of Veterinary Internal Medicine"**

Chair: Geoff Pearson

Scientific writing: Manuscript preparation

Dr Stephen DiBartola, Co-editor-in-chief of the Journal of Veterinary Internal Medicine, USA

Top Tips for Publishing Case Reports in the Journal of Comparative Pathology

Professor Michael Day, Editor-in-chief of the Journal of Comparative Pathology, UK

11.30 - 11.45 **Oral Presentations - Session B: Infectious Disease**

Chair: Achim Gruber and Andrea Gröne

EQUINE INFECTIOUS DISEASE VIRUS INDUCED PULMONARY INTERSTITIAL DAMAGE. WHAT ABOUT AEROSOL TRANSMISSION?

P. Bolf, J. L. Cadore, J. F. Mornex, C. Catoi, A. Gal, M. Taulescu and C. Leroux

11.45 - 12.00 **THE NOVEL HUMAN CORONAVIRUS-EMC CAUSES DISEASE IN MACAQUES BUT NOT IN FERRETS**

J.M.A. van den Brand, L. Wiersma, S.L. Smits, L. Provacia, V.S. Raj, A.D.M.E. Osterhaus, T. Kuiken and B.L. Haagmans



Programme

Thursday 5th September 2013

Location: Jeffery Hall, Level 1

- 12.00 - 12.15 **ACTIVATION OF THE EXTRINSIC PATHWAY OF APOPTOSIS DURING PRRS**
I.M. Rodríguez-Gómez, I. Barranco, S.P. Amarilla, J. Gómez-Laguna, O. García-Nicolás, G. Ramis, F.J. Pallarés and L. Carrasco
- 12.15 - 12.30 **LESIONS IN PERIPHERAL ORGANS OF RUMINANTS INFECTED WITH SCHMALLENBERG VIRUS**
F. Seehusen, V. Herder, M. Weigand, K. Hahn, A. Habierski, I. Gerhauser, P. Wohlsein, M. Peters, M. Varela, M. Palmarini and W. Baumgärtner
- 12.30 - 13.30 **Lunch**
- 13.30 - 15.00 **Keynote Lecture 2: Tendon pathology in human and animal athletes**
Chair: Ken Smith and Federico Valenza
- Sponsored by Beaufort Cottage Laboratories**
- TENDON PATHOLOGY IN HUMAN AND ANIMAL ATHLETES**
Janet Patterson-Kane, University of Glasgow, Scotland
- TENDON PATHOLOGY IN (HUMAN) ATHLETES**
Graham Riley, University of East Anglia, UK
- 15.00 - 15.30 **Refreshment Break and Poster Viewing**
- 15.30 - 15.45 **Oral Presentations - Session C: Infectious Disease**
Chair: Sionagh Smith and Richard Blundell
- MICROSCOPIC BRAIN LESIONS IN DOGS WITH VISCERAL LEISHMANIASIS**
G.D. Melo, F.G. Grano, J.E.S. Silva, J.M. Silva, A. Schweigert, A.T. Ramos, I.M. Langohr and G.F. Machado
- 15.45 - 16.00 **CUTANEOUS MYCOBACTERIUM AVIUM COMPLEX INFECTION IN CATS ORIGINATING FROM THE ISLAND OF HVAR CROATIA**
A. Beck, S. Špičić, I. Račić, I.C. Šoštarić – Zuckermann, A. Gudan Kurilj, Ž. Grabarević, Ž. Cvetnić and R. Beck
- 16.00 - 16.15 **EVIDENCE FOR THE ROLE OF A SHREW SPECIES AS RESERVOIR HOST OF BORNA DISEASE VIRUS IN EASTERN GERMANY**
H. Weissenböck, R. Dürrwald, J. Kolodziejek and N. Nowotny



Programme

Thursday 5th September 2013

Location: Jeffery Hall, Level 1

- 16.15 - 16.30 **MICROARRAY ANALYSIS OF CANINE DISTEMPER VIRUS-INDUCED DEMYELINATING LEUKOENCEPHALITIS**
R. Ulrich, C. Puff, K. Wewetzer, A. Kakuhl, U. Deschl and W. Baumgärtner
- 16.30 - 16.45 **EDEMA DISEASE: APOPTOTIC PANCREATOPATHY?**
J. F. Edwards and T. Conner
- 16.45 - 17.00 **HAEMORRHAGIC SYNDROME IN CATTLE BY SUBGENOTYPE BVDV-1h**
V. Di Marco Lo Presti, G. Purpari, E. Biasibetti, M. T. Capucchio, V. Cannella, P. Di Marco, F. Mira, G. Guarneri, M. Fiasconaro, B. Amato and A. Guercio
- 17.00 - 18.00 **ECVP AGM & new ECVP Diplomate Awards**

Programme

Thursday 5th September 2013

Location: Elvin Hall, Level 1

10.30 - 10.45 **Oral Presentations - Session A: Degenerative & Infectious Disease**

Chair: Felix Ehrensperger and Anja Kipar

THE PATHOLOGY ASSOCIATED WITH IDIOPATHIC ARTERIAL ANEURYSM/RUPTURE IN HOLSTEIN/FRIESIAN CATTLE

M. Wessels, T. Crawshaw, F. Howie, A. Patterson and N. Peperkamp

10.45 - 11.00 **A MULTIPLE APPROACH TO INVESTIGATE THE AETIOPATHOGENESIS OF LIPOMATOUS MUSCULAR DYSTROPHY IN PIEDMONTESE CATTLE**

E. Biasibetti, S. Peletto, P. Acutis, C. Boin, F. Schiavini, A. Bagnato and M.T. Capucchio

11.00 - 11.15 **A NOVEL, IDIOPATHIC, SUPERFICIAL NEOCORTICAL DEGENERATION AND ATROPHY IN YOUNG ADULT DOGS**

S. D. Cahalan, R. Cappello, A. de Lahunta and B. A. Summers

11.15 - 11.30 **DE NOVO HLA-DR EXPRESSION IN CANINE RENAL TUBULAR EPITHELIUM: A POSSIBLE EVENT IN EPITHELIAL-MESENCHYMAL-TRANSITION**

SL Benali, GE Lees, MB Nabity, F Bonsembiante and L Aresu

11.30 - 11.45 **GENERATION AND CHARACTERIZATION OF A PORCINE MODEL OF DUCHENNE MUSCULAR DYSTROPHY**

A. Blutke, N. Klymiuk, A. Graf, S. Krause, K. Burkhardt, A. Wuensch, S. Krebs, B. Kessler, V. Zakhartchenko, M. Kurome, E. Kemter, H. Nagashima, B. Schoser, N. Herbach, H. Blum, R. Wanke, C. Thirion, H. Lochmüller, M. C. Walter and E. Wolf

11.45 - 12.00 **CRYPTOSPORIDIAL INFECTIONS IN CAPTIVE TORTOISES**

B. Richter, M. Brinkmeier, M. Globokar Vrhovec, N. Nedorost and N. Pantchev

12.00 - 12.15 **CANINE DISTEMPER VIRUS INFECTION LEADS TO REDUCED ANTIGEN PRESENTING FUNCTION OF MONOCYTE-DERIVED DENDRITIC CELLS**

A. Beineke, V. Qeska, Y. Barthel, M. Iseringhausen, C. Urhausen, V.M. Stein, A. Tipold and W. Baumgärtner

12.15 - 12.30 **NUTRITIONAL DEGENERATIVE CARDIOMYOPATHY IN DOGS: A PRELIMINARY REPORT**

G. Daniel-Igwe and E. O. Onyekweodiri - CANCELLED - UNABLE TO ATTEND

Programme

Thursday 5th September 2013

Location: Elvin Hall, Level 1

15.30 - 15.45 **Oral Presentations - Session D: Infectious, Wildlife & Neoplastic Disease**

Chair: Lluís Lujan and Wolfgang Baumgaertner

CENTRAL NERVOUS SYSTEM PATHOLOGY IN INFECTIOUS DISEASES OF CETACEANS STRANDED ON THE CATALAN MEDITERRANEAN SEA (1990-2013)

M. Isidoro, S. Soto, L. Pérez, X. Cabañes and M. Domingo

15.45 - 16.00 **CENTRAL NERVOUS SYSTEM ZYGOMYCOSIS IN A BOTTLENOSE DOLPHIN (*TURSIOPS TRUNCATUS*) CAUSED BY *CUNNINGHAMELLA BERTHOLLETIAE***

M. Isidoro, L. Pérez, X. Cabañes, G. Castellà, M. Andrés and M. Domingo

16.00 - 16.15 **C-KIT PATTERN EXPRESSION ANALYSIS IN EQUINE MAST CELL TUMOURS**

S. Ward, A. Kipar and L. Ressel

16.15 - 16.30 **ANALYSIS OF PROGESTERONE RECEPTOR ISOFORMS AND PROLIFERATION IN CANINE MAMMARY CARCINOMAS TREATED WITH THE ANTIPROGESTIN RU534**

S. Guil-Luna, J. Stenvang, N. Brünner, R. Sánchez-Céspedes, Y. Millán and J. Martín de las Mulas

16.30 - 16.45 **EXPRESSION OF SOX9 AND SNAIL2 IN CANINE MAMMARY TUMOURS**

L. Pritchard, G. Beha, K. Smith, B. Brunetti, G. Sarli, C. Benazzi and I. McGonnell

16.45 - 17.00 **CONSENSUS PROPOSAL ON ESSENTIAL PHENOTYPE MARKERS AND HORMONE RECEPTOR ASSESSMENT IN CANINE MAMMARY TUMORS.**

L. Peña, A. Gama, M. Goldschmidt, J. Abadie, C. Benazzi, M. Castagnaro, L. Díez, F. Gartner, E. Hellmen, M. Kiupel, Y. Millán, M. Miller, F. Nguyen, A. Poli, G. Sarli, V. Zappulli and J. Martín de las Mulas

Programme

Thursday 5th September 2013

Location: Clarke Hall, Level 3

10.30 - 12.30 **European Pathosurveillance Network**
Chair: Sandra Scholes

EPSN sessions are open to all delegates registered for the ESVP/ECVP Congress who are currently engaged in diagnostic investigation, research or training in farm animal pathology.

15.30 - 18.00 **European Pathosurveillance Network**
Chair: Sandra Scholes

EPSN sessions are open to all delegates registered for the ESVP/ECVP Congress who are currently engaged in diagnostic investigation, research or training in farm animal pathology.

Programme

Friday 6th September 2013

Location: Jeffery Hall, Level 1

08.30 - 09.45 **Keynote Lecture 3: Tuberculosis in people and animals**

Chair: Henny Martineau and Michael Day

Sponsored by the Journal of Comparative Pathology

OF BADGERS AND MEN: VITAMIN D AND IMMUNITY TO MYCOBACTERIA

Adrian Martineau, Queen Mary University of London, UK

THE TUBERCULOUS GRANULOMA: INFERNO, PURGATORIO OR PARADISO?

Joseph Cassidy, University College Dublin, Ireland

09.45 - 10.10 **Refreshment Break and Poster Viewing**

10.10 - 11.10 **Test your diagnostic skills in veterinary neuropathology**

Chair: Manfred Reinacher

Professor Brian Summers lately retired from the Royal Veterinary College, UK

11.10 - 11.25 **Oral Presentations - Session F: Neoplastic Disease**

Chair: Antti Sukura and Erika Karlstam

MAMMARY TUMORS IN PET RABBITS (ORYCTOLAGUS CUNICULUS) CLASSIFICATION AND EPIDEMIOLOGY

Berit Baum and Marion Hewicker-Trautwein

11.25 - 11.40 **IGF-1R IS CORRELATED TO POOR SURVIVAL IN CANINE APPENDICULAR OSTEOSARCOMA AND COULD BE CONSIDERED A NEW PROGNOSTIC FACTOR**

L. Maniscalco, S. Lussich, E. Morello, M. Martano, F. Gattino, B. Biolatti, P. Buracco and De Maria Raffaella

11.40 - 11.55 **MAST CELL INFILTRATION AND KIT AND PROTEASE EXPRESSION DURING PROGRESSION OF A TRANSGENIC PROSTATE CANCER MURINE MODEL (TRAMP)**

González C, Armisén R, Stutzin A, Baez P, Landerer E, Paredes R, Contreras I and Muñoz C

11.55 - 12.10 **CREATING A CHIMERIC ANTIGEN RECEPTOR FOR CANCER IMMUNOTHERAPY IN DOGS**

S.M. Keller, M. Schjaerff, R. Rebhun and P.F. Moore - CANCELLED - UNABLE TO ATTEND

12.10 - 13.05 **Lunch**



Programme

Friday 6th September 2013

Location: Jeffery Hall, Level 1

13.05 - 14.20 **Keynote Lecture 4: Diseases of rabbits and hares**

Chair: Cheryl Scudamore and Adrian Philbey

LEPORID PATHOLOGY: RABBITS

Patricia Turner, University of Guelph, Canada

LEPORID PATHOLOGY IN HARES

Katherine E Whitwell, Equine Pathology Consultancy, Newmarket, UK

14.20 - 14.45 **Refreshment Break and Poster Viewing**

14.45 - 15.00 **Oral Presentations - Session G: Cardiovascular & Forensic Disease**

Chair: Carl Hård af Segerstad and Alex Brower

SOLID LIPID NANOPARTICLES AS ANTINEOPLASTIC DRUGS VEHICLES IN GLIOBLASTOMA MULTIFORME: IN VITRO AND IN VIVO PATHOLOGICAL EFFECTS

E.Biasibetti, L.Battaglia, M.Gallarate, E.Peira, D.Chirio, E.Muntoni, A.Valazza, M.Lanotte, PP.Panciani, C.Riganti, L.Annovazzi, V.Caldera, D.Schiffer and M.T.Capucchio

15.00 - 15.15 **SEROTONIN 2B RECEPTOR EXPRESSION IN CANINE CARDIAC DISEASE**

Sonja Fonfara, Udo Hetzel and Anja Kipar

15.15 - 15.30 **EFFECTS OF SKIN BARRIER DISRUPTIONS ON THE PENETRATION OF AHAPS-FUNCTIONALIZED SILICA NANOPARTICLES IN THE MOUSE**

A. Ostrowski, D. Nordmeyer, L. Mundhenk, J. Fluhr, C. Graf, E. Rühl and A. D. Gruber

15.30 - 15.45 **ESTABLISHING A RAT MODEL FOR PROLONGED CARDIAC ARREST: INFLUENCE OF ARREST DURATION ON HIPPOCAMPAL LESIONS**

S.Höglér, U.Teubenbacher, A.Janata, W.Weihls, I.A.M.Magnet, F.Ettl, F.Sterz and P.Schmidt

15.45 - 16.00 **FORENSIC CASES OF BRUISES IN PIGS**

K. Barington and H.E. Jensen

16.00 - 16.15 **AORTIC MEDIA ULTRASTRUCTURE IN A HEALTHY FRIESIAN HORSE AND IN A FRIESIAN HORSE WITH AORTO-PULMONARY FISTULA**

V. Saey, K. D'Herde, M. Ploeg, K. Chiers, C.J.G. Delesalle, A. Gröne, W. Back, C.M. de Bruijn, G. van Loon and R. Ducatelle

16.15 - 17.00 **ESVP AGM**



Programme

Friday 6th September 2013

Location: Elvin Hall, Level 1

10.10 - 10.25 **Oral Presentations - Session E: Neoplastic Disease**

Chair: Paola Roccabianca and Giancarlo Avallone

THE DOG AS A SPONTANEOUS MODEL TO STUDY MAMMARY MYOEPIHELIAL BASAL CELL LINEAGE AND ITS ROLE IN MAMMARY CARCINOGENESIS

R. Rasotto, M. Goldschmidt, M. Castagnaro, P. Carnier, D. Caliani and V. Zappulli

10.25 - 10.40 **HISTOLOGICAL GRADING OF CANINE MAST CELL TUMOUR: IS TWO BETTER THAN THREE?**

F. Scarpa, S. Sabattini, D. Berlato and G. Bettini

10.40 - 10.55 **PTEN AND E-CADHERIN EXPRESSION ARE ASSOCIATED IN CANINE MAMMARY TUMORS**

P. Asproni, L. Ressel, F. Millanta, I. Vannozzi and A. Poli

10.55 - 11.10 **EXPRESSION OF BCL-2, BCL-X_L, BAX AND APOPTOTIC INDEX IN CANINE MAMMARY TUMOURS: CORRELATION WITH CLINICOPATHOLOGICAL FACTORS**

F. Yildirim, K. Sonmez, H. Ozyogurtcu, G. Sennazli, A. Gurel, M.C. Gunduz and H. B. Sontas

11.10 - 11.25 **CORRELATION BETWEEN CYTOLOGY AND HISTOPATHOLOGY IN THE DIAGNOSIS OF SPLENIC NEOPLASMS IN DOGS**

A. Forlani, M. Caniatti, S. F. Santagostino, B. Vicini, C. Luraschi and P. Roccabianca

11.25 - 11.40 **E-CADHERIN DYSFUNCTION IN CANINE GASTRIC CANCER**

I. Amorim, J. Carvalho, A. Rema, M. Taulescu, A.L. Saraiva, A.M. Faustino, C.A. Reis, C. Oliveira and F. Gärtner

11.40 - 11.55 **CANINE PAPILLOMAVIRUS 1 (CPV1): A RETROSPECTIVE IMMUNOHISTOCHEMICAL AND REAL TIME PCR INVESTIGATION ON 88 ORAL LESIONS OF DOGS**

I. Porcellato, C. Brachelente, G. Guelfi, A. Reginato, M. Sforza and L. Mechelli

11.55 - 12.10 **IMMUNOHISTOCHEMICAL STUDY OF EXPRESSION OF CAVEOLIN-1(CAV-1) IN CANINE MALIGNANT MAMMARY TUMORS AS A GOOD MODEL IN HUMAN STUDIES**

Hannaneh Golshahi, Abbas Tavasoli, Annahita Rezaie and Mohammad Farhadi

Programme

Friday 6th September 2013

Location: Elvin Hall, Level 1

14.45 - 15.00 **Oral Presentations - Session H: Inflammatory, Skin & Wildlife Disease**

Chair: Enrico Bollo and Nicole Borel

INFECTIOUS CANINE HEPATITIS IN FREE-RANGING RED FOXES (*VULPES VULPES*)

A. W. Philbey and H. Thompson

15.00 - 15.15 **IDIOPATHIC SEVERE EOSINOPHILIC PNEUMONIA AND VASCULITIS IN 11 HORSES**

G.E. Magi, M.C. Ruscello, G. Rossi and G. Renzoni

15.15 - 15.30 **TRANSVERSE SECTIONING FOR EVALUATION OF SKIN BIOPSY SPECIMENS FROM ALOPECIC DOGS**

R. Bond, A. Hendricks, J. Patterson-Kane, K. Stevens and H. Brooks

15.30 - 15.45 **LESSER LOOSESTRIFE (*LYTHRUM HYSSOPIFOLIA*) POISONING IN SHEEP AND CATTLE**

A. W. Philbey and A.G. Morton

15.45 - 16.00 **HEALTH STATUS OF BROWN HARES (*LEPUS EUROPAEUS*) IN EASTERN AUSTRIA**

A. Posautz, A. Küber-Heiss, F. Knauer, ZS. Kelemen, F. Suchentrunk and C. Walzer

16.00 - 16.15 **DETECTION OF HEPATITIS E VIRUS (HEV) IN FREE RANGING WILD BOARS (*SUS SCROFA*) IN ITALY**

R. Verin, R. Nardini, M. Mazzei, P. Varuzza, A. De Martino and A. Poli

Programme

Saturday 7th September 2013

Location: Jeffery Hall, Level 1

08.30 - 09.30 **Keynote Lecture 5: Papillomaviruses in people and animals**
Chair: Norelene Harrington and Bartolomeo Biolatti

THE ROLE OF ANIMAL PAPILLOMAVIRUSES IN CANCERS

Lubna Nasir, University of Glasgow, Scotland

PAPILLOMAVIRUSES IN HUMANS

Simon Herrington, University of Dundee, UK

09.30 - 10.10 **British Society of Veterinary Pathology (BSVP) AGM**

10.10 - 10.40 **Refreshment Break and Final Poster Viewing**

10.40 - 11.40 **Prize Giving and Closing Ceremony**

Keynote Lectures: The role of the pathologist in biosecurity

Royal College of Pathologists Kettle Lecture

In 1936 Edgar Hartley Kettle died while in post as Professor of Pathology at the London Postgraduate Medical School. He was 54. A Yorkshireman born in Skipton he trained at St Mary's and took his first pathology position in 1907. In 1924 he moved as Professor to Cardiff and was there for three years before moving to St Bartholomew's Hospital in 1927. When the London Postgraduate Medical School was founded he was invited to be the first Director of the Institute of Pathology in 1934. Kettle's research interests shifted from cancer in his early years to silicosis and tuberculosis later on. He was elected to Fellowship of the Royal Society six months before he died, and 24 years before the establishment of the RCPPath. Since 1967 the lectures have been organised by this College.

BETWEEN THE DEVIL AND THE DEEP BLUE SEA: PREPARING FOR DISEASE EMERGENCE FROM WILDLIFE

Dr Karrie Rose, Australian Registry of Wildlife Health, Taronga Conservation Society, Australia

krose@zoo.nsw.gov.au

Australia has witnessed an unprecedented rate of disease emergence from wildlife reservoirs over the past two decades. High profile disease discoveries, such as Hendra virus, Australian bat lyssavirus, chytrid fungus, endogenous and exogenous Koala retroviruses, Tasmanian devil facial tumour diseases, and lesser known discoveries of cetacean morbillivirus, marine turtle systemic coccidiosis, leishmaniasis, tularaemia, babesiosis, and pathogenic orbiviruses have raised the level of investment and the quality of scientific investigation in wildlife health. These diseases have had clear repercussions across biodiversity conservation, human and domestic animal health.

Through these investigations we have been astonished by novel pathogens, entirely new mechanisms of disease, and new means of disease emergence and transmission. This situation has forced us to establish new methods of thinking, working and collaborating.

Australian veterinary pathologists have met the challenges faced through the study and management of emergent disease by assuming multiple and varied roles contributing to biosecurity protection. These roles include:

- disease detection,
- syndrome description,
- agent characterization,
- project management,
- risk assessment,
- surveillance,
- research,
- policy development,
- fund-raising,
- professional and community engagement and education,
- and developing eResearch platforms to foster effective online collaboration by uniting disparate colleagues and resources.

Australian veterinary pathologists have not only witnessed, but have helped to drive a paradigm shift regarding the role of wildlife health and disease in biosecurity. There is now a firm acceptance of the need to work ecologically and cooperatively to protect the collective health of humans, domestic animals, plants and the environment.



Keynote Lectures: The role of the pathologist in biosecurity

Royal College of Pathologists Cameron Lecture

Sir Roy Cameron was the College's founding President. An Australian by birth, he became an international expert of liver disease, and was the Professor of Pathology at University College Medical School in London for 27 years. He was knighted for his services to pathology as well as achieving fellowship of the Royal Society, the most prestigious scientific society in the UK. He helped the young College to its feet, but sadly died in office on October 1966. This lecture was founded in his memory.

THE PATH TO A HENDRA VIRUS VACCINE FOR HORSES “...CHANCE FAVOURS ONLY THE PREPARED MIND” *Pasteur 1854*

D. Middleton, CSIRO Australian Animal Health Laboratory, Geelong, Australia

deborah.middleton@csiro.au

Following its emergence in 1994 in association with an outbreak of fatal respiratory disease in racehorses and their trainer, Hendra virus (HeV) infection of horses has regularly recurred in Australia and with apparently increasing frequency. Initial research efforts identified the natural virus reservoir to be Australian flying foxes, but all human cases have been attributable to direct contact with the secretions of infected horses.

The closely related Nipah virus was discovered in Peninsular Malaysia in the late '90s associated with outbreaks of febrile encephalitis in humans and respiratory disease in pigs. Both viruses infect cells via fusion events mediated by their attachment (G) and fusion (F) glycoproteins and, as part of a wider research program into medical countermeasures, it was found that the G protein was strongly immunogenic in natural infection and antibody to the G protein was associated with virus clearance. This suggested a vaccine based on the G protein antigen was a feasible scientific goal.

Further human fatalities from HeV and the potential exposure of a child led to provision of funding support required for translation of proof-of-concept vaccine studies in laboratory animals to the target species, the horse; this required efficacy studies to be conducted at the highest level of bio-containment – Biosafety Level 4 (BSL4). The recent release of an equine vaccine to the Australian horse owning community represents the first commercially available product anywhere in the world that is focused on mitigating the impact of a BSL 4 pathogen. It is an outstanding example of the One Health approach to management of a major public health threat, whereby vaccination of horses will be used to prevent the transmission of virus from bats to humans, thereby protecting not only equine but also human health.



Keynote Lectures: Tendon pathology in human and animal athletes

TENDON PATHOLOGY IN HUMAN AND ANIMAL ATHLETES

Janet Patterson-Kane, University of Glasgow, Glasgow, Scotland

Janet.Patterson-Kane@glasgow.ac.uk

Tendon injury is a common occurrence for both human and equine athletes, particularly at elite levels of competition. In this session we will review the pathology of the superficial digital flexor tendon (SDFT). The SDFT is the most frequently injured tendon in horses and is the functional equivalent of the equally injury-prone human Achilles tendon (AT). Both tendons have a high re-injury rate, and many athletes are forced to retire as a result. Exercise-induced equine SDFT injury is one of the few naturally occurring domestic animal models of disease that has been widely accepted in the scientific literature.

Normal structure, function, and the histological and ultrastructural appearance of SDFT tissue will be reviewed, including the different cell types present and the effects of ageing. There will be a focus on how the veterinary pathologist should examine this tissue type, both grossly and microscopically. Current theories on the pathogenesis of exercise-induced tendon injury will be summarized, including the concepts of cumulative microdamage, dysrepair and degeneration, the central role of the tenocyte (tendon fibroblast), and the controversial role of inflammation. Lesions that are more (or less) thoroughly documented or understood in the SDFT versus the human AT will be highlighted. The phases of repair in tendon tissue following rupture will then be described, including their histological appearance. Differences between scar tissue formation and maturation in tendons and that in other tissues will be emphasized, and reasons why the repair quality is often not sufficient for continued athletic performance will be discussed.



33:

Keynote Lectures: Tendon pathology in human and animal athletes

TENDON PATHOLOGY IN (HUMAN) ATHLETES

Graham Riley, University of East Anglia, UK

Graham.Riley@uea.ac.uk



Keynote Lectures: Tuberculosis in people and animals

OF BADGERS AND MEN: VITAMIN D AND IMMUNITY TO MYCOBACTERIA

Adrian Martineau, Barts & The London School of Medicine, Queen Mary University of London, UK

a.martineau@qmul.ac.uk

Mycobacterial infections pose a major threat to human and animal health alike. The existing vaccine, BCG, offers limited protection at best. New strategies are therefore needed to control tuberculosis.

Vitamin D is best known for its classical role in promoting calcium absorption and bone mineralisation. A growing body of evidence suggests that it also plays a key role in modulating immune responses to infectious pathogens. Historically, vitamin D was used to treat human tuberculosis in the pre-antibiotic era, and vitamin D deficiency has long been recognised to associate with susceptibility both to active disease and to latent infection. Controversy remains, however, as to whether deficiency is the cause or the consequence of active disease. *In vitro*, 1,25-dihydroxyvitamin D - the steroid hormone and active metabolite of vitamin D - induces innate immune responses to mycobacteria in leucocytes of diverse species, raising the possibility that supplementation might have a role in prevention of mycobacterial disease.

In this talk, I will compare and contrast the effects of vitamin D metabolites on innate immune responses to mycobacterial infection in humans and other animals, and review the clinical literature investigating associations between vitamin D deficiency and susceptibility to tuberculosis in different species. I will present new data from an animal study exploring the relationship between vitamin D deficiency and susceptibility to TB in badgers, and a human study, which sheds light on the question of whether vitamin D deficiency arises as a cause or as a consequence of active tuberculosis. Finally I will discuss the challenges of conducting clinical trials to determine whether vitamin D supplementation might have a role in tuberculosis control.

Keynote Lectures: Tuberculosis in people and animals

THE TUBERCULOUS GRANULOMA: *INFERNO*, *PURGATORIO* OR *PARADISO*?

Dr J P Cassidy, Pathobiology Section, UCD Veterinary School, University College Dublin, Belfield, Dublin 4, Ireland

Joseph.Cassidy@ucd.ie

The tuberculous granuloma or 'tubercle' is a focal, self-organising granulomatous response against poorly degradable mycobacteria. Based on the morphological features of granulomas in cattle, humans and laboratory animal models this presentation will explore the mechanisms behind key pathological events occurring within these lesions. Although typically considered the host's method of confining mycobacteria within a hostile hypoxic environment through juxtaposing infected macrophages and T cells and by surrounding the infected lesion core with concentric layers of fibrous tissue (*inferno*), recent evidence suggests in some circumstances, granuloma formation may actually benefit the pathogen, providing sanctuary and facilitating their long-term survival (*paradiso*).

Necrosis, liquefaction, apoptosis, and cell migration/turnover are key processes within granulomas reflecting complex, dynamic interactions between mycobacteria, and host macrophages, multinucleate macrophage giant cells, dendritic cells, T lymphocytes, and cytokines. Recent studies with *M. tuberculosis* have identified mycobacterial virulence mechanisms such as trehalose dimycolate in the lipid-rich cell wall that promote tissue remodeling and granuloma development through stimulating host TNF- α and matrix metalloproteinase production. In 'stable' granulomas mycobacteria may enter a latent state of 'non-replicating persistence' with the potential to reactivate and escape at some later time-point, following host immune perturbation and loss of granuloma integrity. Further remarkable features of tuberculous granulomas are their functional heterogeneity and apparent autonomy so that in any given host, adjacent lesions may act as *inferno*, *purgatorio*, or *paradiso* for their resident mycobacteria.

Keynote Lectures: Diseases of rabbits and hares

LEPORID PATHOLOGY: RABBITS

Patricia Turner, University of Guelph, Canada

pvturner@uoguelph.ca

The rising popularity of domestic rabbits (*Oryctolagus cuniculus*) as house pets has resulted in increased numbers of biopsy and post mortem submissions received by diagnostic laboratories. While some conditions seen in pet rabbits correlate to conditions found in laboratory rabbits that are well described, many do not and it can be challenging for clinicians and pathologists to find information about tumours and other conditions specific to pet rabbits. In addition, pathologists should be aware of several new and emerging diseases that have been reported in pet and commercial meat rabbits. This session will provide a brief overview of common spontaneous lesions and diseases seen in domestic rabbits using a systems approach, and will emphasise clinical, macroscopic, and histopathologic features that may assist with diagnosis.

Keynote Lectures: Diseases of rabbits and hares

LEPORID PATHOLOGY IN HARES

Katherine E Whitwell, Equine Pathology Consultancy, Newmarket, UK

kew@moulton-newmarket.co.uk

In autumn 1990 following confirmation of Grass Sickness (equine dysautonomia) in two co-grazing mares staff reported having seen many sick hares (*Lepus europaeus*) locally. Examination of two hares from the property revealed that they also had lesions of dysautonomia. To put this 'new' disease into context, a hare mortality survey was conducted over many years.

Sourcing funding and the acquisition of dead hares required a broad publicity effort. Hares were obtained predominantly from East Anglia, within 25 miles of Newmarket. Postmortem examinations involved detailed dissection, histology of many tissues including CNS and autonomic ganglia, bacteriology and parasitology. A control population of 25 hares were examined (shot; road kills).

The main causes of death were analysed after the first 100 examinations. Many hares had more than one type of pathology. Intestinal coccidiosis was the commonest cause of death (28%), followed by leporine dysautonomia (24%), bacterial infections (18%), amyloidosis (10%), various internal pathologies (7%), European Brown Hare Syndrome (6%), starvation due to dental abnormality (2%), and internal neoplasia (2%). No cause was found in 3%. Nematode eggs of *Passaluris ambiguus* and adult tapeworms were identified: ticks, fleas and lice were commonly present. Arterial mineralisation was a frequent incidental finding.

Dysautonomia was an important cause of hare mortality in East Anglia. Coccidiosis and dysautonomia were commonest in October and November. Fatal amyloidosis was secondary to chronic non-fatal infections. Many conditions could be accurately diagnosed after gross necropsy.

Keynote Lectures: Papillomaviruses in people and animals

THE ROLE OF ANIMAL PAPILLOMAVIRUSES IN CANCERS

Lubna Nasir, University of Glasgow, Scotland

Lubna.Nasir@glasgow.ac.uk

PAPILLOMAVIRUSES IN HUMANS

Simon Herrington, University of Dundee, UK

s.herrington@dundee.ac.uk

The papillomaviruses are ubiquitous, predominantly epitheliotropic, viruses. Well over 100 different types are known to infect humans, affecting particularly the squamous epithelia of the anogenital region, the skin and the upper aerodigestive tract. The majority of infections remain subclinical and, in many cases, HPV infection results in benign lesions such as warts that regress with elimination of the infection. However, infection with some HPV types, particularly HPV 16 and 18, can also lead to malignant transformation through interference of viral proteins with cell cycle control mechanisms. The E6 and E7 proteins are particularly important in this process and de-regulation of their expression, with consequent abrogation of p53 and pRb function, in cycling cells is an important event in lesion progression. This association with malignant transformation has led to the development of vaccines against HPV and, in some countries, implementation of a vaccination programme.

Keynote Lecturers: Biographies

Dr Karrie Rose, Manager the Australian Registry of Wildlife Health, Taronga Conservation Society, Australia

Karrie enjoys a multi-faceted role in wildlife health research, education, and disease investigation as manager the Australian Registry of Wildlife Health, a program of Taronga Conservation Society Australia. Following in the auspicious footsteps of Registry Founder, Dr. Bill Hartley, Karrie provides diagnostic services, data and advice regarding wildlife health to a broad range of stakeholders including wildlife managers, zoo veterinarians, conservation programs, government and non-government agencies. Karrie's research focuses on the application of an ecological approach to identify and understand pathogens at the interface of animal, human and environmental health. Investigations into disease outbreaks and population declines in wildlife often transform into collaborative research projects leading to the characterisation of emerging pathogens. Karrie first became interested in working with wildlife while conducting field research and population studies with Ferruginous Hawks and Burrowing Owls during university summer breaks. Further employment within the wildlife rehabilitation and pathology programs of Calgary Zoo cemented her commitment to the study of wildlife health. Shortly after graduating with the faculty gold medal from the Western College of Veterinary Medicine, in Saskatoon, Karrie pursued a 3 year residency at the Metropolitan Toronto Zoo. This residency was completed in conjunction with a Doctor of Veterinary Science Degree in Zoo and Wild Animal Medicine and Pathology at the Ontario Veterinary College. Completion of this degree led to 16 months managing a charitable wildlife rehabilitation organisation contracted by the Maritime Safety Authority of New Zealand to provide preparedness and response for oiled wildlife. After a further twelve month period conducting wildlife health surveillance contracts in New Zealand, Karrie moved to Sydney in 1998 to undertake the position of veterinary pathologist for Taronga.

Dr Deborah Middleton, Leader, Pathogenesis Research, CSIRO Australian Animal Health Laboratory, Geelong VIC 3220, Australia

Deborah is a veterinary graduate of The University of Sydney, has a PhD in Veterinary Pathology and has over 30 years of experience in the diagnostic and experimental pathology of diseases of livestock, companion animals and wildlife. After commencing her career in teaching and research at The University of Sydney, she moved to Utrecht University followed by an eight-year stint at The Royal Veterinary College, University of London. Deborah then returned to Australia, where the water is warmer and all the beaches have sand, to take up an academic post in the veterinary pathology department of The University of Melbourne. Currently, she is the leader of pathogenesis research at the CSIRO Australian Animal Health Laboratory - a specialised Biosafety Level 3 and 4 containment facility - in Geelong, Victoria. Particular research interests of this group include emerging zoonotic diseases such as those caused by Highly Pathogenic Avian Influenza, Hendra and Nipah viruses, SARS, other bat-borne viruses and host-pathogen relationships where there is a high degree of co-evolution.



Keynote Lecturers: Biographies

Janet Patterson-Kane, Professor of Veterinary Pathology, Institute of Infection, Immunity and Inflammation, University of Glasgow, Scotland

Janet obtained her veterinary degree from Massey University in New Zealand, and worked in mixed and small animal practice in the UK for two and a half years. She returned to NZ to undertake a PhD on the effects of exercise on collagen in the digital tendons of racehorses, funded by a NZ Universities Scholarship and the NZ Equine Research Foundation. Janet then completed residency training in anatomic pathology at the University of Florida in the USA, followed by 18 months working as a diagnostic specialist at the Livestock Disease Diagnostic Center, University of Kentucky - the centre of the equine pathology universe. During that time she narrowly survived a gruelling examination, to become board-certified by the American College of Veterinary Pathologists. Janet then spent 7 years at the Royal Veterinary College, followed by 2 years back down under at the University of Queensland in Australia, before returning to colder climes to take up a Professorship at the University of Glasgow (in 2009). Over that time she has run a programme of equine tendon research, with a current focus on cellular pathology, and is currently based within an Institute to facilitate collaboration with medical colleagues. Janet is active as a diagnostic pathologist and has a general interest in equine pathology, particularly musculoskeletal conditions.

Graham Riley, Reader in Musculoskeletal Pathology at the University of East Anglia, UK

Graham is a biochemist with a research focus on the molecular pathology of tendon. A graduate of the University of Bristol, he has worked in a number of research areas in both academia and industry, including muscular dystrophy (Pasteur Institute, Paris), haemopoietic stem cells (Institute of Cancer Research, London) and parasitology (Wellcome Laboratories, Beckenham). He completed his PhD at the Rheumatology Research Unit in Cambridge, investigating the biochemical changes that underlie chronic tendon pathology in the rotator cuff tendons of the shoulder. In 1996 he was appointed Head of the Soft Tissue Research Group at the Rheumatology Research Unit, and formed his own research group to investigate the cell and molecular pathology of tendons, ligaments and fascia. He is an internationally recognised research leader in the field of tendon pathology, and has published a number of key papers. In particular, his work on the role and regulation of metalloproteinases in tendon matrix turnover has resulted in several well-cited publications, and his contribution to the field was recognised by the award of a Senior Research Fellowship from Arthritis Research UK. He is now Reader in Musculoskeletal Pathology at the University of East Anglia, having moved to Norwich in 2007.

Keynote Lecturers: Biographies

Adrian Martineau, Clinical Reader in Respiratory Infection & Immunity at Barts & The London Medical School, Queen Mary University of London, UK

His primary research interest is in the immunomodulatory actions of vitamin D in respiratory infection, and he leads a translational programme of work combining in vitro investigations with a series of multi-centre clinical trials. These investigate the potential utility of vitamin D supplementation as an adjunct in the treatment of tuberculosis, and in the prevention of acute respiratory infections and exacerbations of asthma and chronic obstructive pulmonary disease. Other interests include the role of neutrophils in the immune response to tuberculosis, and the effects of vitamin D supplementation in a range of non-communicable diseases: he is clinical Chief Investigator for the Vitamin D and Longevity (VIDAL) trial, a national study investigating effects of vitamin D supplementation on all-cause mortality in adults aged 65-84 years.

Joseph Cassidy, Veterinary Sciences Centre, School of Agriculture Food Science & Veterinary Medicine, University College Dublin, Ireland

Joseph qualified from UCD Veterinary School in Dublin in 1986. After four years in general practice joined Veterinary Sciences Division in Stormont, Belfast as a veterinary research officer. Completed PhD thesis at The Queen's University of Belfast on the Pathogenesis of Bovine Tuberculosis in 1998. Lecturer in Veterinary Pathology at UCD since 1999 and Member/Fellow of Royal College of Pathologists since 2002. Particular interest in the pathology of the respiratory tract. Research interests include laboratory animal models of tuberculosis and their role in vaccine assessment, as well as murine models of Bordetella pertussis infection, asthma and ascariasis. Scientific editor of 'The Veterinary Journal' since 2007.

Keynote Lecturers: Biographies

Patricia Turner, Professor in the Department of Pathobiology & Program Leader of Laboratory Animal Science at the University of Guelph, Canada

Pat manages the university laboratory animal diagnostic pathology core and provides consultative laboratory animal pathology services (diagnostic, phenotyping, modeling, and toxicology). Her research interests include impact of environment on affective behavior and disease susceptibility in laboratory animals, and infectious diseases of laboratory animals. She completed a BSc in Biochemistry (McMaster University) and an MSc in Pharmacology (Dalhousie University), prior to a Doctor of Veterinary Medicine at the Ontario Veterinary College. After two years of mixed practice, Pat returned to the University of Guelph to complete a Doctorate in Veterinary Sciences in Comparative Pathology with a thesis project in toxicologic pathology. Following post-doctoral work at McGill University, she was employed as Director of Animal Care Services and Asst Professor of Pathology at Queen's University. She later worked for Warner-Lambert and Pfizer as a toxicology team representative in preclinical safety testing. Pat teaches comparative medicine and pathology, toxicology, and toxicologic pathology at the University of Guelph, and is a Diplomate of both the American College of Laboratory Animal Medicine and the American Board of Toxicology.

Katherine E Whitwell BVSc, Dipl ECVP, FRCVS, Equine Pathology Consultancy, Newmarket, Suffolk, UK

Katherine graduated from Liverpool in 1965 and spent 3 formative years as clinician in mixed/agricultural practices (Gloucester, Herefordshire, Montgomery and Alnwick). She took a career change to focus on pathology, joining the Animal Health Trust's (AHT) Equine Research Station, Newmarket in December 1968 as assistant pathologist, working with Dr Hugh Platt. She stayed in full time employment with the AHT for 24 years, latterly as senior pathologist and Section head of Pathology. The work embraced equine diagnostic pathology, research (including original work on EHV1 infection), and educational activities. Since 1993 Katherine has been self employed, running the Equine Pathology Consultancy, and is consultant to both Newmarket diagnostic labs. In 1993 she became RCVS Specialist in Veterinary Pathology (equine), gained a Fellowship in March 1994 and became a Diplomate of the ECVP in 1998. Pathology interests have focussed on abortion, the placenta, foal losses, neurological diseases, sudden unexplained deaths, insurance claims, cases with forensic/legal/welfare implications, and cytology. An interest in skeletal problems lead to collaborative palaeopathology studies at Cambridge University. Frustration with lack of progress into equine grass sickness and curiosity about environmental issues lead to studies of comparative dysautonomias particularly in leporids, and thereby to an interest in the full spectrum of pathology in wild hares in particular.

Keynote Lecturers: Biographies

Lubna Nasir, Professor in Comparative Oncology, Centre for Virus Research, Institute of Infection, Immunity and Inflammation, University of Glasgow, Scotland

Lubna obtained her PhD in 1993 and subsequently held a post doctoral position at the University of Glasgow working on the role of Papillomaviruses in Equine Sarcoids. She was then appointed as lecturer in 2001 where she continued to pursue her research interest in animal papillomaviruses, subsequently gaining senior lecturer position in 2005. In 2010 Lubna Nasir was promoted to a personal chair. Throughout her career, Lubna has been engaged in research primarily on the role of papillomaviruses in disease pathogenesis in horses and is an internationally recognised research leader in this field. Her current research focus combines the disciplines of comparative biology, virology, molecular and cell biology to study virus host interactions and disease transmission of Bovine Papillomaviruses in a non-natural equine host.

Simon Herrington, University of Dundee, Ninewells Hospital & Medical School, Dundee, UK

Graduated in biochemistry from the University of Cambridge in 1982 and medicine from the University of London in 1985. He trained in Internal Medicine and then became a CRC clinical research fellow in the Nuffield Department of Pathology, University of Oxford, receiving his DPhil in 1991. He was then appointed clinical lecturer in pathology in Oxford where he completed his training in clinical cellular pathology. He was appointed clinical senior lecturer and consultant in pathology at the University of Liverpool in 1995 and was promoted to a personal chair in 1999. In 2003, he was appointed to the chair of Pathology at the University of St Andrews, moving to the Chair of Cancer Pathology at the University of Dundee in 2010. He has held an honorary consultant contract with NHS Tayside, specialising in gynaecological pathology, since 2003. He is General Secretary of the Pathological Society of Great Britain and Ireland and President of the International Society of Gynecological Pathologists. His main research focus is the pathogenesis of anogenital epithelial neoplasia and how improved understanding of the mechanisms involved can be used to improve disease diagnosis.

Oral Presentations

Session A: Degenerative & Infectious Disease

THE PATHOLOGY ASSOCIATED WITH IDIOPATHIC ARTERIAL ANEURYSM/RUPTURE IN HOLSTEIN/FRIESIAN CATTLE

M. Wessels*, T.Crawshaw[‡], F.Howie[†], A.Patterson[•] and N. Peperkamp[■]

AHVLA Preston*/Starcross[‡], SAC Edinburgh[†], AFBI Stormont[•], UK and GD-Deventer[■], Holland

mark.wessels@ahvla.gsi.gov.uk

Introduction: Arterial aneurysm is an important cause of human morbidity and mortality in the developed world. It is also recognised in a wide range of domestic species associated with genetic and environmental aetiologies. Reports in cattle are rare but a case study in North America suggests an increasing incidence. The pathology of arterial aneurysm/rupture in European Holstein/Friesian cattle is described.

Materials and Methods: 75 cases involving adult Holstein/Friesian cattle were identified on scanning surveillance through necropsy. In 24 (♀ = 23, ♂ = 1) the aneurysm/rupture was dissected. Additional arteries from these cases were harvested using a standard protocol. Histological examination of affected and non-affected arteries was undertaken using haematoxylin/eosin, elastic van Gieson, Alcian blue and periodic acid Schiff. Liver copper analysis was performed.

Results: Fusiform/saccular aneurysms were found in cranial mesenteric or coeliac arteries (n=17) and the abdominal aorta (n=2). Key histological features included medial degeneration and disorganisation, intimal hyperplasia and vasa vasorum perivascular infiltrate. Spontaneous transmural rupture was seen in the uterine artery (n=5) and thoracic aorta (n=1). No animals were copper deficient.

Conclusions: Histological changes are suggestive of a primary degenerative vasculopathy leading to aneurysm formation and/or rupture and are similar to those in North American cows suggesting a similar pathogenesis and aetiology. They are also similar to vascular changes in humans where connective tissue disorders are implicated.

Oral Presentations

Session A: Degenerative & Infectious Disease

A MULTIPLE APPROACH TO INVESTIGATE THE AETIOPATHOGENESIS OF LIPOMATOUS MUSCULAR DYSTROPHY IN PIEDMONTESE CATTLE

E. Biasibetti, S. Peletto*, P. Acutis*, C. Boin*, F. Schiavini**, A. Bagnato** and M.T. Capucchio

*Dept. Veterinary Sciences, University of Torino; *Istituto Zooprofilattico Sperimentale del Piemonte, Liguria e Valle d'Aosta, Torino and **Dept. Health, Animal Science and Food Safety, University of Milano, Italy*

elena.biasibetti@unito.it

Introduction: The diagnosis of neuromuscular diseases is based on different diagnostic techniques: clinical evaluation, muscle biopsy and, in some instances, molecular genetic investigations. Lipomatous muscular dystrophy (LMD) of Piedmontese cattle represents a degenerative myopathy whose aetiology is probably multifactorial, involving genetic, vascular and nutritional factors. This study reports a multiple approach to investigate the aetiopathogenesis of this disease.

Materials and Methods: From 2009 to May 2013, muscle samples from 156 affected individuals were collected and submitted to macroscopical, histological and enzymatic investigations. Sampling for genetic screening is ongoing matching cases to randomly selected controls from same herds according to a casecontrol design.

Results: Gross pathology revealed a different grade of adipose tissue infiltration across individuals. Histological investigations showed variations in fibre size, fibre necrosis, mononuclear cells infiltrations, increase of connective tissue and especially, replacement by fat.

Conclusion: Several findings observed lead to the classification of this disease as a muscular dystrophy. To investigate the existence of a genetic basis of LMD a genome wide association study based on DNA pooling and SNP markers (Illumina BovineHD BeadChip) is ongoing. This approach will allow the identification of genetic markers useful for selective breeding in Piedmontese cattle.

Oral Presentations

Session A: Degenerative & Infectious Disease

A NOVEL, IDIOPATHIC, SUPERFICIAL NEOCORTICAL DEGENERATION AND ATROPHY IN YOUNG ADULT DOGS

S. D. Cahalan, R. Cappello, A. de Lahunta, B. A. Summers

scahalan@rvc.ac.uk

Introduction: This communication describes a diffuse, chronic, superficial neocortical degeneration and atrophy of unknown etiology detected at post mortem examination in 5 dogs 1 to 2 years of age.

Materials and Methods: Presenting neurological signs included ataxia, blindness, mentation changes and postural deficits occurring from 4 weeks to 1 year prior to presentation. Magnetic resonance imaging of the brain of 2 dogs demonstrated severe bilateral cerebrocortical atrophy.

Results: Grossly, multifocal bilaterally symmetrical extensive areas of neocortical brownish discoloration associated with atrophy and sulcal widening were recorded in the dorsal and lateral cerebral hemispheres in 3 dogs. Microscopically, in all dogs there was subacute to chronic superficial neocortical erosion and atrophy affecting all cerebral lobes, ranging from loss of the molecular layer to less frequent mild to marked cavitations of variable length and depth. Mild to moderately increased numbers of small blood vessels, proliferating fibrocytes, lymphocytes, plasma cells and debris-laden macrophages were present in the leptomeninges and subarachnoid space of all dogs. Secondary corticospinal tract degeneration was uniformly present.

Discussion: The distribution pattern of gross and histological cerebral lesions suggests that this is a novel degenerative canine cerebral disease. A congenital vascular anomaly or subarachnoid toxins are considered as possible etiologies.

Key words; Brain, canines, cortical atrophy, dog, neocortex, degeneration.

Oral Presentations

Session A: Degenerative & Infectious Disease

DE NOVO HLA-DR EXPRESSION IN CANINE RENAL TUBULAR EPITHELIUM: A POSSIBLE EVENT IN EPITHELIAL-MESENCHYMAL-TRANSITION

SL Benali^{*}, GE Lees[‡], MB Nabity[‡], F Bonsembiante^{*}, L Aresu^{*}

^{*} Department Comparative Biomedicine and Food Science, University of Padova, Legnaro (PD) – Italy

[‡] Department of Small Animal Clinical Sciences, College of Veterinary Medicine and Biomedical Sciences, Texas A&M University, College Station, TX -USA

[‡] Department of Veterinary Pathobiology, College of Veterinary Medicine and Biomedical Sciences, Texas A&M University, College Station, TX-USA

Silvia.benali@alice.it

Introduction: Tubular epithelial cells (TECs) are known to undergo epithelial-mesenchymal-transition (EMT) contributing to the progression of Tubulointerstitial Fibrosis (TIF). In human glomerulonephritis, TECs have shown the capacity to act as non-professional antigen presenting cells (APC). The aim of this study was to assess altered TECs expression of β -Catenin, HLA-DR, and vimentin in renal biopsies from dogs with chronic tubulointerstitial damage.

Materials and Methods: Morphological diagnosis, inflammation grade, TIF, HLA-DR, β -Catenin expression and clinical variables were compared in dogs with renal injuries. β -Catenin was used as marker for EMT.

Results: Fibrosis, HLA-DR expression, SCr, and UPC were increased and β -Catenin expression was decreased in dogs with primary glomerular diseases compared with dogs with acute tubular necrosis. HLA-DR expression by TECs was positively correlated with fibrosis, inflammation, UPC, and SCr. β -Catenin expression was negatively correlated with fibrosis and inflammation as well as HLA-DR expression.

Conclusions: Progression of renal diseases correlates closely with tubulointerstitial damage. The *de novo* HLA-DR expression by TECs may indicate APC capabilities of TECs, providing new insights into the progression of TIF and EMT.

Oral Presentations

Session A: Degenerative & Infectious Disease

GENERATION AND CHARACTERIZATION OF A PORCINE MODEL OF DUCHENNE MUSCULAR DYSTROPHY

A. Blutke^{*}, N. Klymiuk[†], A. Graf[#], S. Krause[□], K. Burkhardt[†], A. Wuensch[†], S. Krebs[#], B. Kessler[†], V. Zakhartchenko[†], M. Kurome[†], E. Kemter[†], H. Nagashima[‡], B. Schoser[□], N. Herbach^{*}, H. Blum[#], R. Wanke^{*}, C. Thirion[□], H. Lochmüller[£], M. C. Walter[□], E. Wolf^{†, #}

^{}Institute of Veterinary Pathology, Center for Clinical Veterinary Medicine; [†]Chair for Molecular Animal Breeding and Biotechnology; [#]Laboratory for Functional Genome Analysis (LAFUGA), Gene Center; [□]Friedrich-Baur-Institute, Department of Neurology; ^{*, †, #, □}LMU Munich, Germany; [‡]Laboratory of Developmental Engineering, Meiji University, Kawasaki, Japan; [£]Institute of Genetic Medicine, Newcastle University, Newcastle upon Tyne, UK*

blutke@patho.vetmed.uni-muenchen.de

Introduction: To establish a large animal model of Duchenne muscular dystrophy (DMD), male pigs with a deletion of exon 52 of the dystrophin (DMD)-gene were generated by gene targeting and nuclear transfer.

Materials and Methods: DMD deficient pigs and age-matched wild-type pigs (2 days to 3 months of age) were investigated by clinical and pathological examination and gene expression analyses.

Results: DMD deficient pigs exhibited progressive dystrophic changes of skeletal muscles, impaired mobility, muscle weakness, and a reduced life span of ~3 months. The transcriptome changes in skeletal muscles of 3-month-old DMD pigs were in good accordance with human DMD gene expression profiles, whereas the transcriptome profile of 2-day-old DMD pigs showed similarities with exercise induced muscle injury.

Conclusion: Our data provide new insights into congenital changes associated with dystrophin deficiency and secondary complications arising during postnatal development, reflecting the hierarchy of physiological derangements in the dystrophin-deficient muscle.

Oral Presentations

Session A: Degenerative & Infectious Disease

CRYPTOSPORIDIAL INFECTIONS IN CAPTIVE TORTOISES

B. Richter^{*}, M. Brinkmeier^{*}, M. Globokar Vrhovec[†], N. Nedorost^{*}, N. Pantchev[†]

^{*} Institute of Pathology and Forensic Veterinary Medicine, University of Veterinary Medicine, Vienna, Austria
and [†] Idexx Vet Med Labor, Ludwigsburg, Germany

barbara.richter@vetmeduni.ac.at

Introduction: Cryptosporidiosis is a well-known disease in snakes and lizards but little information has been published on this parasitosis in tortoise species. Seemingly, there are two different cryptosporidia in these reptiles. The intestinal species *Cryptosporidium ducismarci* has been associated with clinical disease and pathological lesions, but only few data exist on the presumably gastric *Cryptosporidium* "tortoise genotype".

Materials and Methods: Paraffin-embedded gastrointestinal tissue samples from 100 captive tortoises, which had been submitted for routine pathological examination, were included in this retrospective study. Histological slides were used for standard histopathological examination and for chromogenic in-situ hybridization (ISH) specific for the genus *Cryptosporidium*. Cryptosporidial species identification was done by sequence analysis of the small-subunit ribosomal RNA-gene in positive samples.

Results: With ISH cryptosporidia were detected lining the gastric and/or small intestinal mucosa in nine animals from five different tortoise species. None of these animals had been diagnosed as being infected during routine pathological examination. Histological examination did not reveal any consistent tissue changes in the affected animals. Sequencing results indicated the presence of three different cryptosporidia in the examined tortoises.

Conclusions: Specific gastric and intestinal cryptosporidia are quite common in captive tortoise species. Although no evident histological changes could be associated with cryptosporidial infections the results suggest a possible association with non-specific digestive symptoms.

Oral Presentations

Session A: Degenerative & Infectious Disease

CANINE DISTEMPER VIRUS INFECTION LEADS TO REDUCED ANTIGEN PRESENTING FUNCTION OF MONOCYTE-DERIVED DENDRITIC CELLS

A. Beineke^{*}, V. Qeska^{*}, Y. Barthel^{*}, M. Iseringhausen^{*}, C. Urhausen[†], V.M. Stein[‡], A. Tipold[‡], W. Baumgärtner^{*}

¹Department of Pathology, [†]Unit for Reproductive Medicine, Small Animal Clinic, and [‡]Department of Small Animal Medicine and Surgery, University of Veterinary Medicine Hannover, Germany

andreas.beineke@tiho-hannover.de

Introduction: Canine distemper virus (CDV) causes immunosuppression and increased susceptibility of affected dogs to opportunistic infections. Similar to human measles virus, CDV is supposed to inhibit terminal differentiation of dendritic cells (DCs), responsible for disturbed repopulation of lymphoid tissues and diminished antigen presenting function in dogs.

Materials and Methods: Canine DCs were generated from peripheral blood monocytes *in vitro* and infected with CDV. Virus infection was confirmed and quantified by transmission electron microscopy, CDV-specific immunofluorescence and virus titration. Phenotypical changes of cultured cells were determined by flow cytometry. In addition, apoptotic changes and cellular damage were quantified by TUNEL and lactate dehydrogenase assay.

Results: Results demonstrated a significant time dependent increase of the infectivity rate of DCs. As observed by flow cytometry, CDV-infection of canine DCs led to a down-regulation of co-stimulatory molecules CD80 and CD86 as well as of MHC II, indicative of disturbed antigen presenting properties. As a potential mechanism to evade host immune responses, infected DCs showed no evidence of apoptosis or cell lysis.

Conclusion: These data suggest that CDV-infection of DCs plays a role in the pathogenesis of long lasting immune alterations and virus persistence in canine distemper.

Oral Presentations

Session B: Infectious Disease

EQUINE INFECTIOUS DISEASE VIRUS INDUCED PULMONARY INTERSTITIAL DAMAGE. WHAT ABOUT AEROSOL TRANSMISSION?

P. Bolfa*, J. L. Cadore†, J. F. Mornex‡, C. Catoi*, A. Gal*, M. Taulescu* and C. Leroux‡

**Pathology Department, University of Agricultural Sciences and Veterinary Medicine, Cluj-Napoca, Romania and †Internal Medicine Department, VetAgro Sup, Marcy-l'Etoile, France and ‡UMR754 INRA University Lyon 1, Retrovirus and Comparative Pathology, France*

pompei.bolfa@usamvcluj.ro

Introduction: Equine infectious anemia (EIA) is considered a blood-borne disease primarily transmitted iatrogenically or by haematophagous insects and the virus is infecting cells of the monocyte/macrophage lineage. Alternate routes of transmission have not been explored although there is evidence that EIA was spread via aerosolized particles during the 2006 EIA virus (EIAV) outbreak in Ireland.

Materials and Methods: H&E lung sections from 77 EIAV seropositive Romanian horses were scored based on: lymphocyte infiltration, (peri) bronchiolar inflammation, thickness of the alveolar septa. Immunostaining for the p26 EIAV capsid protein expression and smooth muscle actin were performed.

Results: 52% of the EIAV-positive horses displayed a mild inflammation around the bronchi, 22% - moderate inflammation with inflammatory cells inside the wall and epithelial bronchiolar hyperplasia and 6.5% - moderate to severe inflammation, with destruction of the bronchiolar epithelium and accumulation of smooth muscle cells within the pulmonary parenchyma. Interestingly, EIAV p26 was expressed in the cytoplasm of cells compatible by morphology and localization with alveolar and bronchiolar epithelial cells.

Conclusions: The lesions we observed were compatible with interstitial diffuse pneumonia observed during other lentiviral infections. The presence of EIAV capsid in lung epithelial cells suggests that EIAV might be responsible for the bronchointerstitial damage observed.

Oral Presentations

Session B: Infectious Disease

THE NOVEL HUMAN CORONAVIRUS-EMC CAUSES DISEASE IN MACAQUES BUT NOT IN FERRETS

J.M.A. van den Brand, L. Wiersma, S.L. Smits, L. Provacia, V.S. Raj, A.D.M.E. Osterhaus, T. Kuiken and B.L. Haagmans

Viroscience Lab, Erasmus MC, Rotterdam, the Netherlands

j.vandenbrand@erasmusmc.nl

Introduction: In 2012 a novel human coronavirus (HCoV-EMC) was discovered in human patients causing lower respiratory tract infection. The clinical course of the disease was similar to that seen in severe acute respiratory syndrome (SARS). However, the virulence and pathogenesis of the virus is not known yet and no animal models for human disease have been established.

Materials and Methods: Cynomolgus macaques and ferrets were inoculated with HCoV-EMC, on 1 or 4 days after inoculation the animals were euthanized and pathological, immunohistochemical, in situ hybridization, virological and serological analyses were performed on the samples of those animals. To determine the presence of the receptor for the HCoV-EMC, dipeptidyl peptidase 4 (DDP4) in different cell types of the respiratory tissue, we used immunohistochemical analysis.

Results: HCoV-EMC caused mild respiratory disease in macaques, with non-ciliated bronchiolar epithelial cells as important target cells. Ferrets were not productively infected.

Conclusions: Our results confirm HCoV-EMC as the cause of respiratory disease in a non-human primate model. This suggests that the cynomolgus macaque is a suitable experimental animal species to model this disease in humans.

Oral Presentations

Session B: Infectious Disease

ACTIVATION OF THE EXTRINSIC PATHWAY OF APOPTOSIS DURING PRRS

I.M. Rodríguez-Gómez*, I. Barranco*, S.P. Amarilla*, J. Gómez-Laguna[†], O. García-Nicolás[‡], G. Ramis[‡], F.J. Pallarés[‡] and L. Carrasco*

*Córdoba University, Córdoba, Spain, [†]CICAP, Pozoblanco, Spain, [‡]Murcia University, Murcia, Spain

v22rogoi@uco.es

Introduction: Porcine Reproductive and Respiratory Syndrome Virus (PRRSV) is able to evade the host immune response. One of the strategies followed by PRRSV could be the induction of apoptosis. In this study we assess the expression of cleaved caspase (CCasp) 8, 9 and 3, TUNEL and PRRSV in tonsil and mediastinal lymph node of infected piglets.

Materials and Methods: Twenty-eight SPF piglets were distributed in groups of four, inoculated with PRRSV field isolate 2982 and killed sequentially at different time points. Control animals were mock-inoculated and killed at the end of the study. Samples of tonsil and mediastinal lymph node were collected at necropsy and fixed to perform immunohistochemical studies.

Results: An enhanced expression of CCasp8 was observed earlier in tonsils than in mediastinal lymph nodes. CCasp3 was increased at the end of the experiment. No statistically significant changes were found for CCasp9 and TUNEL. Lymphocytes and macrophages were mainly stained by CCasp8, CCasp9, and CCasp3. PRRSV expression showed two peaks, at 3 and 14 days post-inoculation, in tonsil while only one peak at the beginning of the experiment in mediastinal lymph node.

Conclusion: The activation of the extrinsic apoptotic pathway by strain 2982 highlights that the apoptosis of crucial effector cells, such as lymphocytes or macrophages, might be an strategy to elude host immune response by PRRSV.

Oral Presentations

Session B: Infectious Disease

LESIONS IN PERIPHERAL ORGANS OF RUMINANTS INFECTED WITH SCHMALLENBERG VIRUS

F. Seehusen*, V. Herder*, M. Weigand*, K. Hahn*, A. Habierski*, I. Gerhauser*, P. Wohlsein*, M. Peters±, M. Varela+, M. Palmarini+ and W. Baumgärtner*

**Department of Pathology, University of Veterinary Medicine, Hannover, Germany, ± Staatliches Veterinäruntersuchungsamt, Arnsberg, Germany and +MRC-University of Glasgow Centre for Virus Research, Glasgow, United Kingdom*

frauke.seehusen@tiho-hannover.de

Introduction: Schmallenberg virus (SBV), an orthobunyavirus of the family *Bunyaviridae*, causes epidemic abortions and births of malformed or stillborn animals in ruminants. Main pathomorphological findings consisted of skeletal malformations and abnormalities of the central nervous system (CNS), including hydrocephalus, cerebellar hypoplasia, and micromyelia.

Materials and Methods: To further elucidate the changes in peripheral organs of SBV-infected animals, paraffin-embedded material of ruminants originating from Northern Germany was investigated by using HE staining, SBV immunohistochemistry and in situ hybridization. 30 calves, 13 lambs, and one goat kid as well as age-matched controls were included in this study.

Results: Preliminary results comprised a moderate to severe muscular hypoplasia with fatty replacement, mild to moderate hepatocellular degeneration with interstitial fibrosis and biliary hyperplasia and mild lymphoid depletion of thymus and spleen in some SBV-infected animals. Single SBV antigen-positive cells were detected in one adrenal gland. However this needs to be substantiated by further investigations. The majority of the animals showed no SBV-positive cells in the peripheral organs.

Conclusions: Predominantly muscular and hepatic changes were found in SBV-infected and aborted ruminants, which were presumably caused by CNS lesions or represent residual lesions of systemic spread, respectively.

Oral Presentations

Session C: Infectious Disease

MICROSCOPIC BRAIN LESIONS IN DOGS WITH VISCERAL LEISHMANIASIS

G.D. Melo*, F.G. Grano*, J.E.S. Silva*, J.M. Silva*, A. Schweigert*, A.T. Ramos[†], I.M. Langohr[‡], G.F. Machado*

*São Paulo State University (UNESP), College of Veterinary Medicine, Laboratory of Applied Pathology, Araçatuba-SP, Brazil

[†]Federal University of Santa Catarina, School of Veterinary Medicine, Curitiba-SC, Brazil

[‡]Michigan State University, College of Veterinary Medicine, Department of Pathobiology and Diagnostic Investigation, East Lansing-MI, United States of America

di.melo@uol.com.br

Introduction: Visceral leishmaniasis (VL) is caused by the zoonotic protozoan *Leishmania chagasi* (= *L. infantum*). In dogs, there is frequent association of chronic VL with neurological lesions, but descriptions of specific brain alterations are lacking. Therefore, we aimed to characterize the histopathological changes in the brain of dogs naturally infected by *L. chagasi*.

Materials and Methods: Brain fragments from 40 infected dogs including the telencephalon, diencephalon and metencephalon were paraffin-embedded, sectioned and stained with hematoxylin-eosin. The slides were then submitted to light microscopic examination.

Results: The most common lesions were mild-to-marked meningitis (77.5%), choroiditis (74.2%), subventricular gliosis (72.5%) and lymphohistioplasmacytic perivascular cuffs (55.0%). Glial nodules (30.0%) and satellitosis/neuronophagia (32.5%) were also detected. Additionally, there was vascular congestion (52.5%) and microhemorrhages (40.0%).

Conclusion: The frequent occurrence of microscopic alterations in the brain of infected dogs supports previous evidence that the nervous system is affected during VL. The observation of lesions mostly at the meningeal and ventricular surfaces suggest a response to peripheral infection, possibly after interaction of glial cells with leishmanial components or inflammatory cells and mediators in blood and cerebrospinal fluid, respectively.

Oral Presentations

Session C: Infectious Disease

CUTANEOUS *MYCOBACTERIUM AVIUM* COMPLEX INFECTION IN CATS ORIGINATING FROM THE ISLAND OF HVAR CROATIA

A. Beck*, S. Špičić**, I. Račić**, I.C. Šoštarić – Zuckermann*, A. Gudan Kurilj*, Ž. Grabarević*, Ž. Cvetnić** and R. Beck**

*Department of Veterinary Pathology, Veterinary Faculty, University of Zagreb, Croatia.

**Croatian Veterinary Institute, Department for Bacteriology and Parasitology, Zagreb, Croatia

abeck@vef.hr

Introduction: Cutaneous granulomas of cats are rarely caused by saprophytic mycobacteria from *Mycobacterium avium complex* (MAC) which are cultivable. MAC skin infection has non-specific cutaneous nodular presentation and three histomorphologic forms: granulomatous, pyogranulomatous and spindle cell. We represent four cases of MAC induced skin granulomas in cats originating from seaport of island Hvar.

Materials and Methods: In three cases submitted as skin neoplasia in cats we diagnosed granulomatous inflammation and presumed feline lepromatous leprosy based on granuloma architecture. In fourth case feline leprosy was suspected based on impression smear finding of negatively stained intracellular bacilli taken from ulcerated nodule. Mycobacterial culture was performed from granuloma tissue of two cats. DNA was extracted from formalin fixed paraffin embedded tissue and from fresh tissue. Partial fragment of 16S rRNA was amplified and subsequently sequenced and compared with sequences in GenBank. Routine histology and Ziehl-Neelsen staining were performed in fourth case.

Results: Mycobacteria were not detected by culture after 12 weeks of cultivation. In first three cases granuloma architecture was rich in foamy macrophages and multinuclear giant cells harboring high amount of slender acid-fast bacilli. Organisms were numerous within spindle cells in fourth case of typical MAC spindle cell proliferation. All sequences were identical. They revealed 100% identity with sequences of MAC members.

Conclusions: Mycobacteria growth characteristics on synthetic media, as well as histological pattern of skin granulomas are not sufficient to distinguish different bacterial species, indicating the importance of molecular typing.

Oral Presentations

Session C: Infectious Disease

EVIDENCE FOR THE ROLE OF A SHREW SPECIES AS RESERVOIR HOST OF BORNA DISEASE VIRUS IN EASTERN GERMANY

H. Weissenböck*, R. Dürrwald[†], J. Kolodziejek[‡], N. Nowotny[‡]

*Institute of Pathology and [‡]Institute of Virology, Vetmeduni Vienna, Austria, [†]IDT Biologika GmbH, Dessau-Roßlau

Herbert.weissenboeck@vetmeduni.ac.at

Introduction: Borna disease (BD) is a sporadic viral neurological disease of several mammalian species, predominantly equines. Recently, Swiss researchers identified the bicoloured white-toothed shrew (*Crocidura leucodon*) as potential vector species. The aim of this study was to evaluate whether Borna disease virus (BDV)-infected shrews are present in a different endemic region for BD, Eastern Germany, as well.

Materials and Methods: During five consecutive years (2005-2010) 106 shrews of four different species (among them 55 *C. leucodon*) were collected in several Eastern German federal states. After necropsy, samples were processed for histology, BDV-immunohistochemistry (IHC) and RT-PCR.

Results: In twelve (21.8%) *C. leucodon* shrews BDV genomic RNA was detected by RT-PCR. In the absence of histological lesions IHC showed strong expression of BDV proteins in many neural and extraneural tissues, suggesting a persistent infection. In other shrew species BDV was not detected. The same BDV strain was identified in these shrews which differed from the BDV strain from the Swiss shrews.

Conclusions: These observations show that territorially bound distinct BDV strains cause persistent, obviously subclinical infections in *C. leucodon* shrews. The widespread organ tropism suggests shedding of the virus by different routes and confirms the potential role of *C. leucodon* as reservoir host and source of transmission to susceptible mammal species.

Oral Presentations

Session C: Infectious Disease

MICROARRAY ANALYSIS OF CANINE DISTEMPER VIRUS-INDUCED DEMYELINATING LEUKOENCEPHALITIS

R. Ulrich^{*}, C. Puff^{*}, K. Wewetzer[†], A. Kakuhi[‡], U. Deschl[‡] and W. Baumgärtner^{*}

^{*}Department of Pathology, University of Veterinary Medicine Hannover, Germany and [†]Department of Functional and Applied Anatomy, Center of Anatomy, Hannover Medical School, Germany and [‡]Department of Non-Clinical Drug Safety, Boehringer Ingelheim Pharma, Biberach (Riß), Germany

reiner.ulrich@tiho-hannover.de

Introduction: Distemper is a systemic viral infection of dogs causing pneumonia, gastroenteritis, lymphopenia and encephalomyelitis. Canine distemper virus (CDV)-induced demyelinating leukoencephalitis (CDV-DL) in dogs is a translational animal model for multiple sclerosis. The aim of this study was to perform an assumption-free microarray analysis of transcriptional changes in CDV-DL.

Materials and Methods: RNA was isolated from the cerebellum of 3-6 dogs per subgroup of CDV-DL and 12 normal control dogs and hybridized to canine genome 2.0 arrays (Affymetrix). Data were normalized employing GC-RMA and differential expression was identified employing LIMMA ($q \leq 0.05$) and a fold change filter (≤ -2 or ≥ 2).

Results: Microarray analysis revealed 442 differentially expressed genes. The dominating change was a constant up-regulation of genes related to response to other organism and wounding, and the humoral and cell-mediated immune response. Multiple myelin genes displayed a down-regulation at the onset of demyelination followed by a rebound in later stages. Notably these later stages exhibited a unique up-regulation of $\gamma\delta$ -T-lymphocyte- and immunoglobulin-marker genes.

Conclusions: The transcriptional changes suggest a biphasic mode of demyelination in CDV-DL with an initial oligodendropathy followed by a second wave of intrathecally-produced immunoglobulin-mediated autoimmunity.

Oral Presentations

Session C: Infectious Disease

EDEMA DISEASE: APOPTOTIC PANCREATOPATHY?

J. F. Edwards*, T. Conner†

Department of Veterinary Pathobiology, College of Veterinary Medicine and Biomedical Sciences, Texas A&M University College Station TX, USA

†Food Safety Inspection Service, United States Department of Agriculture, USA

jedwards@cvm.tamu.edu

Introduction: Edema disease is a common, postweaning form of enterotoxigenic colibacillosis associated with an angiopathy in the brain and gut and a circulating exotoxin, Stx2e. An edema disease lesion of the duodenum is commonly seen at slaughter.

Materials and Methods: Over a 3-day period, fifteen, randomly selected cases of edema disease were collected at slaughter (pancreas, duodenum, draining lymph node and liver) and examined histologically. Pancreases were labelled immunohistochemically for caspase-3 and bcl-2 activity.

Results: All pigs had passed an antemortem inspection and had no other macroscopic lesions. All cases had peripancreatic edema, fat degeneration and serous inflammation. Although mild random inflammation was noted occasionally in a pancreas, suppurative pancreatitis, pleocellular pancreatitis and hemorrhage were notably absent, and exocrine pancreas of all cases had severe pancreatic apoptosis with occasionally early necrosis. Widespread angiopathy was not noted. Livers, lymph nodes and intestines were not affected.

Conclusions: The consistency of this lesion is startling. Apoptosis and cell-organelle dysfunction are key to the pathogenesis of pancreatitis, and the sequel of this lesion must be studied. Enteric exotoxins may have an unstudied role in pancreatitis in many species. Further, one wonders if humane handling during transport and slaughter may be involved, and more importantly, are there food safety issues to address with this condition.

Oral Presentations

Session C: Infectious Disease

HAEMORRHAGIC SYNDROME IN CATTLE BY SUBGENOTYPE BVDV-1h

V. Di Marco Lo Presti, G. Purpari, E. Biasibetti*, M. T. Capucchio*, V. Cannella, P. Di Marco, F. Mira, G. Guarneri, M. Fiasconaro, B. Amato, A. Guercio

*Istituto Zooprofilattico of Sicily and *Dept. Veterinary Sciences, University of Torino, Italy*

dimarco.vince@gmail.com

Introduction: Bovine Viral Diarrhoea-Mucosal Disease (BVD-MD) is caused by a *Pestivirus*. Two genotypes are recognized: BVDV-1 and BVDV-2. BVDV-1 causes diarrhoea, respiratory disorders and reproductive disorders. BVDV-2 causes a haemorrhagic syndrome. The authors describe several hypervirulent-outbreak characterized by severe haemorrhagic symptoms caused by BVDV-1 in Sicily.

Materials and Methods: Serological (ELISA) and virological tests (virus isolation on MDBK cell cultures and RT-PCR) for BVD-MD were performed on sera, blood and organs. Moreover, assays for *Bacillus anthracis*, *Salmonella spp.*, *Mannheimia spp.*, IBR-virus and haematological test were carried out. Tissue samples were also submitted to histopathological investigations.

Results: Cattle from 15 farms showed oral ulceration, mucopurulent-haemorrhagic nasal discharge, haemorrhagic diarrhoea, haematuria and petechiae. Ulcerative-haemorrhagic lesions occurred in the mouth, tongue, subcutaneous tissue, gastrointestinal, vaginal and urinary tracts. Laboratory tests confirmed the presence of cytopathic BVD strain. Phylogenetic analysis, performed on the 5'UTR region, characterized the strains within the subgenotype BVDV-1h. Thrombocytopenia was confirmed.

Conclusions: In Sicily, BVD-MD is widely spread. Previous studies have shown a low level of heterogeneity among strains indicating the presence of BVDV-1b and BVDV-1e. Usually, haemorrhagic syndrome is caused by BVD-MD - 2. This is the first isolation of the BVD-MD-1h subgenotype associated with severe haemorrhagic outbreaks in calves.

Oral Presentations

Session D: Infectious, Wildlife & Neoplastic Disease

CENTRAL NERVOUS SYSTEM PATHOLOGY IN INFECTIOUS DISEASES OF CETACEANS STRANDED ON THE CATALAN MEDITERRANEAN SEA (1990-2013)

M. Isidoro*, S. Soto*, L. Pérez*, X. Cabañes*, M. Domingo*[†]

*Departament de Sanitat i Anatomia Animal, Facultat de Veterinària, UAB, [†]CreSA, UAB-IRTA, Cerdanyola del Vallès, Spain

marcosisidoro.ayza@e-campus.uab.cat

Introduction: Since the onset of the first Cetacean Morbillivirus (CeMV) epidemic (1990-1992), postmortem studies have been performed on stranded cetaceans found on the Catalan Mediterranean Sea. Relevant lesions have been frequently found in the central nervous system (CNS), being mostly associated to infectious agents.

Materials and Methods: Postmortem studies have been carried out on 3 different cetacean species (*Stenella coeruleoalba*, *Tursiops truncatus* and *Grampus griseus*), including gross and histopathological examination of the CNS, immunohistochemistry for CeMV, and in selected cases microbiological studies.

Results: The main finding in the CNS has been by far CeMV-associated non-suppurative encephalitis. Granulomatous-necrotizing encephalitis, due to active toxoplasmosis or aspergillosis has been found in association to systemic CeMV infections. Primary encephalitis due to *Toxoplasma gondii* has also been occasionally seen. Sporadic cases of suppurative encephalitis due to *Nocardia spp.* and *Porphyromonas asaccharolytica* have also occurred. Recently, the first case of severe non-suppurative meningoencephalomyelitis due to *Brucella ceti* and the first description of pyogranulomatous and necrotizing meningoencephalomyelitis associated with *Cunninghamella bertholletiae* were recognised.

Conclusions: Post mortem studies have been essential to reveal CNS infections as an important cause of cetacean stranding on the Catalan Mediterranean Sea. CeMV-associated encephalitis has been the main finding to date.

Oral Presentations

Session D: Infectious, Wildlife & Neoplastic Disease

CENTRAL NERVOUS SYSTEM ZYGOMYCOSIS IN A BOTTLENOSE DOLPHIN (*TURSIOPS TRUNCATUS*) CAUSED BY *CUNNINGHAMELLA BERTHOLLETIAE*

M. Isidoro*, L. Pérez*, X. Cabañes**†, G. Castellà**†, M. Andrés‡, M. Domingo*•

*Departament de Sanitat i Anatomia Animal and †Veterinary Mycology Group, Facultat de Veterinària, Universitat Autònoma de Barcelona, *Centre de Recerca en Sanitat Animal, UAB-IRTA, Cerdanyola del Vallès, Spain. ‡ Centro-Fundación para la Conservación y Recuperación de Animales Marinos, El Prat del Llobregat, Spain

marcosisidoro.ayza@e-campus.uab.cat

Introduction: Central nervous system (CNS) fungal infections are not unusual in bottlenose dolphins (*Tursiops truncatus*). Recently, it has been reported the first case of pneumonia associated with *Cunninghamella bertholletiae*, a fungus belonging to the Class Zygomycetes, in a captive killer whale (*Orcinus orca*). However, to date there are no descriptions of this fungus affecting the CNS of cetaceans.

Materials and Methods: A sub-adult, male bottlenose dolphin, found dead-stranded on the Catalan coast of the Mediterranean Sea, underwent a complete post mortem investigation including: gross examination, histopathology and microbiological isolation and characterization.

Results: At necropsy, multiple areas of malacia were macroscopically observed in the periventricular neuroparenchyma of the cerebrum. Microscopically, severe diffuse pyogranulomatous and necrotizing meningoencephalomyelitis and perineuritis were seen associated with abundant intralesional fungal structures invading vessels, fibrinoid vasculitis and thrombosis. The hyphae were thin walled, pleomorphic, pauciseptate, frequently wrinkled, and irregularly branched. *Cunninghamella bertholletiae* was identified by morphological characteristics and confirmed by molecular techniques.

Conclusion: To the authors' knowledge this is the first case reported of CNS zygomycosis due to *Cunninghamella bertholletiae* in a cetacean.

Oral Presentations

Session D: Infectious, Wildlife & Neoplastic Disease

C-KIT PATTERN EXPRESSION ANALYSIS IN EQUINE MAST CELL TUMOURS

S. Ward*, A. Kipar*, and L. Ressel*

**Veterinary Pathology, School of Veterinary Sciences, University of Liverpool, Liverpool, United Kingdom*

l.ressel@liverpool.ac.uk

Introduction: Equine mast cell tumours (MCT) are in the majority benign skin lesions, but multicentric, recurrent and metastatic tumours has been reported. In the dog, the KIT protein expression pattern is related to the biological behaviour of MCT. In equine MCT, however, the KIT status has so far not been systematically examined. The present retrospective study investigated the KIT expression pattern in equine MCT to identify its potential correlation with morphological parameters.

Materials and Methods: A total of 45 equine MCT from the diagnostic archive were stained immunohistochemically, using a well established cross reacting anti-human KIT antibody, and examined for their KIT staining pattern (I: membranous; II: focal cytoplasmic; III: diffuse cytoplasmic). Haematoxylin-eosin and toluidine blue stained sections were used to grade mitotic index, cellular atypia, granule density, mast cell/eosinophil ratio, growth pattern, vascular invasion and completeness of excision.

Results: Most MCT exhibited KIT pattern I (85.4%), and only 4.8% and 9.8% pattern II or III, respectively. Patterns II and III were significantly associated with a higher mitotic index, and showed a trend for positive correlation with increased anisokaryosis as well as infiltrative growth.

Conclusions: The present study supports the hypothesis that KIT protein dysregulation is involved in the biology of equine MCT, similar to its canine counterpart, for which the KIT pattern is used as a prognostic marker.

Oral Presentations

Session D: Infectious, Wildlife & Neoplastic Disease

ANALYSIS OF PROGESTERONE RECEPTOR ISOFORMS AND PROLIFERATION IN CANINE MAMMARY CARCINOMAS TREATED WITH THE ANTIPROGESTIN RU534

S.Guil-Luna*, J. Stenvang[†], N. Brünner[†], R. Sánchez-Céspedes*, Y. Millán*, J. Martín de las Mulas*.

*University of Córdoba, Spain and [†]University of Copenhagen, Denmark. v22gulus@uco.es

v22gulus@uco.es

Introduction: Studies in human breast cancer have established that progesterone receptor (PR) isoforms (PRA and PRB) expression has implications for hormone therapy responsiveness. In canine mammary tumours, PR expression, as measured by immunohistochemistry (IHC), has demonstrated to have predictive value of response to therapy with RU534. The aim of this work was, to analyze total PR (PRAB), PRA and PRB by RT-qPCR in RU534-treated canine mammary carcinomas and to compare with IHC PR expression and proliferation index (PI).

Materials and Methods: Twenty-seven nonspayed female dogs with mammary carcinomas were treated with either 2 doses of 20 mg/kg RU534 (n = 22) or oil placebo (n = 5). Tumour samples were taken before (day 1) and after (day 15) treatment. One-step SYBR Green RT-qPCR was used for the detection of PRAB, PRA and PRB. For IHC, PR10A9 and MIB-1 monoclonal antibodies were employed (PR expression and PI, respectively).

Results: RU534 treatment significantly decreased PI in PRAB-positive and PRA-positive carcinomas exclusively. No changes in PI were observed in tumours negative for PRAB, PRA and PRB. RU534 treatment was associated to a significant decrease of PRAB and PRA but not PRB expression.

Conclusions: Neoadjuvant RU534 treatment had an antiproliferative effect probably related with PRA expression in canine mammary carcinoma.

Acknowledgements: AGL2011-025553, PAIDI-BIO287

Oral Presentations

Session D: Infectious, Wildlife & Neoplastic Disease

EXPRESSION OF SOX9 AND SNAIL2 IN CANINE MAMMARY TUMOURS

L. Pritchard¹, G. Beha², K. Smith¹, B. Brunetti², G. Sarli², C. Benazzi², I. McGonnell¹

¹The Royal Veterinary College, London, United Kingdom ²Department of Veterinary Medical Sciences – University of Bologna, Italy

lpritchard@rvc.ac.uk

Introduction: Sox9 is a transcription factor expressed in chondrocytes and acts with Snail2 to increase matrix production and mammary stem differentiation in some breast carcinomas. The aim of this study was to examine expression of Sox9 and Snail2 in mixed mammary tumours, complex adenomas and carcinomas from dogs.

Materials and Methods: Twenty-one canine mammary tumours and three hyperplasias were labelled using anti-Sox9 and anti-Snail2 antibodies. To identify epithelial and myoepithelial cells, immunohistochemistry and immunofluorescence was performed using anti-CK18 and anti-p63, -AlphaSMA, -vimentin, -CD10 antibodies respectively

Results: Sox9 and Snail2 immunoreactivity was seen in nuclei of both epithelial and myoepithelial cells. Epithelial labelling was lower in tumours compared to hyperplasias. Myoepithelial expression of Sox9 and Snail2 varied based on the myoepithelial morphology. Suprabasal myoepithelial cells (p63+, Alpha-SMA+) were positive in hyperplasias and tumours. Motile myoepithelial cell nests (vimentin+) showed variable positivity; small nests showed strong positivity but was lost in larger nests. Chondrocytes were positive for Sox9.

Conclusion: Reduced Sox9 expression in neoplastic epithelium may be useful as an early biomarker of epithelial change, as also suggested in the human literature. Sox9 expression in some myoepithelial nests could indicate potential to acquire a chondrocytic phenotype, while those nest and epithelial cells also positive for Snail2 could function as regulators of stem differentiation.

Oral Presentations

Session D: Infectious, Wildlife & Neoplastic Disease

CONSENSUS PROPOSAL ON ESSENTIAL PHENOTYPE MARKERS AND HORMONE RECEPTOR ASSESSMENT IN CANINE MAMMARY TUMORS.

L. Peña¹, A. Gama², M. Goldschmidt³, J. Abadie⁴, C. Benazzi⁵, M. Castagnaro⁶, L. Díez¹, F. Gartner⁷, E. Hellmen⁸, M. Kiupel⁹, Y. Millán¹⁰, M. Miller¹¹, F. Nguyen⁴, A. Poli¹², G. Sarli⁵, V. Zappulli⁶, J. Martin de las Mulas¹⁰

¹ Complutense University of Madrid, Spain.

² University of Trás-os-Montes and Alto Douro, Vila Real, Portugal.

³ University of Pennsylvania, Philadelphia, USA.

⁴ LUNAM University, Nantes, France.

⁵ University of Bologna, Italy

⁶ University of Padua, Italy

⁷ University of Porto, Portugal

⁸ Swedish University of Agricultural Sciences, Uppsala, Sweden.

⁹ Michigan State University, East Lansing, MI, USA

¹⁰ University of Córdoba, Spain.

¹¹ Purdue University, West Lafayette, Indiana, USA.

¹² University of Pisa, Italy

laurape@vet.ucm.es

Introduction: Immunohistochemistry (IHC) has played an increasing role as a diagnostic tool for the identification of neoplasms and pathogens. In dogs with mammary tumors (CMTs), there have been an increasing number of studies looking for reliable diagnostic and/or prognostic immunohistochemical biomarkers but no consensus has been reached. These studies cannot be compared because of the differences in how these biomarkers have been used and evaluated.

Materials and Methods: Review of the literature including IHC markers on CMTs in order to detect the best immunolabeling and evaluation systems for each marker.

Results: After the review process, the authors reached a consensus regarding practical questions related to the methodology and provide guidelines on immunolabeling for CMTs markers along with the specific recommendations for interpretation of the results for each of these biomarkers in CMTs.

Conclusion: By standardizing the methods used for labeling and interpretation of these IHC markers, we aim to ensure consistency and reproducibility of future study results.



Oral Presentations

Session E: Neoplastic Disease

THE DOG AS A SPONTANEOUS MODEL TO STUDY MAMMARY MYOEPITHELIAL BASAL CELL LINEAGE AND ITS ROLE IN MAMMARY CARCINOGENESIS

R.Rasotto*, M.Goldschmidt †, M.Castagnaro*, P.Carnier*, D.Caliari*, V.Zappulli*

*Department of Comparative Biomedicine and Food Science, University of Padova, Italy

†Department of Pathobiology, University of Pennsylvania, USA

robertarasotto@yahoo.it

Introduction: Basal-like human breast cancers (HBCs) are hypothesized to originate from either myoepithelial or mammary progenitor cells. They are heterogeneous in morphology and outcome. To better understand their biology, the study of cell lineages of normal human breast has assumed increasing importance. This work evaluated the potential of canine mammary carcinomas (CMCs) as a spontaneous model for basal-like HBCs.

Materials and Methods: Single and double immunohistochemical analyses were performed on serial sections of 10 normal canine mammary glands and 65 CMCs for CK8/18, CK5, CK14, α -smooth muscle actin (SMA), calponin, p63, and vimentin. Ki-67 and HER-2 were also evaluated in CMCs.

Results: Previously unrecognized cell subpopulations were identified in the normal canine mammary gland: progenitor cells (CK5+, CK14+, p63+, vimentin+), intermediary luminal glandular cells (CK5+, CK14+, CK8/CK18+), intermediary myoepithelial cells (CK5+, CK14+, p63+, SMA+, calponin+, vimentin+), and terminally differentiated luminal glandular (CK8/18+) and myoepithelial (calponin+, SMA+, vimentin+) cells. Myoepithelial cells of complex carcinomas were immunohistochemically similar to terminally differentiated myoepithelial cells, while those of carcinomas-and-malignant myoepitheliomas (that had a poorer prognosis), were comparable to intermediary myoepithelial cells and had higher Ki-67 expression.

Conclusions: The biphasic appearance of CMCs with involvement of the myoepithelium in different stages of cell differentiation may help to define the role of myoepithelial cells in mammary carcinogenesis and the heterogeneous nature of basal-like HBCs.

Oral Presentations

Session E: Neoplastic Disease

HISTOLOGICAL GRADING OF CANINE MAST CELL TUMOUR: IS TWO BETTER THAN THREE?

F. Scarpa*, S. Sabbatini*, D. Berlato† and G. Bettini*

*DIMEVET, University of Bologna, Italy and †AHT, Newmarket, UK

giuliano.bettini@unibo.it

Introduction: Mast cell tumour (MCT) is a common canine cutaneous neoplasia with variable behaviour. Recently, a two-tier grading system has been proposed by Kiupel (KS) to reduce the interobserver variation and eliminate the prognostic uncertainty of the Patnaik system (PS). This study aims to compare their ability to predict outcome in a cohort of dogs with cutaneous MCT.

Materials and Methods: 137 surgically-resected cutaneous MCTs were examined. For each case the histological grade was assessed according to PS and KS, and prognostic relevance evaluated with survival analysis.

Results: Median follow-up time was 1183 days. According to PS, there were 18(7.6%) G1 MCTs, 83(60.6%) G2 and 36(26.3%) G3. All G1 were low-grade (LG) in KS, and all G3 were high-grade (HG); among G2, 71(85.6%) were LG, and 12(14.4%) HG. The 1-year-survival probability was 100% for G1, 87% for G2 and 16% for G3. Among G2, the survival probability was 94% for LG and 46% for HG ($P < 0.001$). Median survival was 698 days for HG-G2 MCTs, and 108 days for HG-G3 ($P = 0.027$).

Conclusion: The KS was able to predict the negative prognosis of some G2 MCTs. Similarly, HG MCTs classified G3 with PS had a significantly shorter survival than those classified G2. The simultaneous use of both systems might provide a more accurate prognosis than each system used individually.

Oral Presentations

Session E: Neoplastic Disease

PTEN AND E-CADHERIN EXPRESSION ARE ASSOCIATED IN CANINE MAMMARY TUMORS

P. Asproni*, L. Ressel[†], F. Millanta*, I. Vannozzi* and A. Poli*

* Department of Veterinary Sciences, University of Pisa, Italy and [†]Department of Veterinary Pathology, University of Liverpool, UK

pietro.asproni@for.unipi.it

Introduction: PTEN is a tumor suppressor protein that negatively regulates tumor growth and invasiveness. E-cadherin is a trans-membrane molecule known for its tumor invasion-suppressor role. In human medicine, it has been hypothesized that the expression of these two proteins is correlated. The aim of this study is to evaluate by immunohistochemistry if their expression is associated also in canine mammary tumors.

Materials and Methods: Fifty-four canine mammary samples (15 hyperplasias, 7 adenomas and 32 carcinomas) were submitted to immunohistochemistry for the evaluation of PTEN and E-cadherin expression. Subjects bearing mammary carcinoma were also submitted to a 2-year follow-up study to compare overall survival with PTEN and E-cadherin expression.

Results: All the hyperplasias expressed both the markers, 100% of adenomas were positive for PTEN and 86% for E-cadherin, and 69% and 34% of carcinomas were positive for PTEN and E-cadherin, respectively. PTEN and E-cadherin expression was statistically correlated in all the tumors ($p < .01$) and in the malignant ones ($< .05$). The group positively-stained for the two markers correlated with a longer overall survival ($< .05$) and with the absence of lymphatics invasion ($< .05$).

Conclusions: Our results confirm the correlation between PTEN protein and E-cadherin expression and the tumor suppressor effect of this association in canine mammary tumors.

Oral Presentations

Session E: Neoplastic Disease

EXPRESSION OF BCL-2, BCL-X_L, BAX AND APOPTOTIC INDEX IN CANINE MAMMARY TUMOURS: CORRELATION WITH CLINICOPATHOLOGICAL FACTORS

F. Yildirim*, K. Sonmez*, H. Ozyogurtcu*, G. Sennazli*, A. Gurel*, M.C. Gunduz† and H. B. Sontas‡

*Department of Pathology and †Department of Gynecology and Obstetrics, Faculty of Veterinary Medicine, Istanbul University, Istanbul, Turkey and ‡Section for Obstetrics and Reproduction, University of Veterinary Science Vienna, Austria

funda@istanbul.edu.tr

Introduction: Mammary tumours are the most common neoplasms in female dogs. Dysregulation of normal programmed cell death mechanisms play an important role in the pathogenesis and progression of mammary gland tumours. The aim of this study is to investigate the relationship between apoptosis, histopathological classification, tumour grading and staging of canine mammary tumours (CMT).

Materials and Methods: Twenty seven tissue samples were collected from twenty seven animals with mammary tumours. The samples were evaluated and graded histopathologically. All cases were staged according to the TNM system. The expression of Bcl-2, Bcl-X_L and Bax proteins was investigated by immunohistochemistry and apoptosis was evaluated by terminal deoxynucleotidyltransferase (TdT)-mediated nick end-labeling (TUNEL) technique.

Results: The statistical relation between tumour histomorphology and Bcl-2 expression was very significant ($p=0.001$). There were statistically significant differences between T1 and T5 ($p=0.006$), T2 and T5 ($p=0.037$) tumours in terms of Bax expression through Mann Whitney U Test.

Conclusions: In this study, it is concluded that overexpression of Bcl-2 in highly malignant tumours and the high expression of Bax in metastatic tumours can be auxiliary parameters for predicting the biologic behaviour and prognosis of CMT.

Oral Presentations

Session E: Neoplastic Disease

CORRELATION BETWEEN CYTOLOGY AND HISTOPATHOLOGY IN THE DIAGNOSIS OF SPLENIC NEOPLASMS IN DOGS.

A. Forlani *, M. Caniatti *, S. F. Santagostino *, B. Vicini *, C. Luraschi *, P. Roccabianca *

* DIVET, School of Veterinary Medicine University of Milan, Italy

annalisa.forlani@unimi.it

Introduction: The spleen can be affected by a variety of diseases and cytology represents a useful diagnostic technique. However, few studies have addressed the accuracy of cytology in the evaluation of splenic lesions and specifically neoplasms.

Materials and Methods: Splenic cytological and corresponding histopathological samples obtained between 1998 and 2012 were retrospectively evaluated. Concordance between cytology and histology was determined. Accuracy, sensibility, specificity, positive and negative predictive value of cytology for the diagnosis of splenic neoplasia was determined considering histopathology as the gold standard.

Results: Sixty-six cases were collected. Thirty cytological samples were classified as non-neoplastic (12 true negatives, 18 false negatives compared with histopathology). Cytological diagnosis of neoplasia was obtained in 36 cases (35 true positives and 1 false positive). Cytological diagnosis was in agreement with the histopathological diagnosis in 71, 2% (47/66) of cases. Cytology had a sensitivity of 66%, a specificity of 92%, a positive predictive value of 97%, and a negative predictive value of 40% in the diagnosis of splenic neoplasms. The majority of cases were non neoplastic (30/66), most common tumors were sarcomas (20/67) followed by lymphoma (7/66).

Conclusions: Although cytopathology and histopathology should be considered complementary techniques in the diagnosis of splenic lesions, cytology demonstrated to be a useful tool for splenic neoplasia diagnosis.

Oral Presentations

Session E: Neoplastic Disease

E-CADHERIN DYSFUNCTION IN CANINE GASTRIC CANCER

I. Amorim*‡, J. Carvalho‡, A. Rema*, M. Taulescu†, A.L. Saraiva+, A.M. Faustino*, C.A. Reis*‡, C. Oliveira‡, F. Gärtner*‡

**Institute of Biomedical Sciences Abel Salazar, University of Porto, Portugal*

‡Institute of Molecular Pathology and Immunology, University of Porto, Portugal

† Faculty of Veterinary Medicine, of Agricultural Sciences and Veterinary Medicine, Cluj-Napoca, Romania

+Escola Universitária Vasco da Gama, Coimbra, Portugal

iamorim@ipatimup.pt

Introduction: Genetic and/or epigenetic alterations in E-cadherin-encoding gene (CDH1) or alterations in its protein expression, often result in tissue disorder, cellular de-differentiation, increased invasiveness of tumour cells and ultimately in metastasis. In humans, CDH1 is regarded as a classical tumour suppressor gene in gastric carcinogenesis, being involved in the initiation and progression of both sporadic and hereditary forms. The aim of our study is to evaluate the potential role of E-cadherin (E-cad) and its encoding-gene (CDH1) in canine gastric carcinomas.

Materials and Methods: 21 normal canine gastric mucosal tissue specimens and 21 specimens of canine gastric carcinomas were examined for E-cad expression and tested for somatic CDH1 alterations using immunohistochemistry and PCR-Sequencing, respectively.

Results: The great majority of canine gastric carcinomas showed abnormal E-cad expression in comparison with the normal gastric mucosa.

Conclusions: The different patterns of E-cad immunoexpression observed in canine gastric carcinomas are similar to those already described in human gastric cancer and the existence of CDH1 somatic alterations in such lesions may be valuable and promising information for the clinical management and prognosis of these animals.

Oral Presentations

Session E: Neoplastic Disease

CANINE PAPILLOMAVIRUS 1 (CPV1): A RETROSPECTIVE IMMUNOHISTOCHEMICAL AND REAL TIME PCR INVESTIGATION ON 88 ORAL LESIONS OF DOGS

I. Porcellato*, C. Brachelente*, G. Guelfi*, A. Reginato*, M. Sforza*, L. Mechelli*

**Department of Biopathological Sciences and Hygiene of Animal and Alimentary Productions, University of Perugia, Perugia, Italy*

ilariaporcellato@yahoo.it

Introduction CPV1 (also called COPV) is a papillomavirus responsible for oral papillomatosis mostly in young dogs. The involvement of this virus in oral oncogenesis has been already hypothesized, especially in oral squamous cell carcinomas (SCC).

Materials and Methods In the present study, 88 different oral tumors (papillomas, SCCs, melanomas, ameloblastomas and oral adenocarcinomas) and hyperplastic lesions (gingival hyperplasia) from formalin fixed and paraffin embedded specimens (FFPE) were retrospectively investigated for the presence of viral proteins (immunohistochemistry) and of CPV1 DNA (real time PCR).

Results Results from this study revealed the presence of CPV1 DNA in all oral viral papillomas tested. Viral DNA was also demonstrated in 3/33 SCCs that were negative at the immunohistochemical investigation. Conversely, no positivity was encountered both with immunohistochemistry and real time PCR in other specimens obtained from hyperplastic and neoplastic lesions of the oral cavity of dogs.

Conclusions The study demonstrates that CPV1 is strongly associated with oral papillomatosis and that the contribution of this virus in the pathogenesis of other oral lesions is unlikely. The finding of CPV1 DNA in few SCCs in face of a negative immunohistochemistry supports the hypothesis of an abortive viral infection in the development of these lesions.

Oral Presentations

Session E: Neoplastic Disease

IMMUNOHISTOCHEMICAL STUDY OF EXPRESSION OF CAVEOLIN-1(CAV-1) IN CANINE MALIGNANT MAMMARY TUMORS AS A GOOD MODEL IN HUMAN STUDIES

Hannaneh Golshahi*, Abbas Tavasoli*, Annahita Rezaie†, Mohammad Farhadi‡

*Department of Pathology, Faculty of Veterinary Medicine, University of Tehran, Tehran, Iran† Department of Pathobiology, Faculty of Veterinary Medicine, University of Shahid Chamran, Ahvaz, Iran‡ Iranian Blood Transfusion Organization, Tehran, Iran

h.golshahi@ut.ac.ir

Introduction: Caveolin-1 is thought to have an important impact on both signal transduction and mediation of intracellular processes. It has been suggested that Caveolin-1 may contribute to certain steps of carcinogenesis in various types of cancer. Furthermore, canine mammary tumors have attracted considerable attention over the years as possible animal models for human mammary neoplasia, based on their morphological and biological similarities.

Materials & Methods: Cav-1 immunohistochemical expression was studied in 37 canine malignant mammary tumor to investigate the relationship of histopathological type, histopathologic grade with the expression of Cav-1.

Result: Cav-1 was expressed by epithelial cells in 33 of 37 (89.2%) malignant mammary tumors. There was a significant relationship between epithelial expression of Cav-1 and histological grade of tumors ($P < 0.05$). No significant relationship was observed between histological grade and expression of Cav-1 in myoepithelial or mesenchymal cells.

Conclusion: This study showed that Cav-1 can be used as a prognostic factor in humans and dog cancer research and its expression is associated with more malignant mammary tumors.

Oral Presentations

Session F: Neoplastic Disease

MAMMARY TUMORS IN PET RABBITS (ORYCTOLAGUS CUNICULUS) CLASSIFICATION AND EPIDEMIOLOGY

Berit Baum* and Marion Hewicker-Trautwein[†]

*Vetmedlabor Div. IDEXX, Ludwigsburg, [†]University of Veterinary Medicine, Hannover, Germany

Berit-baum@idexx.com

Introduction: Mammary tumors are common neoplasms in aging pet rabbits with increasing numbers in submissions for histopathologic services. However, data available are predominantly derived from laboratory rabbits. This study aims to provide basic facts on this disease in pet rabbits.

Materials and Methods: 119 different neoplasms from 109 pet rabbits submitted for routine histopathology services were examined. Epidemiology, clinical and histologic presentations were investigated and classified according to the WHO-classification for mammary tumors in dogs and cats.

Results: All 90 patients with known gender were females. The age span reached from 2 to 14 years, with a mean age of 5.5 years. The age of patients with carcinomas was statistically significantly higher than of patients with adenomas ($p < 0.05$). Cranial and caudal, left and right mammary glands were equally affected. The diameter of the neoplasms varied between 4 and 100 mm, with benign lesions having a statistically significantly smaller diameter ($p < 0.01$). The vast majority of neoplasms exhibited morphologic criteria of malignancy (88 %). Predominantly tubulopapillary carcinomas occurred (56 %). A high percentage of neoplasms exhibited squamous differentiation in variable degrees (17 %). Complex neoplasms were rare (4%).

Conclusions: Mammary tumors in rabbits are significantly different to those in dogs, with a higher percentage of malignancy, equal affection of all mammary glands, lower numbers of complex tumors and more squamous differentiation, more closely resembling the situation in cats.

Oral Presentations

Session F: Neoplastic Disease

IGF-1R IS CORRELATED TO POOR SURVIVAL IN CANINE APPENDICULAR OSTEOSARCOMA AND COULD BE CONSIDERED A NEW PROGNOSTIC FACTOR

L. Maniscalco*, S. Lussich*, E. Morello*, M. Martano*, F. Gattino*, B. Biolatti*, P. Buracco* and De Maria Raffaella*

**Department of Veterinary Sciences, University of Turin, Italy*

lorellamaniscalco@yahoo.it

Introduction: The insulin-like growth factor1 receptor (IGF-1R) is a cell membrane receptor involved in different human cancers. In human osteosarcoma IGF-1R expression is related to the development of tumor metastasis and poor prognosis and it represents a suitable target for biological therapy. The aim of this study was to investigate the prognostic and therapeutic significance of IGF-1R in canine osteosarcoma.

Materials and Methods: 36 appendicular osteosarcoma were collected, immunohistochemistry was performed to analyze the correlation between IGF-1R expression and clinic-pathological features. RT-PCR and western blot assays were performed to detect IGF-1R and their downstream effectors MAPK and AKT in 7 primary canine osteosarcoma cell lines. Finally, the effects of IGF-1R inhibitor, PPP, were tested in vitro.

Results: Patients with higher levels of IGF-1R expression (44.12% of cases) had poorer survival if compared with patients with lower expression. q-PCR and western blot demonstrated that 5/7 cell lines overexpressed IGF-1R and showed AKT and MAPK activation. The IGF-1R inhibition resulted in apoptotic effects in vitro.

Conclusions: These results demonstrate that the increased expression of IGF-1R is correlated to poorer survival in canine appendicular osteosarcoma suggesting that IGF-1R is involved in canine osteosarcoma progression and could be considered a new prognostic factor as well as a suitable target therapy.

Oral Presentations

Session F: Neoplastic Disease

MAST CELL INFILTRATION AND KIT AND PROTEASE EXPRESSION DURING PROGRESSION OF A TRANSGENIC PROSTATE CANCER MURINE MODEL (TRAMP)

González, C¹; Armisen, R²; Stutzin, A²; Baez, P; Landerer, E¹; Paredes, R¹; Contreras, I¹; Muñoz, C¹.

*Institution(s):*¹-School of Veterinary Medicine, Universidad Andrés Bello, ²-Facultad de Medicina, Universidad de Chile

carlosgonzalez@unab.cl

Introduction: Mast cells (MCs) seem to play a key role in cancer thanks to molecules they secrete that benefit tumor growth and progression including proteases such as tryptase and chymase, which disrupt the surrounding matrix and facilitate metastases. KIT (CD117) is a transmembrane receptor, with tyrosine kinase activity, and its activation is critical for mast cell homeostasis and function.

Materials and Methods: Primary antibody reactivity was detected by UltraVisionLP HRP polymer & DAB PLUS kit (Thermo). Computer-assisted morphometric analysis was done with Olympus microscope FSX 100 connected to a computer with software for morphometric analysis (ImageProPlus).

Results: MCs were detected in prostates from TRAMP mice at 12, 24 and 32 weeks old. A significant increment of MCs was detected during the progression from intraepithelial neoplasia to invasive and metastatic prostate cancer. Mast cells grew bigger with stronger KIT expression and followed metastatic neoplastic cells to lymph nodes and lung tissue. Most MCs expressed tryptase or chymase with a minor double positive population.

Conclusions: An association with the increment of KIT+/tryptase+ MCs and the progression of early PIN lesions to advanced stages of invasive carcinoma with lymph node and lung metastasis was seen in this study.

Financing: FONDECYT1121202, FONDAP 1501006

Oral Presentations

Session F: Neoplastic Disease

CREATING A CHIMERIC ANTIGEN RECEPTOR FOR CANCER IMMUNOTHERAPY IN DOGS

S.M. Keller*, M. Schjaerff*, R. Rebhun†, P.F. Moore*

**Department of Pathology, Microbiology and Immunology and †Department of Surgical and Radiological Sciences, University of California Davis School of Veterinary Medicine, Davis, USA*

smkeller@ucdavis.edu

Introduction: Adoptive immunotherapy is a novel cancer treatment in which patient cytotoxic T cells are re-directed to recognize a tumor associated antigen through endowment with a chimeric antigen receptor (CAR). The objectives of this study were 1) to create a third generation chimeric antigen receptor against CD1a, an antigen commonly expressed by canine histiocytic sarcomas and 2) to verify its expression in an adhesive cell line.

Materials and Methods: The specificity of the monoclonal antibody CA13.9H11 (Ab9H11) was assessed by expression of its putative ligand canine CD1a in HEK 293 cells. An anti-CD1a CAR was generated by splice overlap extension PCR, cloned into a green fluorescent protein tagged expression vector and chemically transfected into HEK293 cells. CAR expression was assessed by flow cytometry and fluorescent microscopy.

Results: Canine CD1a was confirmed as the ligand of Ab9H11. A third generation anti-CD1a CAR was successfully assembled and transfected into 293 cells. CAR protein expression was confirmed by flow cytometry and fluorescent microscopy suggested surface expression of the receptor.

Conclusions: This study provides the basis for establishing adoptive immunotherapy in a companion animal species. Future work will be directed at expressing the CAR in cytotoxic T cells using a lentiviral expression system and verifying its functionality *in-vitro*.

Oral Presentations

Session G: Cardiovascular & Forensic Disease

SOLID LIPID NANOPARTICLES AS ANTINEOPLASTIC DRUGS VEHICLES IN GLIOBLASTOMA MULTIFORME: IN VITRO AND IN VIVO PATHOLOGICAL EFFECTS

E.Biasibetti, L.Battaglia*, M.Gallarate*, E.Peira*, D.Chirio*, E.Muntoni*, A.Valazza, M.Lanotte**, PP.Panciani**, C.Riganti§, L.Annovazzi@, V.Caldera@, D.Schiffer@ and M.T.Capucchio

Dept. Veterinary Sciences, *Dept. Drug Science and Technology, **Dept. Neuroscience, §Dept. Oncology, University of Torino and @Neuro-Bio-Oncology Center, Policlinico of Monza, Vercelli, Italy

mariateresa.capucchio@unito.it

Introduction: Solid lipid nanoparticles (SLN) are biocompatible systems made of physiological lipids proposed to be used as antineoplastic drug carriers in glioblastoma treatment. The authors report the *in vitro* and *in vivo* changes to compare the effects of SLN, free drug and SLN-loaded drug.

Materials and Methods: Liphophilic drug (paclitaxel) was entrapped in SLN prepared with fatty acid coacervation technique. Glioblastoma cell lines and C6-implanted Wistar rats were used to test the effects *in vitro* and *in vivo* respectively. Evaluation of cytotoxicity was performed by Trypan blue exclusion test and MTT method at different times and concentrations. Liver, kidney, heart, lung and brain samples of rats were collected to evaluate pathological lesions.

Results: Paclitaxel loaded SLN produced a significant cell death on cell lines similar to or slightly increased in comparison with the drug alone. Ultrastructurally the main lesions were vacuoles in mitochondria, lysis and glycogen accumulation. Not significant lesions were detected in rats' liver, kidney and heart. Pulmonary granulomatous and adaptative changes, whose aetiopathogenetic mechanism remains to be clarified, were observed.

Conclusion: SLN-loaded drug seems more efficient in producing cell death. Further investigations will lead to a better understanding of the mechanism of the reported changes.

Oral Presentations

Session G: Cardiovascular & Forensic Disease

SEROTONIN 2B RECEPTOR EXPRESSION IN CANINE CARDIAC DISEASE

Sonja Fonfara^{*,†}, Udo Hetzel^{*}, Anja Kipar^{*}

**Veterinary Pathology, Department of Basic Veterinary Sciences, Faculty of Veterinary Medicine, University of Helsinki, Finland; [†]Companion Animal Studies, University of Bristol, UK*

akipar@liverpool.ac.uk

Introduction: Serotonin (5-HT) signaling in the heart is mediated by receptor subtype 2B (5-HTR2B). While contribution of serotonin to canine valvular disease is reported, the role of 5-HTR2B role in other canine cardiac diseases is not yet known.

Materials and Methods: Blood samples of each nine healthy control dogs and dogs with congestive heart failure (CHF), and myocardial samples of eight healthy control dogs, nine dogs with cardiac diseases and six dogs with systemic non-cardiac diseases were investigated for 5-HTR2B transcription by quantitative PCR (qPCR). Myocardial results were correlated with the transcription of cytokines, matrix metalloproteinases (MMP) and tissue inhibitors of matrix metalloproteinase (TIMP). To identify cells producing 5-HTR2B, laser microdissection with subsequent qPCR and immunohistology were applied.

Results: Control dogs exhibited constitutive 5-HTR2B transcription in blood and myocardium. Dogs with CHF showed significantly higher circulating 5-HTR2B levels than control dogs, while myocardial 5-HTR2B transcription was significantly highest in dogs with dilated cardiomyopathy (DCM) compared to all other groups, and a positive correlation of 5-HTR2B with several cytokines, MMPs and TIMPs was observed. Myocytes were identified as the source of 5-HTR2B mRNA and protein.

Conclusions: The present study provides evidence that serotonin plays a role in normal cardiac structure and function and is involved in CHF and the pathogenesis of DCM.

Oral Presentations

Session G: Cardiovascular & Forensic Disease

EFFECTS OF SKIN BARRIER DISRUPTIONS ON THE PENETRATION OF AHAPS-FUNCTIONALIZED SILICA NANOPARTICLES IN THE MOUSE

A. Ostrowski*, D. Nordmeyer#, L. Mundhenk*, J. Fluhr†, C. Graf#, E. Rühl#, A. D. Gruber*

*Department of Veterinary Pathology and #Institute of Chemistry and Biochemistry - Physical and Theoretical Chemistry, Freie Universität Berlin, Germany and †Department of Dermatology, Venerology und Allergology, Charité - Universitätsmedizin Berlin, Germany

anja.ostrowski@fu-berlin.de

Introduction: The skin is a possible route of entry for nanoparticles (NP) in various biomedical applications. However, the role of a disturbed barrier function on altered skin penetration remains widely unclear to date. This study aimed at identifying effects of different kinds of skin barrier disruptions on the penetration of silica NP in the mouse.

Materials and Methods: Fluoresceine-labeled silica NP (diameter of 55 ± 6 nm) with a N-(6-aminohexyl)(3-aminopropyl)trimethoxysilane (AHAPS)-functionalization were topically applied either on tape stripped, on inflamed or on healthy skin of SKH1 mice (n=3 per group) for one or five consecutive days, respectively. 24 h after the final treatment the mice were sacrificed and tissues were examined histopathologically. NP were detected by fluorescence microscopy.

Results: The silica NP were localized in superficial layers of the stratum corneum but not in deeper epidermal or dermal layers, regardless of the kind of barrier disruption.

Conclusion: We conclude that AHAPS-functionalized silica NP may not penetrate healthy, superficially disrupted or inflamed skin. We will now examine skin, draining and non-draining lymph nodes by transmission electron microscopy for a more sensitive localization of single NP.

Oral Presentations

Session G: Cardiovascular & Forensic Disease

ESTABLISHING A RAT MODEL FOR PROLONGED CARDIAC ARREST: INFLUENCE OF ARREST DURATION ON HIPPOCAMPAL LESIONS

S. Högler*, U. Teubenbacher*, A. Janata[†], W. Weihs[†], I.A.M. Magnet[†], F. Ettl[†], F. Sterz[†], P. Schmidt*

*University of Veterinary Medicine Vienna, [†]Medical University of Vienna, Austria

sandra.hoegler@vetmeduni.ac.at

Introduction: Cardiac arrest (CA) is a major health issue in modern society. Strategies to increase the survival rate and to reduce neurological sequelae are crucial.

Materials and Methods: Male Sprague-Dawley rats underwent artificial CA for 6 or 8 min (n=10/group), followed by 2 min of cardiopulmonary resuscitation. After defibrillation and restoration of spontaneous circulation animals were sacrificed at day 14. Sham animals (n=4) were subjected to the same procedure except for CA. Formalin-fixed and paraffin-embedded slides of the hippocampal CA1 region were stained with HE and lesions were assessed using a semiquantitative scoring system.

Results: Seven animals of the 6 min group and six animals of the 8 min group gained restoration of spontaneous circulation and were included in histological analysis as well as all sham animals. All animals subjected to CA showed consistent lesions in the hippocampal CA1 region, while sham animals showed no damage. There were statistically significant differences between the sham group and both arrest groups. Furthermore, we found significantly more severe lesions in the 8 min group compared to the 6 min group.

Conclusions: We were able to establish a rat model for CA causing consistent lesions in the hippocampal CA1 region. 8 min of CA will be used for further research regarding neuroprotective therapies.

Oral Presentations

Session G: Cardiovascular & Forensic Disease

FORENSIC CASES OF BRUISES IN PIGS

K. Barington and H.E. Jensen

Department of Veterinary Disease Biology, Faculty of Health and Medical Sciences, University of Copenhagen, Denmark

Elvang@life.ku.dk

Introduction: Bruises in pigs inflicted by trauma are a significant animal welfare problem. Affected skin and muscle are regularly submitted for forensic investigation. Central to the evaluation is an assessment of the age of bruises.

Materials and Methods: Cases of bruises in pigs sent for forensic investigation were collected retrospectively. Data consisted of photos of the gross lesions, slides for histology, and a written description of each case. The time from collecting the animals and delivery for slaughter was recorded together with the time of slaughter.

Results: Since 2005 there has been an increase in cases, with a peak in 2008 and 2009 counting 40 cases each year. At gross examination, the pattern of bruises often reflected the object by which the bruise was inflicted. Histologically, hemorrhage and cellular infiltrations were frequently present. However, in 21.7% of cases a reaction was absent, making estimation of age impossible. Currently, the age of bruises may be estimated to be more or less than four hours. The time from collecting the pigs until slaughtering was in 44.1% of cases between 1 and 4 hours, during which time the pigs had been handled by more people.

Conclusions: Precise methods to estimate the age of bruises with and without an inflammatory reaction is needed in order to determine in whose custody the pigs were when the bruises were inflicted.

Oral Presentations

Session G: Cardiovascular & Forensic Disease

AORTIC MEDIA ULTRASTRUCTURE IN A HEALTHY FRIESIAN HORSE AND IN A FRIESIAN HORSE WITH AORTO-PULMONARY FISTULA

V. Saey*, K. D'Herde^β, M. Ploeg*, K. Chiers*, C.J.G. Delesalle[□], A. Gröne*, W. Back^{□,‡}, C.M. de Bruijn[°], G. van Loon[€] and R. Ducatelle*

*Department of Pathology, Bacteriology and Avian Medicine, Faculty of Veterinary Medicine, Ghent University, Merelbeke, Belgium

^βDepartment of Basic Medical Sciences, University Hospital, Ghent University, Ghent, Belgium

•Department of Pathobiology, Faculty of Veterinary Medicine, Utrecht University, Utrecht, The Netherlands

[□]Department of Equine Sciences, Faculty of Veterinary Medicine, Utrecht University, Utrecht, The Netherlands

[‡]Department of Surgery and Anaesthesiology of Domestic Animals, Faculty of Veterinary Medicine, Ghent University, Merelbeke, Belgium

[°]Wolvega Equine Hospital, Oldeholtade, The Netherlands

[€]Department of Large Animal Internal Medicine, Faculty of Veterinary Medicine, Ghent University, Merelbeke, Belgium

veterinaire.pathologie@ugent.be

Introduction: A thoracic aortic rupture is extremely rare in any animal species and in humans. Recently, a series of 24 cases was reported in the Friesian horse breed (Ploeg et al, 2013). The rupture typically was a straight transverse tear near the scar of the ligamentum arteriosum and was in many cases associated with aorto-pulmonary fistulation. To improve our understanding of the presumably genetic pathway of this disease, an ultrastructural study of the aortic media away from the lesion was performed.

Materials and Methods: Samples from the middle thoracic aorta of a clinically healthy Friesian horse (FH) and a Friesian horse with aorto-pulmonary fistulation (FAP) were fixed in cacodylate buffered glutaraldehyde/paraformaldehyde solution and processed for transmission electron microscopy.

Results: The FAP showed a significant increase in density and size of the smooth muscle cells. These cells had more pronounced organelles in the perinuclear cytoplasm (mitochondria, rough endoplasmic reticulum, Golgi) and subplasmalemmal vacuoles.

Conclusion: Hypertrophy, hyperplasia and increased metabolic activity of vascular smooth muscle cells was found in the clinical fistula/rupture case and has also been reported in humans and animal models of hypertension. It is likely that the compensatory changes of the smooth muscle cells are due to mechanical stresses.



Oral Presentations

Session H: Inflammatory, Skin & Wildlife Disease

INFECTIOUS CANINE HEPATITIS IN FREE-RANGING RED FOXES (*VULPES VULPES*)

A. W. Philbey* and H. Thompson†

* Royal (Dick) School of Veterinary Studies, University of Edinburgh, Easter Bush, Edinburgh, Scotland, United Kingdom and † Mill House, Camis Eskan, Helensburgh, Scotland, United Kingdom

adrian.philbey@ed.ac.uk

Introduction: Infectious canine hepatitis (ICH), caused by canine adenovirus type 1 (CAV-1), has been reported mostly in dogs, farmed foxes and other captive carnivores. Initially called “epizootic fox encephalitis”, ICH was first identified in domesticated (“tamed”) silver foxes, a colour variant of the red fox (*Vulpes vulpes*). ICH was diagnosed in a free-ranging grey fox (*Urocyon cinereoargenteus*) in Georgia, USA, in 2005. There is serological evidence of exposure to CAV-1 in free-ranging red foxes in North America, Germany, Australia and the UK, as well as in free-ranging grey foxes in North America.

Materials and Methods: Sick free-ranging red foxes were presented to wildlife rehabilitation centres in England, where they died naturally. Tissues were submitted for virus isolation and histopathology.

Results: ICH was diagnosed in three red foxes found depressed or collapsed in the wild. Grossly, the foxes were jaundiced and had congested livers with accentuation of the lobular pattern. Histologically, there was generalised necrosis and dissociation of hepatocytes, with intranuclear inclusion bodies in hepatocytes, renal glomeruli, proximal convoluted renal tubular epithelial cells and vascular endothelial cells. CAV-1 was isolated from all three foxes.

Conclusions: Free-ranging red foxes are considered to be a reservoir of CAV-1 in the United Kingdom and are a potential source of infection for domestic dogs.

Oral Presentations

Session H: Inflammatory, Skin & Wildlife Disease

IDIOPATHIC SEVERE EOSINOPHILIC PNEUMONIA AND VASCULITIS IN 11 HORSES

G.E. Magi, M.C. Ruscello, G. Rossi and G. Renzoni

School of Veterinary Medical Sciences, University of Camerino, Italy

gianenrico.magi@unicam.it

Introduction: Various eosinophilic lesions has been described in horses. Multisystemic eosinophilic epitheliotropic disease (MEED) characterized by eosinophilic granulomas in various organs represents the most diffuse manifestation. In the present study we describe the gross and microscopic lesions of idiopathic eosinophilic pneumonia and vasculitis in 11 horses without systemic involvement.

Materials and Methods: During a 2-year period (2010-2011), lungs from 88 horses with gross signs of pulmonary disease were collected at a slaughterhouse. Lung sections were stained with hematoxylin and eosin, Giemsa and periodic acid Schiff.

Results: In 11 horses lungs were enlarged, pale pink, poorly collapsed with multifocal to coalescing, white-reddish, 0.4-4.0-cm-diameter, nodules, distributed throughout the parenchyma. Histologically the lesions ranged from severe eosinophilic bronchointerstitial pneumonia to severe eosinophilic lobular bronchopneumonia associated with eosinophilic necrotizing vasculitis affecting small to medium-size vessels. Mild interstitial fibrosis was also present. The other part of parenchyma appeared emphysematous. There was no histologic evidence of parasites within the lesion of any of these horses.

Conclusions: Eosinophilic pneumonia and vasculitis without intralesional parasites are rarely described in horses. Histologic findings do not resemble the typical eosinophilic granulomas observed in lungs of horses with MEED but are similar to pathologic lung findings of idiopathic chronic eosinophilic pneumonia of man and of Churg-Strauss syndrome of man.

Oral Presentations

Session H: Inflammatory, Skin & Wildlife Disease

TRANSVERSE SECTIONING FOR EVALUATION OF SKIN BIOPSY SPECIMENS FROM ALOPECIC DOGS

R. Bond*, A. Hendricks*, J. Patterson-Kane#, K. Stevens* and H. Brooks*.

*Royal Veterinary College, Hatfield, UK and #School of Veterinary Medicine, Glasgow, U.K.

rbond@rvc.ac.uk

Introduction: Transverse sectioning of skin biopsy specimens has revolutionised assessment of human alopecia by demonstration of every hair in each specimen, allowing quantitative evaluation of follicular activity. Since only vertical sectioning is performed routinely in veterinary laboratories, we aimed to determine whether transverse sectioning was a valuable additional technique in assessment of canine alopecia.

Materials and Methods: Paired vertical and transverse sections of skin biopsy specimens from 31 alopecic dogs were examined independently in triplicate in random order and blinded to previous diagnosis using standard check-list proforma. Assessment of key features (follicular activity [anagen/telogen], infundibular hyperkeratosis, sebaceous gland abnormalities, pigment clumping, dermal inflammation) by each sectioning method were compared using the kappa statistic.

Results: In 19 cases, significant differences were evident between the two methods, including a greater proportion of follicles observed in telogen ($n=8$), specifically secondary follicles ($n=5$), in transverse sections. Agreement between the two sectioning planes was moderate for infundibular hyperkeratosis ($\kappa = 0.5210$) and dermal inflammation (0.4351), fair for sebaceous gland abnormalities (0.3966) and pigment clumping (0.2197), but only slight for follicular activity (0.1041).

Conclusion: These data indicate that assessment of canine hair follicle abnormalities (especially anagen / telogen ratios, numbers of hair shafts per unit) is enhanced by transverse sectioning, as previously recognised in studies in humans.

Supported by BSAVA Petsavers



Oral Presentations

Session H: Inflammatory, Skin & Wildlife Disease

LESSER LOOSESTRIFE (*LYTHRUM HYSSOPIFOLIA*) POISONING IN SHEEP AND CATTLE

A. W. Philbey* and A.G. Morton†

* Royal (Dick) School of Veterinary Studies, University of Edinburgh, Easter Bush, Edinburgh, Scotland, United Kingdom and † Hume Livestock Health and Pest Authority, Wagga Wagga, New South Wales, Australia

adrian.philbey@ed.ac.uk

Introduction: Lesser loosestrife (*Lythrum hyssopifolia*) is an annual forb growing on poorly drained or flood-prone areas. It is native to Europe and has been introduced to Australia and North America. In the United Kingdom, the largest population is around Swan Lake in Gloucestershire. Lesser loosestrife is relatively unpalatable, but may be eaten by sheep and cattle if it is the only available green feed.

Materials and Methods: Outbreaks of mortality in sheep and cattle in south western New South Wales, Australia, were investigated. Samples of blood were collected for biochemistry. Tissues were collected at postmortem examination for histopathology. Plants were identified.

Results: Affected sheep and cattle were listless and inappetent. Mortalities ranged from 1% to >50%. Concentrations of urea and creatinine in serum were increased. Grossly, the kidneys were pale and swollen. In sheep, the liver sometimes had an accentuated lobular pattern. Histologically, there was nephrosis in sheep and cattle. Hepatocellular necrosis was evident in some sheep. Lesser loosestrife was the predominant green feed and had been grazed.

Conclusions: Lesser loosestrife poisoning has been reported in sheep and cattle in New South Wales and Victoria, Australia. The plant appears to be nephrotoxic for sheep and cattle, and hepatotoxic for sheep. The toxic principle is unknown.

Oral Presentations

Session H: Inflammatory, Skin & Wildlife Disease

HEALTH STATUS OF BROWN HARES (*LEPUS EUROPAEUS*) IN EASTERN AUSTRIA

A. Posautz, A. Kübber-Heiss, F. Knauer, ZS. Kelemen, F. Suchentrunk, and C. Walzer

Research Institute of Wildlife Ecology, University of Veterinary Medicine Vienna, Austria

annika.posautz@fiwi.at

Introduction: The brown hare (*Lepus europaeus*) population has been declining throughout its range in the last decades. As the brown hare is on the national red list in Austria, a thorough health screening project was conducted in eastern Austria in the years 2010 and 2011.

Materials and Methods: A total of 188 hares underwent a thorough pathologic screening. Parasitologic testing was done in all hares, bacteriology and virology only upon indication. As Tularemia is endemic in eastern Austria, all hares were screened for *Francisella tularensis*. Serologic screening for *Treponema sp.* was implemented in 119 animals, for European Brown Hare Syndrome (EBHS) in 49.

Results: Parasites found were *Trichostrongylus sp.*, *Trichuris sp.* and *Eimeria sp.*. The infestation rate varied strongly. 3% were culture positive for Tularemia. 93% were seropositive for EBHS. 58% for *Treponema*.

Conclusions: The overall health status of the East-Austrian brown hare population is rather good. The occurrence of tularemia is important regarding human health, but does not seem to play a major role in the general health status. The high sero-prevalence for *Treponema* and EBHS shows that the animals have contact to these entities, but seem to cope rather well. For EBHS this might in part be due to a less virulent strain. Generally it can be stated, that the decline cannot be blamed on diseases circling in this population.

Oral Presentations

Session H: Inflammatory, Skin & Wildlife Disease

DETECTION OF HEPATITIS E VIRUS (HEV) IN FREE RANGING WILD BOARS (*SUS SCROFA*) IN ITALY

R. Verin^{*}, R. Nardini^{*}, M. Mazzei^{*}, P. Varuzza^{*}, A. De Martino[†] and A. Poli^{*}

^{*} Department of Veterinary Sciences, University of Pisa, Italy and [†] Pathology Core, Institute for Health Sciences of Aragon, Zaragoza, Spain

rverin@vet.unipi.it

Introduction: Hepatitis E virus (HEV) is highly prevalent in farmed pigs worldwide and its zoonotic role is known. HEV has also been documented in several domestic and wild species, including the wild boar (*Sus scrofa*), which may act as a reservoir.

Materials and Methods: Sixty-four blood, faecal and liver samples of hunted wild boars (classified by age and gender) were included in the study. Indirect ELISA and PCR were performed on all sera and faeces respectively. Histopathology and immunohistochemistry to HEV were performed on livers of PCR positive subjects. Immunohistochemistry against CD3 and CD79a was performed on liver samples to characterise lymphocytic infiltrates.

Results: Thirty-three (51%) sera resulted positive for HEV antibodies while six (9%) faecal samples showed virological positivity with an expected nested-PCR product of 347bp. A higher prevalence was found in juveniles with both techniques with no differences between genders. Histological lesions were characterised by a very mild multifocal and periportal lympho-plasmacytic infiltration of mainly CD3+ lymphocytes. All six liver samples showed immunohistochemical cytoplasmic positivity for HEV around inflammatory foci.

Conclusions: HEV infection is endemic in Italian wild boar population and further investigation is needed in this species to better characterise its role in the epidemiology.

Poster Abstracts

Degenerative Disease

PL-1

ADVERSE REACTION TO PRESUMED INTRA-ARTERIAL CEFTIOFUR SUSPENSION INJECTION IN DAIRY CATTLE

J. Wessels*, M. Wessels*, D.F. Twomey[†] and J. Roberts[‡]

*AHVLA Preston/[†]Starcross, UK, and [‡]Zoetis UK Ltd, Tadworth, UK

mark.wessels@ahvla.gsi.gov.uk

Introduction: Inadvertent intra-arterial injection of medicines can lead to a wide range of adverse reactions. We describe the pathological findings following inadvertent intra-arterial injection of ceftiofur suspension, a cephalosporin type antibiotic drug, in dairy cows.

Materials and Methods: Necropsy was performed on six cows that had received an injection of ceftiofur via the subcutaneous route at the ear base, as indicated in the manufacturer's data sheet. The clinical signs reported included recumbency, hypersalivation, fitting, blindness, unresponsive behaviour and death.

Results: Gross findings included oedema and haemorrhage at the injection site and in brainstem meninges, and oily white material in tissues caudal to the ear base and within meningeal vessels. Multifocal areas of haemorrhage/malacia were identified in the cerebral cortex and cerebellum. In three of the four cases in which brain histopathology was undertaken meningeal and neuroparenchymal haemorrhage, thrombosis, perivascular oedema, rarefaction, necrosis, and astrocyte swelling were seen in the medulla, cerebellar peduncles, pons, midbrain/thalamus, cerebrum and cerebellum. Histological changes seen at the injection site included haemorrhage, myocyte necrosis, oedema and neutrophil infiltrate.

Conclusion: Inadvertent administration into the caudal auricular artery and subsequent retrograde movement into the internal carotid and/or maxillary artery is thought to have led to distribution within the central nervous system vasculature. Vascular occlusion, vasoconstriction, cytotoxicity and breakdown of the blood-brain barrier are all thought to be implicated in the pathogenesis.

Poster Abstracts

Degenerative Disease

PP-2

SPONTANEOUS ISLET AMYLOID POLYPEPTIDE AMYLOIDOSIS (AIAPP) IN TWO PREVOST'S SQUIRRELS (*CALLOSCIURUS PREVOSTI* DESMAREST, 1822)

C. Schulze^{*}, J. Kämmerling[†] and R. P. Linke[‡]

^{*} Berlin-Brandenburg State Laboratory, Gerhard-Neumann-Str. 2, D-15236 Frankfurt (Oder), Germany, [†] Zoo Cottbus, Kiebuscher Str. 5, D-03042 Cottbus, Germany and [‡] Reference Center for Amyloid Diseases, amYmed, Am Klopferspitz 19, D-82152 Martinsried, Germany

christoph.schulze@landeslabor-bbb.de

Introduction: Islet amyloidosis is known from humans, non-human primates, cats and raccoons. Islet amyloid is derived from the precursor protein islet amyloid polypeptide (IAPP) normally produced by islet β -cells and cosecreted with insulin. Since rodent IAPP is considered to be non-amyloidogenic, spontaneous AIAPP has never been reported before.

Materials and Methods: Necropsy was performed on two Prevost's squirrels, kept for 4.5 years as a breeding pair in a zoological garden under standard housing and feeding conditions. Formalin-fixed and paraffin-embedded tissues were investigated by HE- and Congo red staining, and immunohistochemistry using a panel of antibodies against different human amyloid-proteins including IAPP cross-reacting with their animal counterparts.

Results: Except for dehydration, no other macroscopical findings were present. Varying degrees of amyloid deposits from mild - multifocal to severe - diffuse leading to depletion of islets cells were detected in the interstitium of the pancreatic islets in both animals. By immunohistochemistry, the islet amyloid was identified as IAPP.

Conclusions: This is the first report of spontaneous AIAPP in rodents. Future amino acid sequence analysis could reveal the features on which the amyloidogenicity of IAPP in Prevost's squirrels are based.

Poster Abstracts

Degenerative Disease

PP-3

COMPARATIVE ASSESSMENT OF *PORTULACA OLERACEA* (PO) EXTRACT, OMEGA3 AND VITAMIN E + SELENIUM) ON SERUM LEVEL OF GLUCOSE AND INSULIN AND HISTOPATHOLOGY OF PANCREAS IN STREPTOZOTOCIN (STZ) INDUCED DIABETIC RATS

F.Sasani,* M.Alyari Gavaheer, ** D.Babazadeh, J.Ashrafi Helan*****

**Department of Veterinary Pathology, Faculty of Veterinary Medicine, Tehran University, Iran*

***Private Veterinarian*

**** Department of Veterinary Pathology, Faculty of Veterinary Medicine, Tabriz University, Iran*

fsasani@ut.ac.ir

Introduction: The extract of the *Portulaca oleracea* (PO) plant has antidiabetic, antioxidant, antiseptic, diuretic and antipyretic compounds.

Materials and Methods: PO plant extract, omega3 or selenium and vitamin E were orally administered to 3 groups of STZ induced diabetic rats (each group with 5 rats, for 4 weeks) and 3 rats as control groups. The serum insulin and glucose levels, the diameter of the islets of Langerhans, and the number of beta and alpha cells in all groups were checked.

Results: In the PO plant group, the beta cell regeneration was significantly more than in the other 2 groups. Significant regeneration of the islets of Langerhans with more reduction of inflammatory cells and so increasing insulin level in 28th day (15 lu/ml) by comparison to the selenium and vitamin E group (14 lu/ml) and omega 3 group (13 lu/ml) were observed. In the omega3 treated group, the diameter of the islets of Langerhans was more regenerative and serum level of glucose was more reduced in comparison to other groups but the serum level of insulin in the PO plant group was more than other groups.

Conclusion: The PO plant extract was more effective than omega3 or selenium and vitamin E in treatment of STZ induced diabetic rats.



Poster Abstracts

Degenerative Disease

PP-4

EOSINOPHILIC MYENTERIC GANGLIONITIS IN AN 11-YEAR-OLD ARABIAN GELDING

C. de Vries§, L. LefèreØ, P. DeprezØ, K. Chiers§, R. Ducatelle§

§Department of Pathology, Bacteriology and Avian Diseases ØDepartment of Large Animal Internal Medicine
College of Veterinary Medicine, Ghent University, Belgium

cyn.devries@gmail.com

Introduction: Chronic intestinal pseudo-obstruction due to intestinal ganglionitis is a rare disease in animals and is also uncommon in humans. The 4 reported cases in horses, 1 case in a dog, and 1 case in a cow all had lymphocytic infiltrates within myenteric ganglia, while in humans cases with eosinophilic infiltrates have been reported. To our knowledge, this is the first case of eosinophilic myenteric ganglionitis (EMG) in an animal.

Materials and Methods: A 12-year-old Arabian gelding was presented with an acute onset of colic. Based on ultrasonographic examination and abdominocentesis, ileum impaction was diagnosed. The impaction was resolved through ventral midline celiotomy. Surgical biopsies were taken and routinely processed for histopathology. The horse was euthanized due to progressive post-operative intermittent intestinal pseudo-obstruction.

Results: Within Auerbach's plexuses there was mild vacuolation of neurons with moderate infiltration of eosinophils. There was no eosinophilic infiltrate within submucosal plexuses. Neurons within both Auerbach's and submucosal plexuses, as well as in trigeminal and stellate ganglia were positively labeled for synaptophysin.

Conclusion: EMG should be considered as a rare cause of intermittent intestinal obstruction in horses. The possible relation with Equine Grass Sickness is unclear. Although the etiology is unknown, an allergic, autoimmune or infectious etiology could be suspected based on the eosinophilic infiltrate.

Poster Abstracts

Degenerative Disease

PL-5

NEMALINE RODS IN TWO YOUNG BORDER COLLIES WITH MYOPATHY

M. Dettwiler¹, S. Klausmann¹, K. Beckmann², T. Sydler¹

Institute of Veterinary Pathology¹, Small Animal Neurology², Vetsuisse-Faculty, Zurich University, Switzerland

m.dettwiler@access.uzh.ch

Introduction: Nemaline rods have been described in association with congenital and acquired myopathies in humans. Few cases have been reported in cats and dogs. The visibility of nemaline rods has been assumed exclusively to fresh frozen muscle specimens. Here, we report the histological presence of nemaline rods in two Border Collie littermates in formalin-fixed and paraffin-embedded (FFPE) muscle samples.

Materials and Methods: Two 10 week-old Border Collie littermates presented with progressive gait disorder, muscle stiffness and exercise intolerance. They were euthanized due to suspicion of inherited myopathy and submitted for necropsy. HE-sections and special stains (PAS, PTAH, Gomori-Trichrome) were performed from FFPE samples of skeletal muscles, diaphragm and heart. Transmission electron microscopy was carried out on FFPE skeletal muscle specimens.

Results: In both dogs no gross lesions were present. In histology, skeletal muscles including diaphragm showed marked variability in myofiber diameter. Numerous myocytes showed loss of cross striation and multiple hypereosinophilic rod-shaped cytoplasmic inclusions in HE. Cardiomyocytes were not affected. Visibility of the rods was highly improved with PTAH and Gomori-Trichrome stain. The rods did not react with PAS. Electron microscopy showed degenerating myofibers with electron dense, 0,5x1µm large rods associated with Z-lines.

Conclusion: The findings strongly point to a congenital nemaline rod myopathy. Nemaline rods can also be visible in routinely processed sections of FFPE muscle samples.

Poster Abstracts

Degenerative Disease

PL-6

FIBRODYSPLASIA OSSIFICANS PROGRESSIVA IN A CAT

A. Klang¹, S. Kneissl², R. Glaenzel³ and A. Fuchs-Baumgartinger¹

¹ Institute of Pathology and Forensic Veterinary Medicine and ² Diagnostic Imaging, University of Veterinary Medicine Vienna, Austria and ³ Veterinary Clinic Großjedlersdorf, Vienna, Austria

andrea.klang@vetmeduni.ac.at

Introduction: Fibrodysplasia ossificans progressiva, a rare disorder of unknown etiology, is characterized by fibrosis and heterotopic bone formation in connective tissues. Just nine feline cases have been reported so far.

Materials and Methods: A 1-year-old female cat was presented with gait abnormalities such as short strides and stiffness of all limbs. Radiography, post mortem computed tomography (CT), and histopathological examination were performed.

Results: Orthopedic examination identified marked diffuse hardening and reduced range of motion in shoulder, elbow, hip and stifle joints. Radiography demonstrated multiple bilaterally symmetrical distributed calcified lesions defined to the connective tissue of the musculoskeletal system of shoulder girdle, cervical and thoracic vertebral column, aponeuroses and muscle fasciae of the axial skeleton and upper extremities, which revealed characteristics of bone in CT. Histopathological examinations showed proliferations of cell-rich, vascularized, collagenous tissue with foci of chondroid and osseous tissue, nodular perivascular localized aggregations of lymphocytes and mild infiltrations by mastocytes.

Conclusion: This is the first feline case describing fibrodysplasia ossificans progressiva in Europe. Molecular genetic examinations should be attempted to determine possible mutations in the bone morphogenetic pathway, similar to human patients. For better understanding of the pathophysiology of this painful, disabling disorder, and for development of new treatments, cats might serve as useful natural animal model.

Poster Abstracts

Degenerative Disease

PP-7

HISTOCHEMICAL AND IMMUNOHISTOCHEMICAL ANALYSIS OF HERNIATED DISC TISSUE SURGICALLY REMOVED FROM DOGS.

G. Beha, L. Pisoni, C. Bombardi, G. Avallone, G. Sarli, S. Del Magno, F. Cinti, L. Mandrioli, G. Gandini, C. Benazzi

Department of Veterinary Medical Sciences, University of Bologna, Italy

germana.beha2@unibo.it

Introduction: Herniation of intervertebral discs is a common disease in dogs that usually necessitates surgery. The aim of this study was to apply a modified histological grade of herniated disc material (HDM) to surgical samples.

Materials and Methods: Surgically sampled, HDM collected from 29 dogs were processed for routine histology, histochemistry (Gruber), and immunohistochemistry (Factor VIIIra). Follow-up minimum length was 3 months. Inflammation was added as a parameter in the grading system.

Results: All cases submitted contained nucleus pulposus, while annulus fibrosus was inconsistently available. Presence of inflammatory cells was associated with fibrosis, mineralization and neo-angiogenesis. The amount of proteoglycans (stained blue with Gruber) of the nucleus pulposus decreased proportionally with the increase of chondrocyte (stained red) proliferation. Most of the samples were scored as grade 3 in a range from 1 to 5.

Conclusion: The variability of histological material, sampled *in vivo*, and usually consisting only in the nucleus pulposus, suggests to separate the scoring of the annulus fibrosus from that of the nucleus pulposus. The association between proteoglycan reduction and chondrocytes indicates the degree of degeneration. Finally, these data suggest that the applied histochemical staining and the modified scoring with the addition of the inflammatory parameter are appropriate to evaluate the degree of degeneration of disc material.

Poster Abstracts

Degenerative Disease

PP-8

CEREBELLAR ABIOTROPHY IN TWO RELATED LION-TAILED MACAQUES (*MACACA SILENUS*)

A.J. Malbon*, E. Ricci*, S. Unwin[§] and J. Chantrey*

*Veterinary Pathology, School of Veterinary Science, University of Liverpool, UK and [§]Chester Zoo, Cheshire, UK

a.malbon@liverpool.ac.uk

Introduction: Cerebellar abiotrophy is a degenerative condition characterized by either early or late onset of severe neurological deficits caused by the marked depletion of Purkinje cells and granule cell neurons of the cerebellar cortex. The condition has been reported in numerous species with a proposed genetic basis of transmission. Here we present the anatomopathological investigation of two closely related lion-tailed macaques. Both cases, a 9 month old male and a 4 month old female, shared a long history of progressively worsening ataxia, incoordination and delayed body growth.

Materials and Methods: Following post-mortem examinations, full sets of tissues were submitted for histopathological examination by routine H&E staining. On selected serial cerebellar sections, special stains and immunohistochemistry were performed.

Results: Within the cerebellum, there was a moderate shrinkage of the rostromedial folia; correlating with a diffuse and severe loss of Purkinje and granule cells in association with severe atrophy of the cerebellar cortex, accumulation of CSF within the subarachnoid space, reduction of myelinated fibres within the cerebellar folia and increased prominence of Bergmann glia.

Conclusion: Based on the characteristic findings, diagnoses of cerebellar abiotrophy were made. The relatedness of the two cases strongly supports an inherited mode of transmission. To the authors' knowledge, this is the first report of cerebellar abiotrophy in a macaque species.

Poster Abstracts

Degenerative Disease

PP-9

AXONAL INJURY AND DYSBALANCE OF GROWTH-PROMOTING AND REGENERATION-INHIBITORY AXONAL MOLECULES IN CANINE SPINAL CORD INJURY

C. Lempp*, I. Spitzbarth*, F. Seehusen*, V. M. Stein†, A. Tipold† and W. Baumgärtner*

**Department of Pathology, University of Veterinary Medicine, Hannover, Germany*

†Small Animal Clinic, University of Veterinary Medicine, Hannover, Germany

charlotte.lempp@tiho-hannover.de

Introduction: Spinal cord injury (SCI) due to intervertebral disk disease (IVDD) in dogs is regarded a suitable, spontaneously occurring animal model for human SCI research. However, mechanisms of axonal injury and impairment of axonal transport mechanisms, especially concerning processes of inhibition and promotion of axonal regeneration, respectively, are poorly understood.

Materials and Methods: Formalin-fixed and paraffin-embedded sections of healthy and injured spinal cords from dogs with acute and subacute IVDD have been investigated morphologically and immunohistochemically using antibodies against alpha-acetylated tubulin, β -tubulinIII, dynein, kinesin and tau for quantitative evaluation of damage on structures involved in axonal transport mechanisms. Furthermore, antibodies against EPO, EPO-R, HIF, LINGO-1, and Nogo-A, were used to detect axonal outgrowth and its inhibition.

Results: Severe changes in axonal transport mechanisms with accumulation of motor proteins especially in swollen axons could be detected. Significant up-regulation of LINGO, EPO, EPO-R and HIF was evident. No changes were detectable for Nogo-A.

Conclusions: Though canine SCI is characterized by a marked up-regulation of molecules beneficial for axonal outgrowth, a dominating impairment of axonal transport mechanisms may potentially inhibit effective axonal regeneration in SCI.

Poster Abstracts

Infectious Disease

PP-10

MARKED INDUCTION OF IL-8 AND IL-12 IN NEONATAL OVINE LUNG FOLLOWING EXPERIMENTAL INOCULATION OF BOVINE RESPIRATORY SYNCYTIAL VIRUS

E. Redondo, A. Gázquez, A. García, A. Franco, J. Masot

Animal Medicine Department, Veterinary Faculty, University of Extremadura, Cáceres, Spain

jahis@unex.es

Introduction: This study sought to determine the immunohistochemical expression of Interleukin-1-Beta (IL-1 β), Tumor Necrosis Factor-alpha (TNF α), Interferon Gamma (INF γ), IL-4, IL-6, IL-8, IL-10 and IL-12 and to measure the levels of these cytokines in lung from lambs experimentally infected with Bovine Respiratory Syncytial Virus (BRSV).

Materials and Methods: Lambs ($n=15$) were inoculated at 2 days of age with 20 mL of viral inoculum (1.26×10^6 TCID₅₀ per mL) or sterile media ($n=15$). Rectal temperature, pulse and respiratory rates were monitored daily. Lambs were necropsied at 1, 3, 5, 7 and 15 days post inoculation. ExtrAvidin Peroxidase Staining and ELISAs were used to detect BRSV-antigen, IL-1 β , IL-4, TNF- α , INF γ , IL-6, IL-8, IL-10 and IL-12 on paraffin sections and in lung extracts, respectively.

Results: Inflammatory cytokines IL-8 and IL-12 were expressed in greater quantities than IL-1 β , TNF α , INF γ and IL-6 in the lung of experimentally BRSV-infected lambs.

Conclusions: These observations, together with the results of ELISA, led to consideration of important implications for therapeutic strategies based on the modulation of inflammatory cytokines in the treatment of this illness. The pharmaceutical agents that inhibit synthesis of IL-8 and IL-12 or antagonise its biological effects, could be more efficient in the treatment of BRSV infection in lambs than those that are directed only at other inflammatory cytokines.

Poster Abstracts

Infectious Disease

PP-11

HISTOPATHOLOGICAL AND IMMUNOHISTOCHEMICAL FINDINGS IN THE LUNGS OF PIGS EXPERIMENTALLY INFECTED WITH *MYCOPLASMA HYOPNEUMONIAE*

E. Redondo, A. Gázquez, A. García, A. Franco, J. Masot

Animal Medicine Department, Veterinary Faculty, University of Extremadura, Cáceres, Spain

jahis@unex.es

Introduction: The objective of this investigation was to describe the histological changes occurring at different post-infection times in porcine lungs infected with *M. hyopneumoniae* (*Mh*), so as to establish a link between the immunohistochemical expression of cytokines (IL-1 α , IL-1 β , IL-2, IL-6, IL-8, TNF- α - INF- δ) and lymphoid markers (CD3⁺, CD4⁺, CD8⁺, muramidase, CD16⁺, CD19⁺, IgG⁺, IgA⁺) with the development of pulmonary lesions.

Materials and Methods: Pigs were infected intranasally with *Mh* and necropsied at intervals ranging from 7 to 35 days post-infection (dpi).

Results: Histopathological changes consisted of exudates in airways and alveolar lumina, peribronchial and peribronchiolar lymphoid hyperplasia, and enlargement of alveolar septa. These changes were particularly marked from 7 to 28 dpi, coinciding with significant increases in the expression, detected immunohistochemically, of cytokines (IL-1a, IL-1b, IL-8, TNF-a and INF-g) and lymphoid markers (CD4⁺, CD8⁺, muramidase, IgG⁺, IgA⁺). Both the lesions and immunohistochemical signals declined in intensity beyond 35 days.

Conclusions: This study confirmed and extended previous findings on the distribution of *Mh* in infected porcine lungs and on the development of a cellular and humoral immune response. The increase in immunohistochemical expression of cytokines and lymphoid markers coincided with the exacerbation of histopathological lesions. These results provide valuable insights into the local immune response of the pigs' respiratory system to *Mh* infection.

Poster Abstracts

Infectious Disease

PP-12

THE RELATIONSHIP BETWEEN MICROSCOPIC LESIONS AND DEFFERENT TYPES OF CLOSTRIDIUM PERFRINGENS AND THEIR RELATED TOXINS (BY SANDWICH ELISA) IN CATTLE

F.Sasani*, H.Marzban*, J.Javanbakht*, F.Moosakhani**, M.Imanparast**

*Department of Veterinary pathology, Faculty of Veterinary Medicine, Tehran University, Iran

**Department of Veterinary Microbiology, Faculty of Veterinary Medicine, Islamic Azad University, Karaj Branch, Karaj, Iran

fsasani@ut.ac.ir

Introduction: One of the most important causes of Enterotoxaemia in domestic animals is *Clostridium perfringens*.

Materials and Methods: 30 cattle and calves with enterotoxemia were cheked for type of clostridial infection, toxin types and lesions in selected organs.

Results: *C.perfringens* type A (56.66%), type D (26.66%) and type B (16.66%) were the most abundant bacteria in intestinal samples of 30 cattle and calves with enterotoxaemia. The incidence of α , β and ϵ toxins in extracted intestinal contents, by Sandwich ELISA method, were determined as 89/98%, 19/99% and 33.33% respectively. Histopathologic examination of different organs from 12 cattle and calves with enterotoxaemia and *C.perfringens* infection revealed the following changes: heart: Sarcocystosis (30%), lymphocytic endocarditis (10%), pericarditis (10%) and cardiomyocyte hypertrophy (20%); liver: hepatitis (27%), coagulative necrosis (36%), hemorrhage (19%), severe hepatic fibrosis (9%) and hepatic abscess (9%); intestine: necrohemorrhagic enteritis (40%), lymphoplasmacytic enteritis (50%), necrotic and suppurative subserosal Inflammation (10%), congestion (10%), edema (10%) and shortening and fusion of villi (10%); lung: congestion (36%), hemorrhage (9%), edema (27%), atelectasis (9%), emphysema (9%), embolic pneumonia (9%), purulent bronchopneumonia (18%), fibrinous pneumonia (45%), cuffing pneumonia (18%), Interlobular fibrosis (9%) and pulmonary abscess (9%); kidney: congestion (12.5%), acute tubular necrosis (25%), glomerular atrophy (12.5%), interstitial nephritis (50%) and hyaline droplets (12.5%).

Conclusion: The results of this research were compatible with previously published data. Although some of the lesions were triggered by *C.perfringens*, some may be caused by other pathogens which were not investigated in this research.



Poster Abstracts

Infectious Disease

PP-13

FIELD VOLES AS POTENTIAL TULARAEMIA RESERVOIR

H. Rossow*, K. Forbes‡, O. Vapalahti* and A Kipar*,‡

*Veterinary Biosciences (HR, OV, AK) and Finnish Centre for Laboratory Animal Pathology (AK),
Faculty of Veterinary Medicine, University of Helsinki, Finland

‡Suonenjoki Unit, Finnish Forest Research Institute, Suonenjoki, Finland

‡Veterinary Pathology, School of Veterinary Science and Department of Infection Biology, Institute of
Global Health, University of Liverpool, UK

akipar@liverpool.ac.uk

Introduction: Tularaemia caused by *Francisella tularensis* ssp. *holarctica* is endemic in Northern Europe. Many animal and insect vectors are known, but the natural reservoir is unknown. Tularaemia outbreaks in humans might be linked to peak densities of rodent populations, but the mode of bacterial maintenance in nature is still unclear. We therefore studied the susceptibility and response of voles, the dominant small mammals in Finland, to *F. tularensis*.

Materials and Methods: Field voles (*Microtus agrestis*) were intranasally (i.n.) and subcutaneously (s.c.) infected with 120 or 1200 CFU of *F. tularensis* ssp. *holarctica* and necropsied at 5-9 days post infection. For comparison, PCR-positive wild voles, trapped as part of a screening project, were examined. All animals were histologically assessed.

Results: All but one experimentally infected vole exhibited massive bacteraemia and pathological changes typical for tularaemia in other species, such as extensive splenic necrosis. Two i.n. infected voles also showed severe necrotising and granulomatous pneumonia.

Conclusions: Field voles readily develop tularaemia independent of the route of infection. The severity of the lesions in the naturally infected animals challenges the hypothesis that field voles are reservoirs for the bacterium.



Poster Abstracts

Infectious Disease

PP-14

MUCIN EXPRESSION, IEL, AND CYTOKINES IN THE CAECUM OF BROILERS AFTER ADMINISTRATION OF EF55 AND *S. ENTERITIDIS*

M. Levkut Jr., V. Revajová, M. Levkutová, M. Kolesárová, R. Herich, Z. Ševčíková, M. Levkut

University of Veterinary Medicine and Pharmacy, Komenského 73, 041 81 Košice, Slovak Republic

levkut@uvm.sk

Introduction: The local immune response in the gastrointestinal tract has been scarcely studied in relation to competitive exclusion of probiotic strain *E. faecium* EF55 and *S. enterica* serovar Enteritidis 147. To find a certain relation to the quantity of cells and level of cytokines, we chose to study intraepithelial lymphocytes, chicken intestinal mucin gene expression (MUC), as well as proinflammatory cytokines IL-15 and IL-17.

Materials and Methods: One day-old chicks (220) were randomly divided into 4 groups: the probiotic group (10^9 CFU), *Salmonella*+probiotic group, the *Salmonella* group (10^8 CFU in 0.2 ml PBS), and the controls.

Results: EF55 increased higher number of peripheral blood heterophils and the number of IgA+ cells in the cecal intestinal mucosa at the 7. d.p.i. EF55 decreased expression of MUC in the caecum in salmonellae infected group and had a tendency to increase expression of IL-15 and IL-17 at 3. d.p.i.

Conclusions: The results demonstrated beneficial effect of EF55 on the expression of MUC and production of IgA+ cells in the late phase of infection. Furthermore, the results suggest a relationship between expression of cytokines, expression of MUC and IgA+ cells.

Acknowledgements: Research and Development Support Agency, Slovakia, Grant No.APVV-0302-11, VEGA - Grant No. 1/0886/11, No. 1/0313/12, and No.1/0885/11.

Poster Abstracts

Infectious Disease

PP-15

EOSINOPHILIC ENCEPHALOMYELITIS BY NEMATODE INFECTION IN HORSES

G. H. Woo^{*}, Y. H. Jean[†], I. S. Roh[†] and E. J. Bak[‡]

^{*}Semyung University, Jecheon, [†]Animal and Plant Quarantine Agency, Anyang, [‡]Oral Cancer Research Institute, Yonsei University College of Dentistry, Seoul, Republic of Korea

ghwoo@naver.com

Introduction: Verminous encephalomyelitis is a neurologic disease in horses and caused by the migration of nematodes and fly larvae. Equine parasitic migratory infections occur sporadically in several major horse-breeding countries. However, this verminous encephalomyelitis in horses has not been reported in Korea. In this study, we therefore, describe eosinophilic encephalomyelitis caused by nematode in horses.

Materials and Methods: Four thoroughbred horses were submitted to the Animal and Plant Quarantine Agency (QIA) in Korea. At necropsy, various organs and tissues were fixed in 10% buffered formalin, embedded in paraffin, and sectioned at 4 μ m. The sections were then stained with hematoxylin and eosin (HE). Fresh tissues were collected for bacteriology, parasitology, virology and serology.

Results and Discussion: Grossly, dark red or gray appearance and foci were present in the central nervous system (CNS). Histopathologically, multifocal to coalescing eosinophilic necrotizing encephalomyelitis was observed in cerebrum, brain stem and spinal cord. Hemorrhage, granulomatous inflammation, and intact or degenerative nematodes were also seen. The nematodes had polymyarian coelomyarian musculature, smooth thin cuticle, and intestines lined by multinucleated cells with microvilli suggesting *Parelaphostrongylus tenuis*. No bacteria or viruses were isolated from the affected animals.

Conclusions: Based on above results, horses were infected with nematodes, presumably *Parelaphostrongylus tenuis*, resulting in eosinophilic encephalomyelitis.

Poster Abstracts Infectious Disease

PP-16

SITUATION OF RANAVIRUS IN JAPANESE NATIVE AMPHIBIANS

Yumi Une, Eiki Ri, Masaru Murakami

Azabu University, Kanagawa, Japan

une@azabu-u.ac.jp

Introduction: In 2008, we reported the first outbreak of ranaviral disease in Japan in wild populations of the American Bullfrog (*Lithobates catesbeianus*). The aim of this study is to reveal the present situation of Rana virus in Japanese native amphibians.

Materials and Methods: We collected and tested 1,117 Indian rice frogs (*Fejervarya kawamurai*) from 13 locations in 8 prefectures between May 2011 and October 2012. Capture frogs were euthanized, necropsied, and infection tested using kidney tissue and PCR methods using 3 set primers.

Results: Ranavirus was found in all 8 Japanese prefectures. Infection prevalence of ranavirus was 12.9% (152/1,177), with lower infection in 2011 (8.7%) compared to 2012 (16.5%). Infection prevalence differed among seasons in 2011 (0% in spring, 7.7% in summer, 17.8% in autumn) and in 2012 (7.7% in spring, 7.7% in summer, 36.6% in autumn), with prevalence greatest during autumn both years. We sequenced 495, 72 and 193 base pair regions of the MCP, and identified potentially four types of ranavirus (RCV-JP, HNV, FKV, and TFV) present in Indian rice frog populations, with prevalence differing among types (30.1%, 15%, 46.9% and 9%, respectively).

Conclusions: In conclusion, it appears ranavirus is distributed widely in Japan, with multiple variations of the virus circulating in amphibian communities. Given that the Indian rice frog is an invasive species with a rapidly expanding distribution that is a suitable host for ranavirus, their occurrence may contribute to the emergence of ranavirus in native amphibian communities in Japan.

Poster Abstracts

Infectious Disease

PP-17

TLR-2 SIGNALING IN THE BRAIN OF DOGS WITH VISCERAL LEISHMANIASIS: CORRELATION WITH PRO-INFLAMMATORY CYTOKINES

G.F. Machado*, G.D. Melo*, J.M. Silva*, F.G. Grano*, J.E.S. Silva*, A. Schweigert*

* São Paulo State University (UNESP), College of Veterinary Medicine, Laboratory of Applied Pathology (LAPAP), Araçatuba-SP, Brazil

giselem@fmva.unesp.br

Introduction: The central nervous system (CNS) undergoes inflammatory alterations during the peripheral infection caused by the protozoan *Leishmania chagasi* (= *L. infantum*), including lymphocyte infiltration, glial activation and presence of matrix metalloproteinase enzymes. Since Toll-like receptors (TLRs) mediate the production of pro-inflammatory cytokines, the aim of this study was to detect the gene expression of TLR-2, IL-1 β and TNF- α in the CNS of dogs with visceral leishmaniasis (VL).

Materials and Methods: Brain fragments of 15 dogs with VL and 4 uninfected dogs were collected in RNAlater, the RNA was extracted, and submitted to RT-qPCR to quantify the gene expression of TLR-2, IL-1 β and TNF- α , using specific primers and Taqman probes. G3PDH was used as a reference gene.

Results: TLR-2 tended to be up-regulated in the brain of the infected dogs (2.69-fold more; $P=0.0799$) along with the up-regulation of IL-1 β (6.36-fold more; $P<0.001$) and TNF- α (4.31-fold more; $P=0.001$).

Conclusion: *Leishmania* possesses a surface molecule named lipophosphoglycan (LPG) which has been recently described to activate NK cells through TLR-2. Within the brain, the activation of TLR-2 may be a trigger to increase the production of IL-1 β and TNF- α , the main cytokines related to blood-brain-barrier disruption, possibly explaining the inflammatory changes in the central nervous system during VL.

Poster Abstracts

Infectious Disease

PP-18

LYMPHOCYTE MARKERS CORRELATION IN TISSUE AND BLOOD IN VISNA/MAEDI EXPERIMENTALLY-INFECTED SHEEP

P. Pinczowski¹, M. Gimeno¹, L. Sanjosé², N. Insausti¹, A. Casanova¹, D. Pereboom¹, J. Badiola¹, B. Amorena², M. Pérez¹, R. Reina², L. Luján¹

1- University of Zaragoza, Spain

2- Institute of Agrobiotechnology, (UPNA-CSIC), Navarra, Spain

p.pinczowski@gmail.com

Introduction: Visna/maedi (VM) infection can cause chronic arthritis and/or encephalitis, with an inflammatory process dominated by lymphocytes. The expression of lymphocyte markers is useful to understand the pathogenesis of the disease. The aim of this work was to study the expression of lymphocyte markers involved in the evolution of VM in an experimental infection by using flow cytometry and immunohistochemistry.

Materials and Methods: Two previously isolated ovine VM strains either with marked articular (496) or nervous tropism (697) were used. Twenty lambs, negative by ELISA and PCR for VM, were distributed into two infected groups (8 animals each) and one control group (4 animals). Lambs were inoculated intratracheally with 10^6 TCID₅₀ either with the articular or the nervous strain. Blood was tested periodically by flow cytometry for the expression of CD4, CD8 and FOXP3. Two animals from each infected group and one control were killed at 210 dpi and studied by pathological means, including immunohistochemistry.

Results: VM lesions were only seen in the articular group. Increased expression of lymphocyte markers in joints was observed. Expression in blood did not reveal significant changes during the first 6 weeks of infection.

Conclusions: Lymphocyte markers in blood did not seem to correlate with articular changes at least during the first weeks of the experimental infection.



Poster Abstracts

Infectious Disease

PP-19

ZYGOMYCOTIC APPENDICITIS IN COMMERCIAL FATTENING RABBITS

G. De Zan^{*}, L. Bano^{*}, M. Vascellari[§], S. Pascoletti^{*}, L. Viel^{*} and F. Agnoletti^{*}

^{*}Istituto Zooprofilattico Sperimentale delle Venezie, Laboratorio di Treviso, Italy and [§]Istituto Zooprofilattico Sperimentale delle Venezie, Padova, Italy

lorelay29@libero.it

Introduction: "Enteritis complex" indicates a common multifactorial disease that causes economic loss in rabbit farming. Several conditions and infectious agents play a role in the development of this disease but few reports have investigated intestinal mycotic infections in adult rabbits. The aim of this study was to describe three cases of mycotic appendicitis in commercial rabbits.

Materials and Methods: From cases of appendicitis observed during necropsy and at slaughterhouse, three samples of cecum were collected for histopathology and two of these also for *Salmonella* spp. culture and mycological analysis. The fungal isolate obtained was identified by mass spectrometry.

Results: Macroscopically, multifocal, white, pinpoint foci of necrosis were observed on caecal appendix and occasionally on sacculus, serosa. Histologically, a multifocal, severe, pyogranulomatous and necrotizing inflammation effaced submucosal lymphoid tissue. In association occasional hyphae with non-dichotomous branching, non-parallel walls and bulbous swellings were evident. In one case greyish, rapidly growing, wooly colonies were observed on fungal culture. Direct smear of colonies showed large hyphae with few adventitious septa, pyriform sporangia and prominent apophysis. These morphologic features, together with mass spectrometry, identified the fungus as *Lichtheimia (Absidia) corymbifera*. *Salmonella* spp. culture resulted negative.

Conclusions: Based on these findings, zygomycotic appendicitis due to *Lichtheimia (Absidia) corymbifera* should be put in the differential diagnosis of necrotic appendicitis in rabbits.



Poster Abstracts

Infectious Disease

PP-20

CYTOKINE EXPRESSION AND PHENOTYPICAL CHANGES IN THE SPLEEN OF CANINE DISTEMPER VIRUS INFECTED DOGS

V. Qeska*, Y. Barthel*, M. Iseringhausen*, A. Tipold[‡], V.M. Stein[‡], W. Baumgärtner*, A. Beineke*

**Department of Pathology, and [‡]Department of Small Animal Medicine and Surgery, University of Veterinary Medicine Hannover, Germany*

andreas.beineke@tiho-hannover.de

Introduction: Canine distemper virus (CDV) causes immunosuppression and immune mediated demyelination in the central nervous system of dogs. The aim of the present study was to testify the hypothesis that depletion of peripheral lymphoid organs is associated with disturbed immunomodulation.

Materials and Methods: Lymphoid depletion of spleens of CDV infected dogs and control animals was evaluated semi-quantitatively by light microscopy and associated phenotypical changes have been characterized by immunohistochemistry using different leukocyte markers. In addition, cytokine expression analyses and virus quantification have been performed by real time PCR.

Results: CDV infection led to a loss of T cells (CD3) in the PALS and B cells (CD79α) in follicles of investigated dogs. Moreover, splenic depletion was associated with a profound decrease of Foxp3⁺ regulatory T cells and an increased mRNA expression of tumor necrosis factor, indicative of a pro-inflammatory microenvironment.

Conclusion: Impairment of regulatory mechanisms of the peripheral immune system represents a potential prerequisite for long lasting immune alterations and excessive neuroinflammation in CDV infected animals, as currently discussed for immune mediated myelin disorders, such as multiple sclerosis.

Poster Abstracts Infectious Disease

PP-21

A CASE OF INTRATESTICULAR TETRATHYRIDIOSIS IN A CAT (FIRST REPORT)

A.Gulcubuk¹ O.Erdogan¹ A.Kayar² A.Baran³ G.Ozturk¹ N.Aysul⁴ M.Saroglu⁵

¹Department of Pathology, ²Department of Internal Medicine, ³Department of Reproduction and artificial insemination, ⁵Department of Surgery, Faculty of Veterinary Medicine, University of Istanbul, 34320 Avcilar-Istanbul, Turkey

⁴Department of Parasitology, Faculty of Medicine, University of Adnan Menderes, 09016 Isikli- Aydin, Turkey

gulcu@istanbul.edu.tr

Introduction: The helminths (Wordle, McLeod and Radinovsky 1974, mesocestoides valliant 1863) that belong to the *Mesocestoides* species are small and medium-sized eucestodes. Tetrathyridia are found in the serous cavities, especially the peritoneal cavity, and the liver and lungs. Tetrathyridia replicate in the intestines of dogs. They may proliferate in the peritoneal cavity by penetrating the gut wall. This may lead to development of pyogranulomatous peritonitis and adhesions.

Materials and Methods: The testicles of a cross bred cat who had bilateral orchiectomy was referred to our department. The dimensions of the left testicle were 1,1x1x0,7 cm whereas the dimensions of the right testicle were 1.3x1x0.8 cm. Both of their cut surfaces were yellowish in color. Lineal pattern resembling scatrix tissue was observed in the gross examination of the mediastinum testis.

Results: Histological evaluation of the right testicle revealed tetrathyridium larvae that had convoluted borders and a thick eosinophilic cuticle. They were composed of single layer of cells. They had numerous calcareous corpuscles within and their transversal sections showed suckers in the invaginated ducts. The largest radius of the larvae was measured as 1.23x0,87 mm while the smallest was 1.005x0.37 mm. There were numerous lymphocytes, macrophages, foreign body giant cells and a small number of plasma cells and they were surrounded by a fibrous capsule.

Conclusion: This is the first description of intratesticular tetrathyridia in a cat.

Poster Abstracts

Infectious Disease

PP-22

ASPERGILLOSIS AS THE MOST IMPORTANT POST-HATCHING PROBLEM IN LOWER-SILESIA GEES

K. Bobusia*, K. Bobrek*, A. Gawel*, M. Nowak†, R. Ciaputa†, M. Kandefer-Gola†

*Department of Epizootiology and Clinic of Bird and Exotic Animals, †Department of Pathology, University of Environmental and Life Sciences, Wrocław, Poland

katarzyna.bobusia@gmail.com

Introduction: Aspergillosis, yolk sac inflammation and gout are the most common post-hatching problems in poultry. Aspergillosis is an acute or chronic disease, primarily affecting the respiratory system, but peritoneal, visceral and systemic infections can also occur. The agent is *Aspergillus fumigatus*. The aim of the study was to determine the percentage of *Aspergillus fumigatus* infections among all post-hatching diseases in 1day old gosling in Lower-Silesia in 2008-2012.

Materials and Methods: Tissue samples were examined using classical microbiological procedures. Sampled cuttings of organs were fixed, then transferred to paraffin blocks and sliced to 4µm sections.

Results: In years 2008-2013, 116 samples from 1 day old geese were examined. In 61 samples *Aspergillus fumigatus* growth was detected. In 2008 aspergillosis occurred in 81% cases, in 2009 – 67% cases, 2010 – 15% cases, 2011 – 32% cases, 2012 – 11% samples taken from 1day old gosling.

Conclusion: Occurrence of aspergillosis in the area of Lower Silesia in 2008 - 2012 amounts 52,6% and it is the most common disease in 1day old gosling. *Aspergillus fumigatus* can penetrate egg shell and infect the embryos. Broken infected eggs are a source of *Aspergillus* spores which contaminate hatching birds via the respiratory system. We observed that during rainy summers, aspergillosis occurred more often.

Poster Abstracts

Infectious Disease

PP-23

INCLUSION BODY HEPATITIS (IBH) IN LOWER-SILESIA – POLAND

K. Bobusia*, K. Bobrek*, A. Gawel*, M. Nowak†, R. Ciaputa†, M. Kandefer - Gola†

**Department of Epizootiology and Clinic of Bird and Exotic Animals, †Department of Pathology, Division of Pathomorphology and Veterinary Forensic, University of Environmental and Life Sciences, Wrocław, Poland*

katarzyna.bobusia@gmail.com

Introduction: Inclusion body hepatitis (IBH) is an adenoviral infection of young chickens characterized by sudden onset and sharply increased mortality, short course, anemia, and hepatitis, often accompanied by intranuclear inclusion bodies. The aim of the study was determine percentages of IBH in all diagnosed broilers' diseases processing with hepatic changes among provided samples in University of Environmental and Life Sciences in Wrocław in 2010-2013.

Materials and Methods: Sampled cuttings of liver with lesions were fixed in 7% formalin, then transferred to paraffin blocks and sliced to 4µm sections.

Results: In 2010, 16 cases IBH was diagnosed, in 2011- 43 IBH cases, in 2012- 22 IBH cases and in 2013 (up to the end of May) - 9 cases IBH. In 2010 it is 26,2%, in 2011 - 29,9%, in 2012 - 16,5% and in 2013 - 16,1%, among all diagnosed broilers' diseases with changes in liver.

Conclusion: Occurrence of IBH in the area of Lower Silesia in 2010 - 2012 amounted to 26,2%, which is comparable to the data obtained in the area of Warsaw where IBH percentage in 1999 - 2010 was 29%. In 2012-2013 a marked reduction was observed among diagnosed cases, which amounted to 16,3%.

Poster Abstracts

Infectious Disease

PP-24

FACTORS CONTRIBUTING TO AXONOPATHY AND AXONAL REGENERATION IN CANINE DISTEMPER LEUKOENCEPHALITIS

C. Lempp*, F. Seehusen*, I. Spitzbarth* and W. Baumgärtner*

**Department of Pathology, University of Veterinary Medicine, Hannover, Germany*

charlotte.lempp@tiho-hannover.de

Introduction: While demyelination in canine distemper leukoencephalitis (DL) has been explored extensively in order to serve as a spontaneous virally induced animal model for human demyelinating diseases, aspects of axonal pathology during DL still need to be investigated. Especially the role of axonal cytoskeleton alterations, axonal transport mechanisms, and possible spontaneous axonal regeneration attempts remains elusive so far.

Materials and Methods: Formalin-fixed and paraffin-embedded cerebellar sections of healthy controls and dogs with different stages of DL have been investigated morphologically and immunohistochemically using antibodies against phosphorylated and non-phosphorylated neurofilament (pNF, nNF), alpha-acetylated tubulin, β -tubulinIII, dynein, kinesin, and tau for quantification of axonal transport deficiencies. Furthermore, antibodies against growth-associated protein (GAP)43, erythropoietin (EPO), EPO-receptor(R), hypoxia-inducible factor (HIF), LINGO-1, and Nogo-A, were used to detect molecules involved in axonal outgrowth and its inhibition, respectively.

Results: Significantly decreased expression of neurofilaments, microtubules and motor proteins beginning in the early phase of the disease was evident. In parallel to Nogo-A and LINGO-1, expression of EPO and HIF were up-regulated in both the acute and subacute stages. EPO-R-expression, in contrast, was decreased within the lesions. GAP43 was not expressed.

Conclusions: Persisting axonopathy during DL is characterized by an early onset of axonal cytoskeleton disturbances and altered axonal transport mechanisms. Thus, it may serve as a triggering mechanism for subsequent secondary demyelination and possibly impairs spontaneous regeneration.

Poster Abstracts

Infectious Disease

PP-25

DETECTION OF BOVINE PAPILLOMAVIRUS AND EFFICACY OF TREATMENT USING SAPONIN

R.Puleio, F.Antoci, G. Tumino, A. Tamburello, P. Di Marco, G. Purpari, A.Guercio, G.R.Loria

Istituto Zooprofilattico Sperimentale della Sicilia, Italy

roberto.puleio@izssicilia.it

Introduction: Papillomas of teats and udders in cows may cause skin lesions, thelitis, mastitis and poor milking resulting in economic losses. We describe an outbreak of bovine papillomavirus (BPV) and successful treatment with a purified extract of *Quillaja saponaria* bark (Quil-A).

Materials and Methods: Twenty cows showed classic lesions of papillomatosis of the neck, teats and udder. Diagnosis was based on clinical signs, histopathology, immunohistochemistry, polymerase chain detection (PCR) and detection of the BPV by transmission electron microscopy. All affected cows were treated with 5ml of Quil-A (200 µg/ml) injected subcutaneously daily for seven days. Immunohistochemistry for CD3, Ki-67, MHC-II, cytokeratin and vimentin were performed on samples collected before and after treatment with Quil-A.

Results: The lesions were characterized by epithelial hyperplasia, acanthosis, hyperkeratosis and fibroplasia of the underlying dermis. BPV was found in the epidermis by immunohistochemistry. BPV-specific DNA was also detected by PCR. CD3-positive lymphocytes were present in the epidermis and particularly in the dermis. Sixteen of the 20 Quil-A treated cows showed a visible regression of cutaneous lesions.

Conclusions: The immune response of cattle to BPV is poor. In the present outbreak, we believe that papilloma regression was stimulated by the subcutaneous inoculation of Quil-A, which induced a Th1 immune response and production of cytotoxic T-lymphocytes against virus; leading to a satisfactory outcome.

Poster Abstracts

Infectious Disease

PP-26

OUTBREAK OF BOVINE MASTITIS CAUSED BY MYCOPLASMA BOVIS IN SICILY

R.Puleio*, A. Tamburello*, R.Ayling[†], R. Nicholas[†], G.R.Loria*

*Istituto Zooprofilattico Sperimentale della Sicilia**, *Mycoplasma Laboratory, Animal Health Veterinary Laboratories Agency-Weybridge, UK[†]*

roberto.puleio@izssicilia.it

Introduction: *Mycoplasma bovis* has a major role in respiratory disease, but is also considered a cause of mastitis in dairy cows. This study describes an outbreak of *M. bovis* mastitis observed in a herd of dairy cattle in Sicily.

Materials and Methods: Laboratory investigations were carried out on milk collected from all mammary quarters of each cow. Udders and supra-mammary lymph-nodes were also collected from slaughtered animals. Tissues were processed with routine histological staining. Immunohistochemistry was performed on tissues for markers including CD3, CD79, MHC-II and S-100.

Results: Mycoplasmas were seen in cultures of milk from affected cattle identified later by PCR as *M. bovis*. The identity of the isolates were confirmed by PCR/DGGE at AHVLA (UK). Gross findings showed multifocal to coalescent grey–reddish areas of parenchymal retraction, mostly involving single or groups of lobules. Histologically the interstitium was fibrotic and enlarged by diffuse lymphocytic infiltration. Scant catarrhal exudate including macrophages, lymphocytes and plasma cells was observed within the udder-alveolar lumina.

Conclusions: In EU, *M. bovis* has been associated with a variety of diseases such as pneumonia, arthritis and conjunctivitis but only rarely a cause of mastitis, even less so in Southern Italy. The authors underline the risk of importation of dairy cows from infected countries.

Poster Abstracts

Infectious Disease

PP-27

HISTOPATHOLOGICAL AND IMMUNOHISTOCHEMICAL STUDIES OF LESIONS INDUCED BY *MYCOPLASMA MYCOIDES* SUBSPECIES *CAPRI* IN GOAT

R.Puleio*, F.Messina*, R. Ayling[†], R. Nicholas[†], G.R.Loria*

*Istituto Zooprofilattico Sperimentale della Sicilia**, *Mycoplasma Laboratory, Animal Health Veterinary Laboratories Agency-Weybridge, UK[†]*

roberto.puleio@izssicilia.it

Introduction: *Mycoplasma mycoides subsp capri* (M.m. capri) have been reported to cause caprine mastitis, pleuropneumonia, polyarthritis, and septicaemia. The authors report three severe outbreaks of disease in goat herds caused by M.m. capri.

Materials and Methods: Post-mortem examination was carried out on kids which had presented with severe polyarthritis and respiratory disease. Joint fluid, conjunctival swabs, nasal swabs, and milk were cultured according to standard procedures followed by biochemical tests and PCR. Tissue samples were taken for histological and immunohistochemical examination. Cells in tissue expressing *M.m. capri* antigen, MHC-II, S-100, CD3 and CD79 lymphocytes were determined by immunohistochemistry.

Results: Culture tests revealed the presence of typical "fried egg" colonies. Further biochemical and molecular biological tests confirmed *M.m. capri*. Histological lesions consisted of interstitial pneumonia, pericarditis, while joints were characterized by arthrosynovitis with sero-fibrinous exudate and infiltration of S-100⁺ dendritic cells, MHC-II⁺ cells and CD3⁺ lymphocytes of the synovial capsule and periarticular tissues. The lymph nodes showed a reactive hyperplastic lymphadenitis. Immunohistochemical investigations showed the presence of *M.m. capri* in lungs and joints.

Conclusions: These results further contribute to characterization of the lesions and local immune response against M.m.capri in kids.

Poster Abstracts

Infectious Disease

PP-28

LACK OF SCHMALLENBERG VIRUS OCCURRENCE PRIOR TO 2011 IN GERMANY

M. Weigand*, I. Gerhauser*, K. Hahn*, V. Herder*, A. Habierski*, F. Seehusen*, P. Wohlsein*, M. Varela+, M. Palmarini+ and W. Baumgärtner*

*Department of Pathology, University of Veterinary Medicine, Hannover, Germany and + MRC-University of Glasgow Centre for Virus Research, Glasgow, United Kingdom

malin.weigand@tiho-hannover.de

Introduction: Schmallenberg virus (SBV), an orthobunyavirus of the family *Bunyaviridae*, represents a ruminant pathogen, which caused epidemic abortions and births of malformed or stillborn animals in many European countries since August 2011.

Materials and Methods: To further elucidate the occurrence of SBV, archived material of the central nervous system (CNS) of ruminants originating from Northern Germany and submitted for necropsy between 1961 and 2010 was investigated by using immunohistochemistry and *in situ* hybridisation. 84 cattle, 49 sheep, 11 goats, and 20 wild ruminants were included in this retrospective study. The scrutinized ruminants were either aborted or neonatal animals, preferentially showing skeletal or CNS malformations, or adult animals with encephalitis.

Results: Immunohistochemistry and *in situ* hybridisation detected many SBV-positive cells in positive control sections. However, preliminary analysis detected neither SBV RNA nor protein in the CNS of investigated animals collected prior to the SBV endemic in 2011.

Conclusions: Based on the present findings, there is no evidence of SBV infection prior to 2011. Consequently, SBV might have evolved lately from closely related arthropod-borne viruses recently introduced into Northern parts of Europe.



Poster Abstracts Infectious Disease

PL-29

APOPTOSIS IN EARLY AND LATE POST-INFECTION STAGES OF SHEEP CHALLENGED WITH *Fasciola hepatica*

A. Escamilla*, R. Zafra ‡, E. Mozos*, M.J. Bautista*, I.L. Pacheco*, M.T. Ruiz*, L. Buffoni†, R. Pérez†, A. Martínez-Moreno†, J. Pérez*

* Department of Comparative Pathology, †Department of Animal Health (Parasitology), Faculty of Veterinary Medicine, University of Córdoba, Spain. ‡IUSA, University Las Palmas de Gran Canaria, Spain

an1momoe@uco.es

Introduction: Fasciolosis is an economically important disease in ruminants. *Fasciola hepatica* has shown several mechanisms of immune evasion and immunomodulation to survive in the host. Recent studies have reported that *F. hepatica* induces apoptosis of eosinophils and peritoneal macrophages in rats, but no studies have been conducted to elucidate if the parasite causes apoptosis in ruminant immune cells.

Materials and Methods: Nine 7-month-old *F. hepatica* free sheep were used for the study, group 1 (n=3) was infected with 200 metacercariae of *F. hepatica* and killed at 8 days post-infection (dpi), group 2 (n=3) were infected with the same dose and killed at 17 weeks post-infection (wpi), group 3 (n=3) was used as uninfected control. Apoptosis was investigated in liver tissue sections using two anti-caspase 3 antibodies.

Results and Conclusions: At 8 dpi numerous apoptotic cells expressed caspase 3 at the periphery of necrotic foci; these cells show morphologic features consistent with macrophages, eosinophils, lymphocytes and hepatocytes. At 17 wpi, caspase 3+ cells were found in the vicinity of some bile ducts containing adult parasites.

Poster Abstracts

Infectious Disease

PP-30

DOUBLE-NEGATIVE T CELLS IN BLOOD AND CEREBROSPINAL FLUID OF DOGS WITH VISCERAL LEISHMANIASIS

G.D. Melo*, F.G. Grano*, J.E.S. Silva*, A. Schweigert*, J.M. Silva*, G. F. Machado*

*São Paulo State University (UNESP), College of Veterinary Medicine (FMVA), Laboratory of Applied Pathology (LAPAP), Araçatuba-SP, Brazil

di.melo@uol.com.br

Introduction: CD3⁺ T-cells can coexpress either CD4 or CD8 receptors, or none of them, belonging to double-negative (DN) T-lymphocyte subset (CD3⁺CD4⁻CD8⁻). Since dogs infected by *Leishmania chagasi* may exhibit deficits in the immune response, we aimed to characterize the T-lymphocytes subsets in the blood and cerebrospinal fluid (CSF) of dogs with natural visceral leishmaniasis (VL).

Materials and Methods: Blood and CSF were collected from 17 infected dogs, and lymphocytes were identified by flow cytometry using the anti-CD3/CD4/CD8 antibody (AbD Serotec, TC014).

Results: In average, blood mononuclear cells were composed of 13.5% CD3⁺CD4⁺ lymphocytes, 8.9% CD3⁺CD8⁺ cells, and 48.6% DN cells. Further, in the CSF, 9.9% of CD3⁺CD4⁺ cells, 6.4% of CD3⁺CD8⁺ lymphocytes, and 66.2% of DN cells were observed. CD4 and CD8 T-lymphocytes were both reduced in blood and CSF, compared to normal reference ranges, and DN T-cells were increased and the predominant lymphocyte subset in blood as well as in CSF.

Conclusions: DN T-cells are important to produce immunoregulatory cytokines in human VL. The reduction of CD4 and CD8 lymphocytes subsets was expected in VL and the predominance of DN T-lymphocytes is suggestive that these cells play a role in the immune response during canine VL; however, their modulatory or cytolytic role must be determined.

Poster Abstracts Infectious Disease

PP-31

PULMONARY MACROPHAGES AS PRIMARY SOURCE OF CYTOKINES IN RESPONSE TO INFECTION WITH DIFFERENT PRRSV-1 STRAINS

S.P. Amarilla*, J.Gómez-Laguna*, I.M.Rodríguez-Gómez*, I.Barranco*, L.Carrasco*, S.B. Morgan**, T.W. Drew**, Salguero FJ**

*University of Cordoba-Spain. **Animal Health and Veterinary Laboratories Agency-United Kingdom.

ashyrleypaola@yahoo.com

Introduction: Porcine reproductive and respiratory syndrome (PRRS) strains show high differences among and within genotypes, being recently described several highly pathogenic PRRSV strains. In this study we identify the main cell type involved in the expression of cytokines in the lungs of pigs experimentally infected with different PRRSV-1 strains and their relationship with immunopathogenic mechanisms.

Materials and Methods: Sixty-eight 5-week-old pigs were inoculated with 1) control mock-infected; 2) Lelystad prototype virus (LV); 3) 215-06, British field strain; 4) SU1-Bel, highly virulent strain from Belarus, or 5) a commercial modified live vaccine. Animals were euthanized at 3, 7 and 35dpi. Immunohistochemistry was used to detect the expression of PRRSV, TNF- α , IL-1 α and IL10. Cell types were identified based on their morphological characteristics.

Results: In the animals infected with the prototype virus (LV), moderate (215-06) and virulent (SU1-Bel) strains the virus was mainly expressed by alveolar macrophages (AMs). Whereas the expression of TNF- α and IL-1 α was detected mainly in septal macrophages with all the strains, IL-10 was expressed by septal macrophages in SU-1 but in AMs in LV, 215-06 or vaccinated animals.

Discussion & Conclusion: Our results indicate that pulmonary macrophages may be differentially activated after different PRRSV-1 strains infection what may be involved in the differences observed among strains and/or genotypes.

Poster Abstracts

Infectious Disease

PP-32

VISCERAL LARVAL MIGRANS IN A HORSE

P.J.Brown*, H. Elsheikha* and S.Turner[‡]

**School of Veterinary Medicine and Science, University of Nottingham, Sutton Bonington Campus, LE125 RD, UK and Chine House Veterinary Hospital, Sileby, LE12 7RS, UK[‡]*

pbathome@hotmail.co.uk

Introduction: A 10 year old thoroughbred gelding was presented for post mortem examination relating to a suspected cervical spinal lesion causing rapidly worsening ataxia affecting all four limbs.

Materials and Methods: A full post mortem examination was carried out, including histological examination of representative samples of major organs.

Results: At necropsy, no lesion was noted affecting the cervical spine but one kidney, and local lymph nodes, were enlarged, and virtually replaced, by solid, coarsely-lobulated white tissue; a renal tumour (a carcinoma or possibly lymphoma) was suspected. There were no signs of intestinal parasitism. Microscopic examination of sections of the kidney, and enlarged lymph nodes revealed an extensive granulomatous inflammation with large numbers of epithelioid macrophages and giant cells. Within many granulomas there were many sections of structures typical of parasite larvae. Similar larvae were present within small blood vessels in areas of malacia in sections of the cervical spinal cord. No larvae were detected in sections of a wide range of other organs.

Conclusions: Visceral larval migrans is not commonly reported in domestic animals and does not appear to have been described in horses, despite the common incidence of intestinal parasites. The parasite species involved in this case was not identified. The precise source of the parasitic infection and the localisation of lesions to one kidney are difficult to explain.

Poster Abstracts

Infectious Disease

PP-33

IMMUNOHISTOCHEMICAL DETECTION OF JAPANESE ENCEPHALITIS VIRUS IN AVIAN MYELOID LINEAGE CELLS

G. Rossi^{*}, A. Platonov[†], G.E. Magi^{*} and P. Mani[‡]

^{}School of Veterinary Medical Sciences, University of Camerino, Italy, [†]Central Research Institute of Epidemiology, Moscow, Russia and [‡]Department of Animal Pathology, Prophylaxis and Food Hygiene, University of Pisa, Italy*

giacomo.rossi@unicam.it

Introduction: Between 1997 and 2000, birds (mainly blackbirds and song thrushes) were collected during mortality episodes occurred in a wetland area located in Tuscany, where cases of West Nile virus (WNV) infection in horses were observed in 1998.

Materials and Methods: Formalin-fixed tissue samples from 14 birds collected in 1997 and 7 collected in 2000 that tested positive for JE group antigens by immunohistochemistry (IHC), were sent to the Central Research Institute of Epidemiology in Moscow, to carry out molecular testing for flaviviruses.

Results: None of the samples tested positive for WNV, but PCR amplicons of the Japanese Encephalitis Virus (JEV) NS5 gene and the JEV E gene, were obtained from tissues of 7 birds. Sequencing of 552 bp fragments of the JEV E gene (GenBank AF501311-AF501315) and of NS5 amplicons, showed high similarity (99%) with JEV genotype III (Nakayama strain). IHC for JEV (pAb, PG 10004) was positive in 13 of 21 bone marrows, with stem cells positive also for anti CD11b (pAb, ab75476). Positive reactions were also present in neurons, microglial cells, kidney, spleen, liver, lung and gastrointestinal tract ganglia.

Conclusions: This is the first description of JEV localization in myeloid lineage cells of avian bone marrow, a possible important reservoir for this virus.

Poster Abstracts

Infectious Disease

PP-34

DIFFERENTIAL CYTOKINE EXPRESSION IN BCG VACCINATED AND EXPERIMENTALLY INFECTED CATTLE WITH *Mycobacterium bovis*

S. Gibson, B. Villarreal-Ramos, J. Gough, T.S. Strickland, H.M. Vordermeier and F.J. Salguero

Animal Health and Veterinary Laboratories Agency, Weybridge, KT15 3NB, U.K.

javier.salguero@ahvla.gsi.gov.uk

Introduction: Bacillus Calmette-Guérin (BCG) is currently the only viable candidate for immunisation of cattle against bovine tuberculosis, caused by *Mycobacterium bovis*.

Materials and Methods: In an attempt to characterise the differences in the immune response following *M.bovis* infection between BCG vaccinated and unvaccinated animals, a combination of gross pathology, histopathology and immunohistochemical (IHC) analyses were used.

Results and Discussion: BCG vaccination was found to significantly reduce the numbers of gross and microscopic lesions present within the lungs and lymph node. Additionally, the bacterial load of the granulomas significantly reduced for stage III and IV of granulomas development.

IHC using cell markers revealed the numbers of macrophages (CD68+), CD3+ lymphocytes and WC1+ gamma-delta T cells to be significantly reduced in lymph node granulomas of BCG vaccinated cattle, when compared to non-vaccinated control animals. B lymphocytes (CD79a+) were significantly increased in vaccinated cattle for three stages of development. TGF-beta expression showed significant downregulation in the earliest stage granuloma in BCG vaccinated cattle. IHC analysis of the cytokines IFN-gamma and TNF-alpha demonstrated significantly increased expression within the lymph node granulomas of BCG vaccinated cattle. This is suggestive of a protective role of IFN-gamma in the response to *M.bovis* infection.

Poster Abstracts

Infectious Disease

PP-35

DEVASTATING EFFECT OF PERSISTENT ASYMPTOMATIC INFECTION OF MINKS WITH ALEUTIAN MINK DISEASE VIRUS ON REPRODUCTIVE PERFORMANCE

K. Kostro*, P. Reichert[†] and M. Reichert[‡]

** Department of Epizootiology, Clinic of Infectious Diseases, Faculty of Veterinary Medicine, University of Life Sciences, Lublin, Poland, [†] Small Animal Practice, Pulawy, Poland and [‡] Department of Pathology, National Veterinary Research Institute, Pulawy, Poland*

reichert@piwet.pulawy.pl

Introduction: Aleutian mink disease is a chronic and incurable sickness of farm-raised and wild mink caused by a AMD virus (AMDV) belonging to the family Parvoviridae. The aim of this study was to assess the impact of asymptomatic infections of mink from the two AMD-endemic farms on the morphological changes of the internal organs and reproductive performance.

Materials and Methods: The study included 450 clinically healthy female minks divided in to three experimental groups (two PCR confirmed AMDV positive groups and one AMDV negative control group with 150 animals each. Minks were subjected to clinical observations, throughout the period of reproduction, and then for the first 7 weeks after birth. Data collected during this period were evaluated using selected breeding and reproductive indices. At the time of necropsy histopathological assessment was included as well.

Results: All reproductive indices including conception rate, litter size and litter weight at birth as well as neonatal mortality were significantly poorer. Histopathological examination revealed changes typical for AMD in particular in spleen, kidneys, liver and lymph nodes.

Conclusions: Obtained results highlight and prove the frequently underestimated extent of economic losses on AMD endemic mink farms.

Poster Abstracts

Infectious Disease

PP-36

PRRS VIRUS DISTRIBUTION IN TISSUES FROM PIGS EXPERIMENTALLY INFECTED WITH DIFFERENT GENOTYPE 1 STRAINS

S.B. Morgan¹, F.J. Pallares^{1,2}, J. Gough¹, J.P. Frossard¹, S.P. Graham¹, F. Steinbach¹, T.W. Drew¹ and F.J. Salguero¹

¹Animal Health and Veterinary Laboratories Agency – Weybridge, United Kingdom and ²Faculty of Veterinary Medicine, University of Murcia, Spain

javier.salguero@ahvla.gsi.gov.uk

Introduction: The appearance of highly pathogenic PRRS strains in Europe and Asia has raised concerns about this disease and increased efforts to understand the pathogenesis.

Materials and Methods: Sixty 5-week-old pigs were inoculated with a) the Lelystad virus (LV); b) a field strain from the UK causing respiratory clinical signs (215-06) or c) a highly pathogenic strain from Eastern Europe (SU1-Bel). Sixteen animals were mock-infected and used as control. Animals were killed at 3, 7 and 35dpi. Histopathology and apoptosis were studied by H&E and TUNEL. Immunohistochemistry was used to detect the expression of PRRSV nucleocapsid.

Results: Histopathological lesions consisted in interstitial pneumonia with mononuclear cell infiltrates in the lungs, lymphoid depletion and follicular hyperplasia, apoptosis and lymphoid depletion in lymph nodes, tonsil and thymus. PRRSV was detected mainly in monocyte-macrophages. SU1-Bel infected animals showed the highest pathological scores and the highest presence of virus at 3 and 7 dpi, followed by the U.K. field strain and then LV. Moderate lesions were observed at 35 dpi with a lower PRRSV detection by IHC in all the infected groups.

Conclusion: Highly pathogenic SU1-Bel strain induced more severe pathology in both lungs and lymphoid organs of pigs compared to classic field isolates and the prototype LV. These results correlate with the number of PRRSV infected cells.

Poster Abstracts

Infectious Disease

PP-37

DIFFERENTIAL EXPRESSION OF IL8 IN PARENCHYMA, BRONCHI AND BRONCHUS-ASSOCIATED LYMPHOID TISSUE (BALT) OF PIGS INFECTED WITH MYCOPLASMA HYOPNEUMONIAE (MHYO)

R.S. Rosales¹, F.J. Pallarés², J. Gough¹, T.S. Strickland¹, R.D. Ayling¹, R.A.J. Nicholas¹, F.J. Salguero¹

¹Animal Health and Veterinary Laboratories Agency – Weybridge, United Kingdom and ²Faculty of Veterinary Medicine, University of Murcia, Spain

javier.salguero@ahvla.gsi.gov.uk

Introduction: IL8, one of the main chemokines involved in the respiratory innate immune response has been suggested to have a key function in Mhyo induced pneumonia. In order to gain a better insight into the role of this chemokine in Mhyo infections, the differential mRNA relative expression of IL8 in various porcine lung cell populations obtained from healthy and Mhyo-infected animals by laser capture microdissection (LCM) was analysed.

Materials and Methods: Tissue samples from lung parenchyma and bronchi were collected from both Mhyo-infected (n=5) and a non-infected control group (n=5) by LCM. In addition BALT was also obtained from the Mhyo infected group. Total RNA was then extracted and the differential relative expression of IL8 quantified by qPCR.

Results: IL8 was shown to be unregulated in parenchyma, bronchi and BALT obtained from infected animals when compared to the parenchyma and bronchi from non-infected control animals. IL8 mRNA upregulation observed in both the parenchyma and bronchi which was statistically significant when compared to BALT in infected animals.

Conclusions: Our results confirm the role of IL8 in the immune response against Mhyo infections. In addition, the differences observed between tissues highlights the usefulness of LCM in this type of pathogenesis study by eliminating the effect of mixed cell populations and organic compartments in expression assays.

Poster Abstracts

Infectious Disease

PP-38

DISSEMINATED FUNGAL INFECTION CAUSED BY *SCEDOSPORIUM PROLIFICANS* IN A BORDER COLLIE

K. Erles*, A. Mugford[#], D. Barfield[#], T. Ross*, K. Anfinson[#], and D.B. Church[#]

The Royal Veterinary College, Hatfield, United Kingdom

*Department of Pathology and Pathogen Biology

[#]Department of Clinical Sciences and Services

kerles@rvc.ac.uk

Introduction: *Scedosporium prolificans* has been recognised as an opportunistic fungal pathogen of humans causing disseminated infections in immunocompromised individuals. The fungus is resistant to most antifungal treatments. There are few reports of localised infections with *S. prolificans* in animals and only one previous report of disseminated infection in a dog.

Materials and Methods: An 11 month old Border Collie presented with a history of poor growth, weight loss, cough and cyclical pyrexia. He was recumbent and poorly responsive. Clinical findings included harsh lung sounds, pyrexia and marked anaemia. His clinical condition deteriorated and he died of respiratory arrest.

Results: Post mortem examination showed numerous firm white to yellow foci within the myocardium, pancreas and kidneys and pale red foci on the meningeal surface of the brain. The lungs exhibited multifocal consolidation. Histological examination revealed necrosis within the myocardium, kidneys, pancreas, lungs and brain with numerous septate fungal hyphae that exhibited haphazard to dichotomous branching and lemon-shaped conidia. Culture of lung and brain yielded a fungal isolate that was identified as *Scedosporium prolificans*.

Conclusion: Disseminated infections with filamentous fungi in dogs are most commonly associated with *Aspergillus* spp; while infection with *S. prolificans* has rarely been reported. The morphology of *S. prolificans* in tissue sections is similar to *Aspergillus* spp. and fungal culture or PCR may be required for definitive diagnosis.

Poster Abstracts

Infectious Disease

PP-39

ANIMAL MODELS TO INVESTIGATE THE ROLE OF GAMMAHERPESVIRUSES IN PULMONARY FIBROSIS

Gail Leeming*, Alexandra Malbon*, Udo Hetzel[†], James P Stewart*, Anja Kipar*[†]

*Veterinary Pathology & Department of Infection Biology, School of Veterinary Science, University of Liverpool, UK; [†]Veterinary Pathology, Faculty of Veterinary Medicine, University of Helsinki, Finland

akipar@liverpool.ac.uk

Introduction: Equine multinodular pulmonary fibrosis (EMPF) is an emerging disease, characterised mainly by a loss of functional pulmonary parenchyma due to extensive interstitial fibrosis and is strongly associated with equine herpesvirus 5 (EHV-5), a gammaherpesvirus (γ -HV).

Materials and Methods: We conducted a retrospective study on EHV-5 positive EMPF cases and an experimental study on CD-1 mice, infected with murine γ -HV (MuHV-4, MHV-68) and euthanised at 7, 14 and 23 days post infection (dpi). In situ hybridisation and immunohistology served to demonstrate EHV-5 and MHV-68, inflammatory and proliferating cells, and TGF- β expression.

Results: EMPF was characterised by marked multifocal interstitial fibrosis with pyogranulomatous inflammation and type II pneumocyte hypertrophy and hyperplasia, with EHV-5 present in type II pneumocytes and infiltrating macrophages. CD-1 mice exhibited transient pulmonary pyogranulomatous inflammation, diffuse macrophage recruitment and lesional and alveolar fibrosis, first seen at 7 dpi and peaking at 14 dpi. MHV-68 tRNA was detected in hypertrophic type II pneumocytes. In both species, TGF- β expression, mainly by infiltrating macrophages, was seen.

Conclusions: Our studies provide further proof that γ -HV can directly induce pulmonary fibrosis and identify natural and experimental animal models to investigate the role of γ -HV in the human disease.

Poster Abstracts

Infectious Disease

PP-40

COMPARISON OF CLASSICAL SWINE FEVER VIRUS ATTENUATED STRAINS DISTRIBUTION IN TISSUES OF INOCULATED PIGS

K. Podgorska, A. Szczotka-Bochniarz, K. Czajor, B. Malek, K. Kamieniecka, K. Stepniewska and Z. Pejsak

National Veterinary Research Institute, Department of Swine Diseases, Pulawy, Poland

anna.szczotka@piwet.pulawy.pl

Introduction: Previous analysis indicated that CSFV attenuated strains used for production of vaccines show unexpected genetic divergence. The aim of this study was to compare the course of early infection and tissue distribution of most divergent attenuated CSFV strains.

Materials and Methods: Two groups of 12 pigs were vaccinated with KPS87 and Chinese (C-strain) CSFV strains (91.7% of sequence identity within E2 region). Blood samples were collected twice a week. Three pigs were euthanized at 7, 14, 21 and 28 days post inoculation (dpi). Samples were tested with Real-Time RT-PCR (sera and tissues), NPLA (sera) and IHC (tissues).

Results: None of the pigs inoculated with C-strain developed viremia while in the second group virus was detected in blood of 5 pigs. KPS87 infection spread to higher number of tissues and persisted for a longer period compared to C-strain. In pigs from C-strain group neutralizing antibodies were detected earlier and reached higher levels compared to KPS87 inoculated pigs.

Conclusions: The C-strain of CSFV induced an earlier and more robust immune response and had lower tissue distribution, making it the strain of choice for emergency vaccination and comparative analysis of new vaccines.

The study was financed by a grant from the Polish Ministry of Science and Higher Education (N N308 293537).

Poster Abstracts

Infectious Disease

PP-41

CONCOMITANT CANINE HERPESVIRUS-1, CANINE DISTEMPER VIRUS, CANINE PARVOVIRUS, AND CANINE ADENOVIRUS INFECTIONS

S.A. Headley*, L. Bodnar*, A. P. Silva*, A. F. Alfieri*, L. A. Gomes*, W. Okano[‡], A. A. Alfieri*

**Laboratory of Animal Virology, Universidade Estadual de Londrina and [‡] School of Veterinary Medicine, Universidade Norte do Paraná, Brazil*

selwyn.headley@uel.br

Introduction: There are few descriptions of multiple infections in dogs. This study investigated the participation of canine herpesvirus type 1 (CaHV-1), canine distemper virus (CDV), canine adenovirus type 1 and 2 (CAV-1 and -2), and canine parvovirus type 2 (CPV-2) in dogs from southern Brazil.

Materials and Methods: Four 3-8 months-old, German Spitz, littermates (1, female; 3, males), one 47-days-old, Bichon Frisé, male pup, and a 3-years-old, mixed-breed, male dog that died spontaneously were necropsied. Clinical manifestations included abdominal pain, extreme vocalization, convulsions, and icterus. Routine necropsies were performed; duplicate tissues were collected for histopathology and the molecular detection of specific genes of CDV, CaHV-1, CAV-1 and -2, and CPV by RT-PCR/PCR assays.

Results: All dogs demonstrated necrohemorrhagic hepatitis and nephritis, and vasculitis; pulmonary haemorrhage with necrotizing bronchitis, non-suppurative myocarditis and parvoviral enteritis occurred in most dogs. PCR/RT-PCR amplified the desired amplicons of CaHV-1, CDV, CPV-2, CAV-1 and CAV-2 E from multiple tissue of these dogs. Quadruple and triple viral coinfections were identified. The target tissues/organs of each pathogen demonstrated the characteristic pathological pattern(s) and contained viral DNA and/or RNA.

Conclusions: These findings support a diagnosis of coinfections due to CDV, CaHV-1, CPV-2a, CAV-1, and CAV-2 in these dogs.

Poster Abstracts

Infectious Disease

PP-42

BOVINE HISTOPHILOSIS IN SOUTHERN BRAZIL

S. A. Headley*, V. H. S Oliveira[‡], E. A. Beuttemüller[‡], G. F. Freire*, D. E Bronkhorst*, A. F. Alfieri[‡], W. Okano*, A. A. Alfieri[‡]

*School of Veterinary Medicine, Universidade Norte do Paraná, and [‡]Department of Veterinary Preventive Medicine, Universidade Estadual de Londrina, Brazil

headleysa@gmail.com

Introduction: *Histophilus somni* is the cause of histophilosis that is characterized by multi-systemic disease in ruminants. This study investigated the sudden death of three calves, one diarrheic calf, one aborted foetus, and feedlot steers ($n=12$) with respiratory distress from five farms in southern Brazil.

Materials and Methods: Necropsy was performed on all animals except those with respiratory difficulties, from which deep nasal swabs were collected. PCR assays targeted specific amplicons of Ovine herpesvirus 2, Bovine herpesvirus 1 and -5 (BoHV-1 and -5), *Listeria monocytogenes*, *H. somni*, Pestivirus, *Mycoplasma bovis*, and *Mannheimia haemolytica*; bovine group A rotavirus (BoRV-A) and bovine coronavirus (BCoV) were investigated in animals with diarrhoea and pulmonary disease.

Results: The principal pathological findings included vasculitis, thrombotic-meningoencephalitis, necrotizing myocarditis, hepatic abscesses, and bronchopneumonia. *H. somni* DNA was amplified in all calves, the brain of the aborted foetus, and swabs of five steers with pulmonary distress. The five steers also contained BoHV-1 DNA ($n=4$); two were positive for BCoV. All other PCR assays were negative; BoRV-A was not identified. Three *H. somni*-induced syndromes were identified: systemic ($n=4$), abortion ($n=1$), and pulmonary ($n=5$).

Conclusions: These findings confirm the involvement of *H. somni* in the different disease presentations on these farms.

Poster Abstracts

Infectious Disease

PP-43

THE FIRST CASE REPORT OF VERMINOUS PNEUMONIA IN CAMEL (*CAMELUS DROMEDARIUS*) WITH *SETARIA CERV*

Bagheri Farnoosh, Tavasoly Abbas

Department of Pathology, Faculty of Veterinary medicine, University of Tehran, Iran

f.bagheri@ut.ac.ir

Introduction: Usually the causative agents of verminous pneumonia in camels are *Dictyocalus filaria* and *Dictyocalus viviparus*. *Dictyocalus filaria* most commonly affect the lambs and goat kids, but *Dictyocalus viviparus* is seen in cattle. *Setaria cervi* a common parasite of cattle has been reported from sheep and goat.

Materials and Methods: From February 2009 to February 2010, 300 lungs of dromedary camels (1-11 year) slaughtered at an abattoir located in Tehran province, Iran were grossly examined for the presence of pneumonic lesions. 120 lungs were diagnosed affected, from which specimens were collected for histopathological and bacteriologic examinations.

Results: There were four cases of verminous pneumonia, three caused by a common pulmonary parasite of ruminant lungs (*Dictyocaulus*). The fourth case was a novel verminous pneumonia caused by *Setaria cervi*.

Conclusion: This is the first case report of verminous pneumonia caused by *Setaria cervi* in a camel.

Poster Abstracts

Infectious Disease

PL-44

USING PCR TO DETERMINE THE IDENTITY OF MYCOBACTERIA IN HISTOLOGIC AND CYTOLOGIC SPECIMENS

G. Reppas*, C. O'Brien[‡], R. Malik[†], J. Fyfe[‡]

**Vetnostics, Sydney, Australia and ‡ Victorian Infectious Diseases Reference Laboratory, North Melbourne, Australia and † Centre for Veterinary Education, The University of Sydney, Australia*

george.reppas@vetnostics.com.au

Introduction: Mycobacteriosis in animals can be diagnosed utilising existing histologic and cytologic techniques, but the specific mycobacterial species involved in such infections cannot be determined using these techniques alone. This study investigated the application of PCR methodologies to establish the presence and determine the identity of mycobacteria causing common syndromes affecting companion animals where histologic and cytologic specimens were available for further testing.

Materials and Methods: Histologic (routinely prepared paraffin-embedded, formalin-fixed [PEFF] tissue) and cytologic specimens (methanol-fixed Diff-Quik[®] stained smears and Ziehl Neelsen [ZN] stained smears) from patients where organisms were visible as negatively-stained or acid fast bacilli (AFB) were subjected to PCR testing (TaqMan qPCR, nested PCR using specific mycobacterial primers).

Results: PCR amplification of mycobacterial DNA was successfully performed using Diff-Quik[®] stained cytology smears obtained by fine needle aspiration (FNA) and PEFF tissues. ZN-stained smears were less suitable for PCR testing. There was good correlation between TaqMan qPCR assay threshold cycle (Ct) number and semi-quantitative estimates of AFB density in ZN-stained PEFF tissue specimens.

Conclusions: PCR techniques greatly facilitated the diagnosis and specific identification of mycobacterial infections in stained smeared and PEFF tissue specimens.

Poster Abstracts

Infectious Disease

PL-45

PRELIMINARY INVESTIGATIONS UTILISING A PANFUNGAL PCR TO DETERMINE THE IDENTITY OF FUNGAL INFECTIONS IN CYTOLOGIC SPECIMENS FROM ANIMALS

G. Reppas*, R. Malik[†], S. Sleiman[‡], C. Halliday[‡]

*Vetnostics, Sydney, Australia and [‡] Mycology Laboratory, CIDML, Westmead Hospital, Westmead, Australia and [†] Centre for Veterinary Education, The University of Sydney, Australia

george.reppas@vetnostics.com.au

Introduction: Fungal disease in animals is readily diagnosed utilising traditional histologic and cytologic techniques, although the specific fungal pathogen causing such infections cannot usually be identified with certainty. The aim of this study was to investigate the application of a published panfungal PCR protocol to confirm the presence of pathogenic fungi, and further, to identify the aetiological agent to the species level where stained smears were available for further testing.

Materials and Methods: Cytologic specimens (methanol-fixed, Diff-Quik[®] stained smears from fine needle aspirate biopsies (FNA)) submitted to a veterinary diagnostic laboratory displaying fungal elements (hyphae and/or yeast-forms), in variable numbers, from infected patients were included.

Results: PCR amplification (ITS regions) and sequence analysis of fungal DNA was successfully performed using Diff-Quik[®]-stained FNA cytology smears to the genus and species level in 12/14 and 8/14 cases respectively.

Conclusions: Panfungal PCR proved to be extremely reliable for the identification of specific aetiological agents in the majority of cytology smears tested. Such PCR methods complement routine cytopathologic assessment of smears in animals with fungal infections. Critically, such information greatly assists clinicians formulate cogent treatment regimes in many instances, without resorting to additional morbidity and expense of sedation, anaesthesia, surgical biopsy and attempted fungal culture.

Poster Abstracts

Infectious Disease

PP-46

CUTANEOUS NEOFORMATIONS ASSOCIATED WITH COINFECTION BY ORF VIRUS AND *ORTHOPOXVIRUS* IN GOATS IN SICILY

S. A. Mignacca, M.T.Capucchio*, E. Biasibetti*, G. Purpari, P. Di Marco, L. Spuria*, S. Muscia, D. Tasca, L. Gallina**, G. Casà**, V. Di Marco Lo Presti, A. Guercio.

*Istituto Zooprofilattico of Sicily; *Dept. Veterinary Sciences, University of Torino and **Dept. Medical Veterinary Sciences, University of Bologna, Italy*

dimarco.vince@gmail.com

Introduction: Parapoxvirus - ORF virus (ORFV) is the etiological agent of contagious ecthyma, a severe zoonotic exanthematic disease that affects small ruminants. It is usually characterized by highly infectious pustules and papillomatous lesions on the skin of the lips, tongue, and around the mouth. In more severe cases, the skin of the eyes, feet, vulva or udder may also be affected. The authors describe pathological and microbiological data of a coinfection by ORFV and *Orthopoxvirus* in a flock of 140 cross-breed goats living with sheep and cattle.

Materials and Methods: Proliferative lesions were submitted to histopathological and virological investigations (virus isolation, PCR, electron microscopy).

Results: During the autumn-winter period 2012-2013, 60 goat kids showed severe proliferative lesions in the skin. Microscopically diffuse, chronic ulcero-vesiculo-pustulo-proliferative lesions were observed. Hyperkeratosis, areas of ulceration in epidermis and predominantly neutrophilic inflammation in the dermis were also detected. Electron microscopy showed the presence of ORFV. PCR revealed the presence of *Parapoxvirus* and *Orthopoxvirus*.

Conclusion: Further investigations will lead to better understand the mechanism of the coinfection by both Poxvirus in goats and to evaluate the role of other species bred in the same flock.

Poster Abstracts

Infectious Disease

PP-47

IMMUNOPHENOTYPING OF CD3⁺ CD4⁻ CD8⁻ T LYMPHOCYTES IN LYMPH NODES OF DOGS WITH VISCERAL LEISHMANIASIS

J. E. S. Silva*, F. G. Grano*, G. D. De Melo*, J. M. Silva*, V. M. F. Lima[†] and G. F. Machado[†]

* Graduate students in Animal Science, Faculty of Veterinary Medicine, UNESP - Univ Estadual Paulista, Araçatuba-SP, Brazil

[†] Department of Clinics, Surgery and Animal Reproduction, Faculty of Veterinary Medicine, UNESP - Univ Estadual Paulista, Araçatuba-SP, Brazil

zeeduardo554@hotmail.com

Introduction: Leishmaniasis in Brazil is caused by the protozoan *Leishmania chagasi*, and the dog is the main reservoir of the disease. Canine leishmaniasis can be considered an immune-mediated disease because the parasite has the ability to modify the host's immune system. The purpose of this study was to immunophenotype T- lymphocytes CD3⁺ CD4⁻ CD8⁻ from lymph nodes of the head and popliteal region by flow cytometry.

Materials and Methods: Popliteal and head lymph nodes (retropharyngeal and mandibular) biopsies from 17 dogs with canine leishmaniasis confirmed by parasitological and serological tests were obtained. T lymphocyte population phenotyping by flow cytometry using monoclonal antibodies were realized.

Results: There was no difference in the percentage of T- lymphocytes CD3⁺ CD4⁻ CD8⁻ cells obtained in both head and popliteal lymph nodes. However the percentage of CD3⁺ CD4⁻ CD8⁻ cells observed in dogs with canine leishmaniasis was higher than in healthy dogs, according the literature.

Conclusions: Flow cytometry has proved to be a good method for immunophenotyping T cells in lymph nodes however further studies are needed to elucidate the role of the T cell subset CD3⁺CD4⁻CD8⁻ cells in the course of canine leishmaniasis.



Poster Abstracts

Infectious Disease

PP-48

HISTOLOGIC DETECTION AND PREVALENCE OF BIOFILMS IN FOREIGN BODY ASSOCIATED INFLAMMATORY REACTIONS IN DOGS, CATS AND HORSES

L. König, R. Klopfleisch, O. Kershaw, A. D. Gruber

Department of Veterinary Pathology, Freie Universität Berlin, Germany

lydia-marie.koenig@fu-berlin.de

Introduction: The role of bacterial biofilms in chronic inflammation associated with foreign body material including suture material and medical implants has been well characterized in humans. Here, we have established histological detection methods and the prevalence of biofilms in such conditions in pet animals.

Materials and Methods: Formalin fixed, paraffin embedded tissue samples (n=85) with inflammatory reactions associated with surgical suture material or surgical swabs from dogs, cats and horses were sectioned and stained with HE or a variety of special stains including Giemsa, Gram and the PAS reaction. Next generation sequencing of suspected biofilm material was performed in select cases.

Results: Biofilms with characteristic bacterial aggregates and extracellular matrix suggestive of extracellular polymeric substances (EPS) were detected in 2 of 85 samples (2.35 %).

Conclusion: HE, Giemsa and Gram stains combined with PAS reaction were found economical, reliable and sensitive tools for the detection of biofilms in routinely processed pathological tissue specimens. However, the prevalence of biofilms was surprisingly low in our study. Lack of convincing results from a deep sequencing approach may be due to degradation of nucleic acids in this material.

Poster Abstracts Infectious Disease

PP-49

THE FIRST REPORT OF OVINE CEREBRAL NEOSPOROSIS AS A CAUSATIVE AGENT OF ENCEPHALITIS IN IRAN

F. Sasani[†], J.Javanbakht^{†*}, P. Seifori[#], SS.Fathi[€] and M.A.Mohammad Hassan[‡]

[†]Department of Pathology, Faculty of Veterinary Medicine, Tehran University, Tehran, Iran

[#]Department of Pathology, Veterinary Organization of Iran, Tehran-Iran

[€]student, Department of Parasitology, Faculty of Veterinary Medicine, Tehran University, Tehran, Iran

[‡]Department of Clinical Sciences, Faculty of Veterinary Medicine, Tehran University, Tehran, Iran

Running Head: *Neospora caninum*

Corresponding author: Dr. Javad javanbakht

Department of Pathology, Faculty of Veterinary Medicine, Tehran University, Tehran, Iran

Tel: +989372512581, Fax: 9821143995115

javadjavanbakht@ut.ac.ir

Introduction: Neosporosis is an infection of animals caused by an intracellular coccidian parasite, *Neospora caninum*, closely related to *Toxoplasma gondii*. The parasite is an important cause of cattle abortions worldwide. The aim of this study was to investigate the presence of encephalitis in lambs aborted due to *N. caninum* infection.

Materials and Methods: During 2004 to 2008, 109 aborted fetal brains of sheep were collected to identify the possible causes of abortion from different provinces of Iran and were investigated in the pathology laboratory. Fetal histopathology was applied to detect the presence of protozoal-associated lesions in brain. The presence of *N. caninum* was confirmed by nested-PCR.

Results: Histopathological examination of one fetal brain demonstrated extensive suppurative and nonsuppurative meningoencephalitis, suppurative meningitis and non-septic and septic encephalitis. Some other brains showed gliosis (focal or diffuse). During the process of extracting DNA from 109 selected samples, DNA extracted from one case and amplified by semi-nested PCR was positive for the presence of *N.caninum*.

Conclusion: This study demonstrates that *N. caninum* can cause brain lesions in aborted lambs. This is the first report of this condition in sheep from Iran.



Poster Abstracts

Infectious Disease

PP-50

INTRACELLULAR YEASTS IN ENDOTHELIAL CELLS OF A GREAT BLUE HERON (*ARDEA HERODIAS*)

C Millins*, J Hill[‡], G Wobeser[‡]

*University of Glasgow, Glasgow, UK [‡]University of Saskatchewan, Saskatoon, Canada

c.millins.1@research.gla.ac.uk

Introduction: Outbreaks of disease in farmed domestic ducks in Canada and the United Kingdom have been associated with an unidentified intracellular organism. The identification and pathological features of a morphologically similar yeast organism in the endothelial cells of a great blue heron (*Ardea herodias*) are described.

Materials and Methods: A wild, adult female great blue heron being treated for trauma died during rehabilitation. At post mortem, tissues were collected for histology, aerobic bacterial culture was carried out on lung, spleen and kidney and fungal culture was attempted on lung tissue. Transmission electron microscopy was carried out on lung tissue. PCR using standard fungal primers for regions of the rRNA operon was carried out.

Results: The heron was very thin and there was a mild fibrinous coelomic and pericardial effusion. Microscopically, parabronchi were filled with edema. Many endothelial cells in the alveolar septa and rarely in other tissues were expanded by basophilic round to oval 1-2 µm structures which showed apical budding on electron microscopy. Phylogenetic analysis supported placement of the organism in the Saccharomycetales family of yeasts.

Conclusions: Intraendothelial yeast organisms were described as a potentially novel species in the Saccharomycetales family. Similar organisms have been associated with disease outbreaks in farmed ducks in Canada and the UK. Research to investigate the epidemiology, pathology and cost to the poultry industry is planned.

Poster Abstracts

Infectious Disease

PP-51

OBSERVATIONS OF EARLY LESIONS ASSOCIATED WITH *MYCOBACTERIUM TUBERCULOSIS* (ERDMAN STRAIN) FOLLOWING AEROSOL CHALLENGE IN THE RHESUS MACAQUE

E.L.Rayner, G.A.Hall, G.R.Pearson, M.Dennis, S.Sharpe

Public Health England, Wiltshire, UK

emma.rayner@phe.gov.uk

Introduction: The non-human primate provides an excellent model for human *M.tuberculosis* (*Mtb*) infection but little is known about development of early pulmonary lesions. A previous study described early lesion morphology in infection with the *M.tb* H37RV strain.

Materials and Methods: As part of a wider study to compare early events following aerosol challenge, three rhesus macaques received varying doses [98, 28, and 11 colony forming units (CFU)] of *M.tuberculosis* (*Mtb*) Erdman strain; tissues were examined microscopically at 24 -25 days post-challenge.

Results: Gross and microscopic tuberculous lesions were observed in the lungs of all animals; lesion numbers were proportional to the challenge dose. Regardless of dose, granulomas of similar size and stages of development were present, frequently with central, caseous necrosis. Involvement of bronchus-associated lymphoid tissue, bronchial/bronchiolar walls and intra-pulmonary lymphatics, were observed at all challenge doses. Hilar lymph nodes were markedly enlarged and variably effaced by necrotic, granulomatous inflammation. Scattered, microscopic lesions were present in all spleens and the liver of two animals (98 and 28 CFU), indicating systemic spread of infection.

Conclusion: Pathological findings following aerosol challenge with the Erdman strain of *Mtb* at early time points has enabled comparison with other strains e.g. H37RV, to improve understanding of early pathogenesis which may influence the design of future vaccine studies.

Poster Abstracts

Neoplastic Disease

PP-52

EPIDEMIOLOGICAL SURVEY OF NEOPLASMS IN FERRETS: 856 CASES (2000-2010)

A. Forlani^{*}, G. Avallone[†], S. F. Santagostino^{*}, P. Roccabianca^{*}

^{*} DIVET, School of Veterinary Medicine University of Milan, Italy and [†] Department of Veterinary Medical Sciences, University of Bologna, Italy

annalisa.forlani@unimi.it

Introduction: Ferrets are among the most common non-conventional companion animals, and seem to be particularly prone to tumor development. The aim of this study is to analyze the prevalence of neoplasms in Italian ferrets.

Materials and Methods: Biopsy samples and necropsy specimens submitted between 2000 and 2010 were included. Signalment and histopathology were retrieved from the electronic archives of the veterinary pathology service of the University of Milan. Total number of submitted samples was used to calculate the prevalence of neoplasms.

Results: A total of 908 ferret samples were received of which 688 included at least one tumor (75,77%). Ferrets with multiple neoplasms were common thus a total of 856 tumours were collected. Age ranged from 5 months to 10 years. F/M ratio was 0,99. Endocrine (63,8%), integumentary (14,7%) and hemolymphatic (8,9%) systems were most commonly affected. A higher frequency of adrenal gland (25.8%), pancreatic islet cell (24.9%), and mast cell tumors (5.8%) was evidenced. Cutaneous squamous cell carcinomas (SCC) occurred together with sebaceous gland tumors. Twenty-one abdominal spindle cell tumours with primary undefined origin were observed (2,6%).

Conclusion: Prevalence of tumors recorded in this study paralleled previous findings. The unusual association between SCC and sebaceous gland neoplasms, and the origin of intrabdominal spindle cell neoplasms should be further investigated.

Poster Abstracts

Neoplastic Disease

PP-53

AN UNSUAL CASE OF A MATURE TERATOMA ON THE LEFT PERIANAL REGION OF A YOUNG CAT

M. Taulescu*, C.A. Ober[‡], L. Oana[‡], L. Bel[‡], C. Cătoi*, L. Fărcaș*, A. Nagy*, P.C. Peștean[‡]

**Department of Pathology and [‡]Department of Anesthesiology and Surgery, Faculty of Veterinary Medicine, University of Agricultural Sciences and Veterinary Medicine, Cluj-Napoca, Romania*

taulescumarian@yahoo.com

Introduction: Teratomas contain elements that originate from more than one germ-cell layer, and are mostly found in the gonads. The aim of this study was to evaluate the histological and immunohistochemical features of a mature teratoma from the perianal region of a young cat.

Materials and Methods: A 10-month-old uncastrated male cat with a clinical history of a large mass in the left perianal area was submitted to the surgery department. After surgical excision, gross, histological and immunohistochemical exams of the mass were performed.

Results: Gross inspection showed a large cystic mass. On cut section, a multinodular, red to gray mass, measuring 4x3x3cm, was observed. An area with several black hairs was present on the surface of the mass. Microscopically, the mass showed a mixed structure consisting of skin and appendages, adipose tissue, woven bone, smooth muscle tissue, several serous glands lined by columnar epithelium and pseudostratified ciliated epithelium. The cells were immunostained by pancytokeratin, vimentin, α -actin and bone morphogenetic protein-2 (BMP) antibodies.

Conclusions: Based on gross, histological and immunohistochemical features, the definitive diagnosis of the tumor was mature teratoma. A perianal location has not been previously reported in the cat.

Poster Abstracts

Neoplastic Disease

PP-54

EXPRESSION OF CD117 AND C-KIT MUTATIONS IN CANINE CUTANEOUS MAST CELL TUMORS

I. Vucicevic, M. Vucicevic, Z. Stanimirovic, J. Stevanovic and S. Aleksic-Kovacevic

Faculty of Veterinary Medicine, University of Belgrade, Serbia

ivanav@vet.bg.ac.rs

Introduction: The pattern of CD117 expression and c-kit proto-oncogene mutations may be important for classification of mastocytomas. Both membrane-associated and cytoplasmic CD117 expression can be demonstrated in mastocytomas. The presence of cytoplasmic labeling for CD117 as well as mutations in c-kit proto-oncogene indicate a poor prognosis.

Materials and Methods: Twenty four cutaneous mastocytomas and 6 control specimens from 30 dogs of different age, breed and sex were included in this study. Formalin fixed and paraffin embedded tissue samples were stained with hematoxylin-eosin and immunohistochemically tested for CD117 expression. DNA was extracted from the same paraffin blocks and subsequent polymerase chain reaction amplification was performed using PE1 and PE2 primers. Classification according to the degree of malignancy was made based on the presence of mitotic figures, multinucleated cells, bizarre nuclei in 10 high-power fields, taking into account the pattern of CD117 expression.

Results: Fourteen of 24 mastocytomas were histologically low-grade, while ten were histologically high-grade, out of which 7 mastocytomas showed diffuse cytoplasm labeling for CD117. In all 14 low-grade mastocytomas only the membrane expression of CD117 was present. Mutations of c-kit proto-oncogene were not detected in any of the tested mastocytomas, except in the positive control.

Conclusions: Most of the high-grade mastocytomas expressed CD117 in the cytoplasm which supports the link between the aberrant expression of CD117 and increased tumour grade.

Poster Abstracts

Neoplastic Disease

PP-55

MESENCHYMAL GASTROINTESTINAL TUMORS IN CATS

S. Nesic, I. Vucicevic, V. Kukolj and M. Jovanovic

Faculty of veterinary medicine, University of Belgrade, Serbia

milijan@vet.bg.ac.rs

Introduction: Primary mesenchymal nonlymphoid gastrointestinal tumors are rare in cats. Some express CD117 (KIT) antigen and are recognized as gastrointestinal stromal tumors (GIST), but others need further classification based on their histological pattern and immunohistochemical characteristics.

Materials and Methods: An endoscopic biopsy from the stomach of a European female cat (case no 1) and a surgical specimen of the small intestine from another European male cat (case no 2) were submitted for histopathology. Tissues were fixed in 10 % formalin, embedded in paraffin, sectioned and stained with HE. Immunohistochemistry was performed on selected sections with antibodies against vimentin, α -smooth muscle actin (α -SMA), S-100 protein and CD 117.

Results: The biopsy from case 1 was composed of numerous densely arranged spindle cells forming a storiform pattern. Cells were positive for vimentin and S-100 protein but negative for CD 117 and α -SMA. In case 2 a storiform pattern of the tumor was less obvious, and the neoplastic cells were spindle to polygonal with vesiculated nuclei and prominent nucleoli. Few mitotic figures were seen. Immunohistochemistry was positive for α -SMA and negative for S-100 protein, vimentin and CD 117.

Conclusions: Both tumors had a storiform pattern but polymorphism of tumor cells in case 1 was much more prominent. According to immunohistochemistry, case 1 showed neural differentiation while case 2 had myogenic origin. Our diagnosis was peripheral nerve sheath tumor (case 1) and leiomyosarcoma (case 2).

Poster Abstracts

Neoplastic Disease

PP-56

A CASE OF A GINGIVAL FELINE SARCOID IN A YOUNG CAT

Brandes Kristin¹, Lendl Christine², Teifke Jens Peter³

¹Animal Pathology Augsburg, Germany, ²Veterinarian Practice, Gut Lichtenberg, Scheuring, Germany ³Federal Research Institute for Animal Health, Greifswald - Insel Riems, Germany

tierpatho.augsburg@gmx.de

Introduction: Fibroblastic proliferations induced by papillomavirus are well documented in the skin of horses. Similar lesions have also been described on the skin of the head in young cats, with a median age of approximately 12 months. This case describes an unusually extensive gingival fibroblastic proliferation of the upper jaw in a young cat.

Materials and Methods: A 9-month-old, intact male, european short hair cat presented with extensive neoplastic proliferation of the gingiva which completely covered all incisors within the upper jaw. The cat had a normal appetite, ate without difficulty, and was in good general condition. The mass was surgically removed, processed for histopathological examination, and samples were submitted for PCR analysis.

Results: Histopathology revealed a nonencapsulated, poorly demarcated neoplastic mass composed of spindle cells arranged in whorls abutting the mucosal epithelium. The overlying mucosa was hyperplastic and demonstrated rete ridge formation. Papillomavirus was detected by PCR.

Discussion: A diagnosis of feline sarcoïd was made based on pathohistological features and PCR results. Other inflammatory or neoplastic lesions were ruled out by histological examination.

Poster Abstracts

Neoplastic Disease

PP-57

ARTERIAL EMBOLISATION WITH DEGRADABLE MICROSPHERES IN THE TREATMENT OF HUMAN UTERINE MYOMAS AND METASTATIC DISEASE: SHEEP AS AN ANIMAL MODEL

E. Karlstam*, J. Bengtsson", W. Cwikiel" and D. Gavier-Widen*

**Department of Pathology and Wildlife Diseases, National Veterinary Institute, Uppsala, Sweden, "Center for Medical Imaging and Physiology, Skånes University Hospital, Lund, Sweden*

erika.karlstam@sva.se

Introduction: Arterial embolisation with plain or cytostatica-loaded calibrated microspheres, to achieve ischemia of tumours and local delivery of potent drugs, is currently used in human medicine. Only non-degradable microspheres, causing permanent vessel occlusion, are commercially available. The purpose of this study was to test degradable microspheres, potentially allowing complete restitution of the vessels, in the sheep model.

Materials and Methods: Seven adult female sheep were used in a pilot study. Under general anaesthesia, arteria uterina was unilaterally embolised with degradable microspheres (from Magle AB, Life Sciences, Kristianstad, Sweden) measuring 500-700 µm until stagnant flow. Sheep were euthanized one to sixty-five hours after embolisation. Samples from the uterus, ovaries and inner organs were fixed in formalin, processed, cut and stained with H&E and PAS.

Results: Intra-arterial microspheres and neutrophilic arteritis were detected in the endo- and myometrium in all but one sheep. Mild degeneration to severe ischemic necrosis of the endo- and myometrium was also seen.

Conclusion: Embolisation of the arteria uterina in sheep with degradable microspheres causes ischemic necrosis of the uterine wall, and neutrophilic vasculitis in arteries of the endo- and myometrium. The long term effects of this type of embolisation will be addressed in a forthcoming study.

Poster Abstracts

Neoplastic Disease

PP-58

COMPACT CELLULAR (SOLID) CARCINOMA CONTAINING HURTHLE CELL AREAS IN THE THYROID GLAND OF A DOG

A Gulcubuk¹, O. Erdogan¹, E.R. Bozkurt², .A. Gurel¹, M. N. Arikan³, H. Cat⁴

¹Department of Pathology, ³Department of Surgery, Veterinary Faculty, Istanbul University, 34320 Avcilar-Istanbul, TURKEY

²Department of Pathology, Istanbul Educational and Research Hospital, Ministry of Health, 34098 Kocamustafapasa-Istanbul, TURKEY

⁴Department of Internal Medicine, German Hospital Istanbul, 34433 Beyoglu-Istanbul, TURKEY

gulcu@istanbul.edu.tr

Introduction: Thyroid tumors are known to constitute 1.2-3.8% of all tumors in dogs. Oncocytic or oxyphilic cells, called as Hurthle cells, are large, polygonal cells originating from metaplastic transformation of mature glandular or non-glandular epithelial cells. While oncocytic cell tumors originating from thyroid (Hurthle) are frequently seen in human, compact cellular (solid) carcinoma with Hurthle cells are rarely encountered in dogs.

Materials and Methods: A 7-year-old, Collie dog was referred to the clinics of our faculty with a complaint of swelling in the neck. Two separate masses, located at the upper and median 1/3 parts of the neck were detected at physical examination and were surgically removed. Grossly, encapsulated solid masses (4x3x2cm and 2x1x1cm) with lobulated, haemorrhagic and greyish-white cut surfaces were detected.

Results: Histological examination revealed wide, eosinophilic polygonal cells with tiny cytoplasmic granules and centrally localized prominent nuclei. Smaller cells forming insular structures along with cell clusters that constituted fuciform bundles were observed, as well. In some fields, follicles containing colloid matrix were remarkable. Neoplastic cells were infiltrated to the capsule and to the vessels in the capsule at several sites. No positive fields were detected in PAS and Kongo red stain. Immunohistochemical evaluation of thyroglobulin, calcitonin and chromogranin showed negative marking for thyroglobulin and chromogranin and rare and weak positive staining was detected for calcitonin.

Conclusion: The masses were diagnosed as follicular compact cellular carcinoma containing Hurthle cell areas.



Poster Abstracts

Neoplastic Disease

PP-59

THE IN VITRO EFFECT OF TIN DERIVATIVES ON THE CELL LINES OF CANINE OSTEOSARCOMA (D-17), B-CELL LYMPHOMA (CL-1) AND T-CELL LEUKAEMIA (GL-1)

D. Poradowski, H. Pruchnik [□], A. Pawlak, R. Ciaputa*, M. Kandefer-Gola*, J. Bąkowska[‡], B. Obmińska-Mrukowicz, K. Kubiak[‡]

*Department of Biochemistry, Pharmacology and Toxicology, Division of Pharmacology and Toxicology [□]
Department of Physics and Biophysics *Department of Pathology, Division of Pathomorphology and Veterinary
Forensic, [‡]Department of Internal Medicine and Clinic of Diseases of Horses, Dogs and Cats, University of
Environmental and Life Sciences, Wrocław, Poland*

dominik.poradowski@gmail.com

Introduction: Tin compounds have a potential cytotoxic effect. The aim of the study was to determine how they affect the neoplasms most commonly diagnosed in dogs.

Materials and Methods: Cytotoxicity was evaluated for three tin compounds (Sn10A2, Sn11A, Sn10A) with the MTT test. The tested cell lines were exposed to the compounds for a period of 72 hours. The tested compounds were used at the following concentrations: 1, 0.5, 0.1, 0.05, 0.01, 0.005, 0.001 nM / ml.

Results: In relation to osteosarcoma cell line inhibitory concentrations (IC50) for Sn10A2, Sn11 and Sn10 were respectively 0.14±0.09, 0.13±0.02 and 0.25±0.03 nM/ml. With respect to B-cell lymphoma cells IC50 for Sn10A2, Sn11A and Sn10A were respectively 0.36±0.10, 0.43±0.11 and 0.81±0.17 nM/ml, whereas in relation to T-cell leukemia cells IC50 were respectively 0.20±0.07, 0.39±0.06 and 0.32±0.02 nM/ml.

Conclusion: The tested compounds, depending on its chemical structure and the tumour type, to varying degrees inhibited the proliferation. The results are promising due to the very low IC50 values.

Poster Abstracts

Neoplastic Disease

PP-60

THE EFFECT OF PIROXICAM, ETODOLAC, AND FLUNIXIN ON THE CELL LINE OF CANINE OSTEOSARCOMA (D-17)

D. Poradowski, B. Obmińska-Mrukowicz, A. Pawlak, R. Ciaputa*, M. Kandefer-Gola*, J. Bąkowska[‡], K. Kubiak[‡]

Department of Biochemistry, Pharmacology and Toxicology, Division of Pharmacology and Toxicology

**Department of Pathology, Division of Pathomorphology and Veterinary Forensic, [‡]Department of Internal Medicine and Clinic of Diseases of Horses, Dogs and Cats, University of Environmental and Life Sciences, Wrocław, Poland*

dominik.poradowski@gmail.com

Introduction: Nonsteroidal anti-inflammatory drugs (NSAIDs) cause inhibition of the activity of cyclooxygenase-2 and reduced secretion of prostaglandins. This property may be useful in cancer therapy.

Materials and Methods: The cytotoxicity of the NSAIDs was determined with the MTT test. The tested cell line was exposed to the NSAIDs for a period of 72 hours. The tested drugs were used in the following concentrations: piroxicam -100, 50, 20, 10, 5, 1, 0.5, 0.1 µg/ml, flunixin and etodolac 20, 10, 5, 1, 0.5, 0.1, 0.05 µg/ml.

Results: Flunixin most strongly inhibited the proliferation of the osteosarcoma cell line at concentrations of 20 and 10 µg/ml, respectively $18.5 \pm 10.4\%$ and $15.15 \pm 7.4\%$. Etodolac at the highest tested concentrations of 20 and 10 µg/ml provoked a slight stimulation of tumour cell proliferation (respectively $12.50 \pm 4.88\%$ and $8.86 \pm 4.08\%$). A similar effect was also observed at the highest concentrations of piroxicam 100 and 50 µg/ml, where cell proliferation was respectively 9.75 ± 4.05 and $21.29 \pm 5.68\%$.

Conclusion: In vitro, only flunixin inhibited proliferation of osteosarcoma cell in a dose-dependent manner. However, etodolac and piroxicam intensified, in varying degrees, tumour cell proliferation.

Poster Abstracts

Neoplastic Disease

PP-61

THE COMPARISON OF THE EXPRESSION OF THE CELL PROLIFERATION MARKERS MINICHROMOSOME MAINTENANCE PROTEIN 3 AND 7 (MCM3, MCM7) IN CANINE OSTEOSARCOMA

R. Ciaputa*, M. Kandefer-Gola*, M. Nowak*, J. A. Madej*, D. Poradowski†, J. Bąkowska‡, K. Kubiak‡

Department of Pathology, Division of Pathomorphology and Veterinary Forensic, †Department of Biochemistry, Pharmacology and Toxicology, Division of Pharmacology and Toxicology, ‡Department of Internal Medicine and Clinic of Diseases of Horses, Dogs and Cats, **University of Environmental and Life Sciences, Wrocław, Poland*

rafal.ciaputa@up.wroc.pl

Introduction: Osteosarcoma is a mesenchymal tumor belonging to the primary bone cancers. It is the most frequently diagnosed bone cancer in dogs, but in relation to all canine cancers its occurrence is rare. The aim of the study was to demonstrate and compare the expression of the cell proliferation markers - MCM3 and MCM7.

Materials and Methods: Representative samples of neoplastic tissue were fixed in 7% formalin, subjected to decalcification, then transferred to paraffin blocks and sectioned at 4µm. Immunohistochemistry was performed using Monoclonal Mouse Anti-Human MCM3 and MCM7 by DAKO.

Results: In the immunohistochemical analyzes, the strong expression of MCM3 was observed (85% of the cells revealed a positive nuclear reaction) and as high level of MCM7 (75% of the cells revealed a positive nuclear reaction).

Conclusion: The results indicate a high mitotic potential and therefore considerable aggressiveness of osteosarcoma. Both cell proliferation markers demonstrate strong expression in the malignant cells, and thus they may be useful in the diagnosis and assessment of the aggressiveness of the lesions.

Poster Abstracts

Neoplastic Disease

PP-62

CALRETININ EXPRESSION IN THE TUMORS OF LEYDIG CELLS IN TESTICLES – A COMPARATIVE STUDY IN DOGS AND MALES

R. Ciaputa^{*}, M. Kandefer-Gola^{*}, M. Nowak^{*}, J. A. Madej^{*}, D. Poradowski[†], J. Bąkowska[‡], K. Kubiak[‡] and E. Górzyńska^{**}

**Department of Pathology, Division of Pathomorphology and Veterinary Forensic, †Department of Biochemistry, Pharmacology and Toxicology, Division of Pharmacology and Toxicology, ‡Department of Internal Medicine and Clinic of Diseases of Horses, Dogs and Cats, University of Environmental and Life Sciences, Wrocław, ** Histopathological laboratory HistMed N.Z. s.c. M. Kosiński P. Prajs, Wrocław, Poland*

rafal.ciaputa@up.wroc.pl

Introduction: One of the most common groups of cancers in male dogs are testicular tumors, in particular seminoma, Leydig cell tumour and Sertoli cell tumour. The aim of this study was to demonstrate the expression of calretinin in testicular tumors in dogs by comparison to men.

Materials and Methods: Samples of testicular tumours from dogs and people were fixed in 7% formalin, then processed to paraffin wax and sectioned at 4µm. Immunohistochemistry was performed using Monoclonal Anti-Human Calretinin by DAKO.

Results: Calretinin showed strong cytoplasmic expression in neoplastic Leydig cells, with a score of 8 - 10 points according to the Remmele scale. Results were similar in canine and human tumours.

Conclusions: Similar expression results of the tested marker in dogs and men make it possible to use Leydig cell tumours in dogs as a model for the disease in men.

Poster Abstracts

Neoplastic Disease

PP-63

EXPRESSION OF Ki-67 IN CANINE CIRCUMANAL GLAND TUMORS AND NORMAL CIRCUMANAL GLAND

I.C. Šošćarić – Zuckermann*, A. Gudan Kurilj*, K. Severin**, B. Artuković*, A. Beck*, M. Hohšteter*, L. Medven*, D. Huber* and Ž. Grabarević*

*Department of Veterinary Pathology, **Department of Forensic and Judicial Veterinary Medicine, Veterinary Faculty, University of Zagreb, Croatia

isostaric@vef.hr

Introduction: Circumanal gland (CG) tumours comprise a group of common canine skin tumours that arise from the modified sebaceous glands located in the dermis of cutaneous zone of anus. The aim of this study was to detect the proliferating capacity of these tumours using Ki-67 immunohistochemical (IHC) marker.

Materials and Methods: A total of 64 samples (10 normal circumanal glands, 15 CG adenomas, 11 CG epitheliomas, 21 well differentiated CG carcinomas and 7 poorly differentiated carcinomas) were analysed using Ki-67 IHC marker (MIB-1, Dako).

Results: Average values of Ki-67 expressions within cells were as follows: normal CG – 5.7%; CG adenomas – 4.9%; CG epitheliomas – 14.4%; well differentiated CG carcinomas – 16.4%; poorly differentiated CG carcinomas – 20.8%. Significant differences between these values were spotted between normal CG and either well differentiated or poorly differentiated carcinomas ($p < 0.01$); between CG adenomas and CG epitheliomas ($p < 0.05$); between CG adenomas and either well differentiated or poorly differentiated carcinomas ($p < 0.01$).

Conclusions: The results show overall quite low Ki-67 proliferation index (PI) of these tumours. The PI values of CG epitheliomas, well differentiated CG carcinomas and poorly differentiated CG carcinomas are comparable. However, there are significant differences between malignant variants of these tumours and normal CG or CG adenoma.

Poster Abstracts

Neoplastic Disease

PP-64

BILATERAL CRYPTORCHIDISM, SEMINOMA AND SERTOLI CELL TUMOR ASSOCIATED WITH CRANIOPHARYNGIOMA AND DIABETES INSIPIDUS IN A DOG

P, Bolfa*, S. Niculescu†, A. Tomuta†, F. Tabaran*, A. Nagy*, R. Vidrighinescu*, A. Irimie* and C. Catoi*

**Pathology Department, University of Agricultural Sciences and Veterinary Medicine, Cluj-Napoca, Romania and † Veterinary Clinic Vetcon, Sibiu, Romania; pompei.bolfa@usamvcluj.ro*

pompei.bolfa@usamvcluj.ro

Introduction: Both in humans and dogs it is not infrequent for testicular tumors to coexist in cases of cryptorchidism. However, they have not been associated with craniopharyngiomas (intracranial germ cell tumors) so far.

Materials and Methods: An 11 year-old, male Poodle dog was presented with polyuria, polydipsia, diabetes insipidus, diffuse symmetrical alopecia, phlebectasia, thinning and decreased elasticity of the skin and bilateral cryptorchidism. Both testicles were surgically removed and examined histologically (H&E) histochemically (PAS and Oil Red-O) and immunohistochemically (neuron-specific enolase-NSE and vimentin). An MRI of the head was also performed.

Results: In the left testicle (size 8.0x5.2x3.2cm) we diagnosed a classical seminoma (PAS positive, vimentin positive but NSE negative) while in the right one (size 3.0x2.0x2.0cm) both a classical seminoma and an intratubular Sertoli cell tumor (Oil Red-O positive, vimentin and NSE positive) were observed microscopically. MRI examination detected a mass of about 18/16 mm at the base of the encephalus, compressing adjacent structures. This appearance suggests an extra-axial tumor, most probably a craniopharyngioma.

Conclusions: To the authors' knowledge this is the first case of craniopharyngioma associated with multiple testicular neoplasms in dogs. Although benign, the intracranial tumor was probably responsible for the broad range of clinical signs.

Poster Abstracts

Neoplastic Disease

PP-65

IMMUNOPHENOTYPE OF NEOPLASTIC AND BYSTANDER CELLS IN CANINE CUTANEOUS MAST CELL TUMOURS (CCMCT)

I. Otrocka-Domagala, K. Paździor, M. Gesek, M. Mikiewicz, T. Rotkiewicz

Department of Pathological Anatomy, Faculty of Veterinary Medicine, University of Warmia and Mazury in Olsztyn, Poland

i.otrocka-domagala@uwm.edu.pl

Introduction: Canine cutaneous mast cell tumours are common, potentially malignant neoplasms, classified into grade I - well differentiated, grade II - intermediate and grade III - poorly differentiated. In most cases mast cells are accompanied by numerous bystander cells. Appropriate tumour diagnosis and grading is crucial for successful therapy. The aim of the research was to evaluate the immunophenotype of neoplastic mast cells and bystander cells in CCMCT.

Materials and Methods: CCMCT samples were collected from eight dogs, fixed in 10% buffered formalin and processed routinely. Histological diagnosis and grading was based on sections stained with HE and toluidine blue to visualize metachromatic granules. The expression of MHCII, CD18, CD3, CD79 α cy and E-cadherin was detected immunohistochemically.

Results and Discussion: The neoplastic mast cells were E-cadherin+, CD3- and MHCII-. In most cases mast cells cross-reacted with CD79 α cy. The CD18 expression was variable. The bystander cells sometimes outnumbered tumour cells and were represented by eosinophils (CD18+), neutrophils (CD18+), lymphocytes T (CD3+, MHCII+), lymphocytes B (CD79 α cy+, MHCII+), plasma cells (CD79 α cy+; MHCII+) and fibrocytes (MHCII+). The immunophenotype of neoplastic and bystander cells in CCMCT is useful in differential diagnosis especially in poorly differentiated types lacking metachromatic granules. CD79 α cy cross-reactivity of mast cells could be a diagnostic difficulty in distinguishing poorly differentiated CCMCT from B-cell neoplasms.

Poster Abstracts

Neoplastic Disease

PP-66

CONGENITAL CARDIAC RHADOMYOSARCOMA IN A CALF

I. Otrocka-Domagala, W. Rękawek, K. Paździor, M. Gesek, M. Mikiewicz, T Rotkiewicz

Faculty of Veterinary Medicine, University of Warmia and Mazury in Olsztyn, Poland

i.otrocka-domagala@uwm.edu.pl

Introduction: Embryonal rhabdomyosarcoma (EmbRMS) is a malignant tumour derived from primitive myogenic cells. It has been reported in dogs, a cat, sheep and a lamb, mostly in skeletal muscles. Two main variants of EmbRMS were recognized, the first composed of well-differentiated rhabdomyoblasts; the second consisting of cells resembling myotubes. Tumours with mixed cell populations were also described.

Materials and Methods: A 3-month-old female Simmental calf died with clinical signs of heart failure. The necropsy examination revealed in the heart apex the presence of whitish masses infiltrating the muscle of both ventricles and interventricular septum.

Results: Histologically, the tumour was non-encapsulated and infiltrative, composed of round, oval and spindle-shaped myoblasts-like cells, with varying amounts of cytoplasm and marked anisokaryosis, arranged in long fascicles. The chromatin was granular and prominent nucleoli were observed. Elongated cells with one or a few eccentrically-located nuclei were sporadically present. Mitotic figures, sometimes bizarre, were identified (0-3). The cytoplasm of the tumour cells was glycogen-rich, showed weak to moderate desmin, strong vimentin and SMA negative reactivity. PCNA expression was observed in many neoplastic cells.

Conclusions: Based on the histological features of the neoplastic cells and immunohistochemical results, especially moderate desmin and strong vimentin expression, the neoplasm was diagnosed as embryonal rhabdomyosarcoma. To our knowledge this is the first report of primary cardiac EmbRMS in a calf.

Poster Abstracts

Neoplastic Disease

PP-67

SPONTANEOUS MALIGNANT PHEOCHROMOCYTOMA IN A SLOW LORIS (NYCTICEBUS COUCANG)

James Mount, Ricardo Feinstein, Dolores Gavier-Widén

National Veterinary Institute, Department of Pathology and Wildlife Diseases, Uppsala, Sweden

james.mount@sva.se

Introduction: Pheochromocytomas are rare tumors of the adrenal gland in primates. Pheochromocytomas are derived from chromaffin cells and usually benign, however, with potential for metastasis. Here we report a spontaneous case of malignant pheochromocytoma with metastasis to distant organs in a slow loris.

Materials and Methods: A 15 year old male slow loris from a zoo had showed signs of weakness and lethargy for a few days. Staggering behaviour, vomiting and poor appetite developed subsequently. The clinical course was progressive and the animal eventually died. Gross and microscopic examinations were performed.

Results: The slow loris was in poor condition and also icteric. At necropsy the left adrenal gland was markedly enlarged and there were multiple, well circumscribed yellow coloured masses in both lungs and liver. Histological examination of the adrenal gland revealed loss of normal architecture due to widespread infiltration of atypical polygonal cells arranged in nests. Cells had a high degree of pleomorphism and a high mitotic index. The masses in the lungs and liver showed similar histological features with additional areas of haemorrhage and necrosis.

Discussion and Conclusion: On the basis of histopathology findings, malignant pheochromocytoma was diagnosed. Fewer than 25 cases of pheochromocytoma in nonhuman primates have been described in the literature. To the authors' knowledge, this is the first official reported case in a slow loris.

Poster Abstracts

Neoplastic Disease

PP-68

LINGUAL INTRAEPITHELIAL CARCINOMA IN A CAT

I. Babińska, I. Otrocka-Domagala, I. Borkowska*

*Faculty of Veterinary Medicine, University of Warmia and Mazury in Olsztyn, Poland, * Private Veterinary Practice "Medican", Olsztyn, Poland*

Izabella.Babinska@uwm.edu.pl

Introduction: Diabetes mellitus may increase the risk of oral cancer. Intraepithelial carcinoma is a preinvasive form of neoplasm that has a high probability of progression into invasive tumour. Intraepithelial neoplasia can develop from epithelial dysplasia through carcinoma in situ, to invasive squamous cell carcinoma (SCC).

Materials and Method: A 12.5-year-old female neutered diabetic domestic shorthair cat presented with a history of oral pain and reluctance to eat. Clinical examination revealed two firm excrescences, located on the ventral surface of the tongue and enlargement of the retropharyngeal lymph nodes. Hematology was within the reference range. Plasma biochemical parameters (glucose, AST, ALT, AP, BUN, CREA) were increased. A punch biopsy of the lesion was collected. Formalin-fixed, paraffin-embedded tissue sections were HE stained.

Results: Histopathological examination revealed small, round neoplastic cells originated from tongue epithelium, lying on the basement membrane. Mitotic figures were identified. The overlying connective tissue was swollen and inflamed.

Conclusions: Based on the histopathological findings intraepithelial carcinoma was diagnosed. During two weeks after punch biopsy, rapid growth of the lesion was noticed. In human, the association of diabetes mellitus with malignancy has been established in some types of cancer including oral carcinoma. Insulin deficiency, through cytoskeleton changes and reducing cell adhesion, is considered to be an initial step towards neoplasia.

Poster Abstracts

Neoplastic Disease

PP-69

MAMMARY TUMOR METASTASIS IN THE FEMUR OF A DOG: A CASE REPORT

A. Alvarenga da Rocha^{*}, J. Madalena da Silva[†], M.C.R Luvizzoto[†], G. Fabrino Machado[†]

^{*}UFF - Universidade Federal Fluminense, College of Veterinary Medicine, Rio de Janeiro, Brazil

[†]São Paulo State University (UNESP), College of Veterinary Medicine, Laboratory of Applied Pathology, Araçatuba-SP, Brazil

aaline.vet@hotmail.com

Introduction: Malignant mammary tumors often metastasize into local lymph nodes and lungs, and less frequently into other organs. The purpose of this study was to report a case of bone metastasis of a mammary carcinoma in a dog that exhibited pain and lameness.

Materials and Methods: A 6-year-old female, Poodle dog was referred to the veterinary hospital, showing a mass in the inguinal mammary diagnosed as mammary adenocarcinoma with lymph node invasion. Seven months later, the same dog presented with lameness. On radiographic examination, a small spot of bone lysis in the upper extremity of the left femur was observed and a high amputation was performed.

Results: On microscopic analysis, roundish cells with anisokaryosis, anisocytosis, scant cytoplasm, prominent nucleoli (up to 3) and mitotic figures (up to 3 in per x40 field). Based on histopathologic examination and previous clinical reports, a metastasis of mammary adenocarcinoma was the suspected diagnosis. Immunohistochemistry using anti-cytokeratin (DAKO M3515) resulted in diffuse cytoplasmic positive staining.

Conclusion: Mammary gland bone metastasis is a rare observation and could easily be overlooked or misinterpreted. Morphologic analysis suggested epithelial origin and the positivity for cytokeratin excluded primary bone neoplasms that are mostly vimentin positive.

Poster Abstracts

Neoplastic Disease

PP-70

SPLENIC MYXOID LIPOSARCOMA: DIAGNOSIS NOT STRAIGHTFORWARD

C. Zanardello*, A. Carminato*, M. Vascellari* and F. Mutinelli*

**Istituto Zooprofilattico Sperimentale delle Venezie, Legnaro (PD), Italy*

czanardello@izsvenezie.it

Introduction: Histopathology of the spleen is frequently challenging and differentiation between malignant and non-malignant lesions is not always clear-cut. The present case report describes a disseminated myxoid liposarcoma previously diagnosed as a reactive splenitis.

Materials and Methods: In December 2012, a 11 year-old retriever dog presented with haemoperitoneum underwent splenectomy. After surgery the dog completely recovered. In March 2013 the process recurred and the dog was euthanized. Spleen samples of the first surgery and post-mortem samples were collected. Samples were processed for histology and immunohistochemistry. Immunostaining for S-100 protein, vimentin, CD-18 and CD31 was performed.

Results: Histology of the spleen revealed a fibrino-haemorrhagic splenitis with the presence of reactive spindle-cells and adipose tissue. The necropsy revealed multiple nodular proliferative masses, primarily involving the peritoneum. Microscopic examination highlighted a diffuse proliferation of pleomorphic cells with cytoplasmic lipid droplets and lipoblasts set in a myxoid matrix and abundant well differentiated adipose tissue. The neoplastic cells revealed positivity for S-100 protein and vimentin and did not stain for CD-18 and CD31. A diagnosis of disseminated myxoid liposarcoma of primary splenic origin was made.

Conclusion: Primary liposarcoma of the spleen is a very rare neoplasia and few prognostic data are published. Clinicians should consider very likely the dissemination of the neoplasia in case of spleen rupture. Therefore, haemoperitoneum could worsen prognosis in case of splenic sarcomas, regardless of grading and histotype.

Poster Abstracts

Neoplastic Disease

PL-71

UNCOMMON METASTASIS OF AN OSTEOSARCOMA CAUSING CENTRAL DIABETES INSIPIDUS IN A BARSOI DOG

M. Dettwiler¹, M. Dennler², C. Kümmerle-Fraune³, S. Schäfer³, K. Hurter⁴, M. Hilbe¹

Institute of Veterinary Pathology¹, Section of Diagnostic Imaging², Small Animal Medicine³ and Surgery⁴, Vetsuisse-Faculty, Zurich University, Switzerland

m.dettwiler@access.uzh.ch

Introduction: Osteosarcoma are frequent primary bone tumours in dogs, occur mainly in large and medium-sized breeds and commonly metastasize to the lungs. We describe a case of an osteosarcoma with metastasis to the thalamic region causing central diabetes insipidus in a dog.

Materials and Methods: A 1,5-year-old male Barsoi dog presented with lameness of the left hind limb. X-ray and MRT imaging revealed a monostotic aggressive bone lesion in the proximal tibial metaphysis expanding into the epiphysis by pathologic fracture. The dog was treated conservatively. Two months later the dog presented in comatose state. Blood analysis revealed a severe hypernatremia. In MRT, a large intraaxial space-occupying lesion was found in the thalamic region. The dog was euthanized and necropsy was performed.

Results: Macroscopically, the left proximal tibial epi- and metaphysis was filled with an ill-defined, hard, beige mass. In the brain, a well-demarcated, hard, beige mass, 2.5 cm in diameter, was found above the pituitary gland compressing the surrounding neuronal tissue. Histologically, both masses comprised of infiltratively growing irregular spindeloid cells with large eccentric nuclei separated by strands of immature osteoid.

Conclusion: A sole brain metastasis of an osteosarcoma infiltrated the thalamus, hypothalamus and hypophyseal stalk, causing disruption of ADH synthesis and transport resulting in central diabetes insipidus.

Poster Abstracts

Neoplastic Disease

PL-72

A NEW APPROACH TO EVALUATE MAMMARY TUMOURS IN FEMALE SPRAGUE-DAWLEY RATS: THERMOGRAPHY

A.I. Faustino-Rocha^{*}, A. Silva[†], J. Gabriel[†], D. Talhada^{*}, A. Andrade^{*}, C.I. Teixeira-Guedes^{*}, R. Gil da Costa^{*}, R. Ferreira[‡], P.A. Oliveira^{*}, M. Ginja^{*}

^{*}Department of Veterinary Sciences, UTAD, Vila Real and [†]Faculty of Engineering, UP, Porto and [‡]Department of Chemistry, UA, Aveiro, Portugal

rmcosta@fe.up.pt

Introduction: Angiogenesis plays a crucial role in breast cancer, a common malignancy. Thermography, already accepted by the FDA for breast cancer diagnostic, provides data on tumour surface temperature, while ultrasonography evaluates tumour vascularization. This study aimed to evaluate rat mammary tumours vascularization and surface temperature ultrasonographically and thermographically.

Materials and Methods: Animal procedures were approved by the Portuguese DGAV (no.008961). At 7-weeks-old, 11 female Sprague-Dawley rats were injected with N-methyl-N-nitrosourea (50mg/Kg). Thirty-five weeks later, mammary tumours (n=16) were evaluated thermographically and ultrasonographically using Power-Doppler (PDI) and B-Flow, before sacrificing the animals. The color pixels density (CPD), reflecting blood vessel density, was determined in images obtained by both methods.

Results: Histologically, all tumours were classified as carcinomas. Tumour temperature was 32-38.6°C. PDI and B-Flow evaluation detected smaller vessels at the surface and larger vessels within the tumour, respectively. B-Flow detected higher CPDs ($p<0.05$). A negative correlation ($p<0.05$) was found between CPD (determined by PDI but not B-Flow) and the maximum temperature and thermal amplitude.

Conclusions: Tumours with an overall high CPD are also more homogeneous, with less necrotic ("cold") regions and less reactive angiogenesis in surrounding ("hot") parts, resulting in smaller thermal amplitudes and lower peak temperatures.

Poster Abstracts

Neoplastic Disease

PP-73

VASCULOGENIC MIMICRY IN CANINE AND FELINE URINARY AND INTESTINAL CARCINOMAS: SUGGESTION FOR A NEW METHOD OF DETECTION

B. Brunetti, L.V. Muscatello, G.A. Marchese, G. Avallone, C. Benazzi and G. Sarli

Department of Veterinary Medical Sciences, University of Bologna, Bologna, Italy

b.brunetti@unibo.it

Introduction: Vasculogenic Mimicry (VM) is the ability of non-endothelial neoplastic cells to form vessel-like networks. Histochemical and immunohistochemical protocols are usually applied for its detection, though electron microscopy is the gold standard. The aim of our study was to find a specific, cost-effective method for the identification of VM in carcinomas.

Materials and Methods: Seven intestinal and 5 urinary bladder canine and feline carcinomas with VM features were selected on hematoxylin and eosin (HE) sections. VM was confirmed with an innovative method (combined anti-cytokeratin AE1/AE3 immunohistochemistry, PAS and HE) and a second previously reported method (anti-Factor VIII-ra immunohistochemistry and PAS).

Results: VM was confirmed in 5/12 cases (2 intestinal and 3 urinary carcinomas): 2 cases with the first method, 2 with the second and 1 with both. In AE1/AE3-PAS-HE method, AE1/AE3 identified epithelium-dependent channels, PAS highlighted basement membranes, and eosin the erythrocytes. In FVIII-ra-PAS method, FVIII-ra negative VM-channels were lined by PAS positive basement membranes, and erythrocytes were *birefringent*.

Conclusion: VM was identified for the first time in intestinal and urinary carcinomas, suggesting that it may be under-diagnosed in animals. Furthermore, the AE1/AE3-PAS-HE method allows an easier detection of erythrocytes in cytokeratin-positive vessel-like structures, while the previously reported method can be useful in less differentiated carcinomas with weak cytokeratin expression.

Poster Abstracts

Neoplastic Disease

PP-74

ORAL SQUAMOMELANOCYTIC TUMOR IN A DOG: A UNIQUE BIPHENOTYPIC BIPHASIC CANCER

L.V. Muscatello, C. Benazzi, G. Sarli, F. Scarpa, M. Brumat* and B. Brunetti

Department of Veterinary Medical Sciences, University of Bologna, Bologna, Italy

**Veterinary practitioner*

luisaver.muscatello2@unibo.it

Introduction: Malignant melanoma is the most common oral tumor in dog, epidemiologically followed by squamous cell carcinoma (SCC). In human medicine, squamomelanocytic tumor (SMT) is a malignant cutaneous proliferation composed of closed intermingled cells of SCC and melanoma. An unusual case of canine oral cancer, characterized by the coexistence of SCC and malignant melanoma in the same neoplasm is herein reported.

Materials and Methods: A gingival multinodular neoplasm of female mix-breed 16-year-old dog was routinely processed and haematoxylin and eosin (HE)-stained. Immunohistochemistry (IHC) with antibody anti-cytokeratin AE1-AE3 and anti-Melan-A was performed.

Results: Two population of neoplastic cells were present: one of closely packed, partially pigmented, melanocytic polygonal to spindle cells and a second minor component of squamous epithelial polygonal cells, intimately intermingled with each other. IHC has proven the unique biphenotypic nature of the neoplasm. The melanocytic cells were Melan-A positive and AE1-AE3 negative, and complementarily the squamous epithelial cells were AE1-AE3 positive and Melan-A negative. Based on histopathological and IHC findings the diagnosis of SMT was achieved.

Conclusion: SMT can be considered as a new histological type of canine melanoma, a unique biphasic neoplasm, characterized by two distinct, phenotypically different, intermixed cell populations, with unknown prognosis.

Poster Abstracts

Neoplastic Disease

PL-75

EFFECTS OF MODERATE EXERCISE IN AN ANIMAL MODEL OF CHEMICALLY-INDUCED MAMMARY TUMOURS

C.I. Teixeira-Guedes*, A. Andrade*, D. Talhada*, A.I. Faustino-Rocha*, R.M. Gil da Costa[§], M.J. Pires^{*,†}, A. Gama*, J.A. Duarte^ψ, P.A. Oliveira^{*,†}, R. Ferreira[‡]

**Department of Veterinary Sciences, UTAD, Vila Real, §Faculty of Engineering, UP, Porto [†]Animal Sciences Centre, ICETA, UP, Porto, ^ψResearch Centre in Physical Activity, Health and Leisure, UP, Porto and [‡]Mass Spectrometry Centre, Department of Chemistry, UA, Aveiro, Portugal*

rmcosta@fe.up.pt

Introduction: Breast cancer is the most common malignancy in women. Several studies suggest that physical exercise has a beneficial effect in breast cancer risk and progression. This study aims to evaluate the effects of moderate physical exercise on tumour development and inflammation in an animal model.

Materials and Methods: Animal procedures were approved by the Portuguese DGAV (no.008961). Mammary tumours were induced by i.p. administration of N-methyl-N-nitrosourea (MNU) (50mg/Kg). Sprague-Dawley rats were divided into: sedentary control, sedentary MNU, exercised control and exercised MNU. Exercised animals were trained in a treadmill during 8 months. At the end of experimental protocol animals were sacrificed, tumours were counted and histologically classified. Serum samples were collected to quantify interleukin-6 (IL-6) and C-reactive protein (CRP) by immunoblotting.

Results: The total number of mammary lesions was lower in exercised MNU (n=21) compared with sedentary MNU (n=28) group. The sedentary MNU group showed more malignant tumours, namely comedo invasive carcinoma. Physical exercise reduced the IL-6 and CRP levels.

Conclusions: Moderate physical exercise may have beneficial effects on mammary tumour development and anti-inflammatory potential.

Poster Abstracts

Neoplastic Disease

PL-76

A CASE OF FELINE INTESTINAL DIFFUSE LARGE B-CELL LYMPHOMA WITH ASSOCIATED MULTINUCLEATED CELLS

Samuel Sharpe*, Caroline Millins*, Elspeth Waugh*, Kirsty Dewar†, Francesco Marchesi*, Pamela Johnston*

** University of Glasgow, Glasgow, UK; †Crieff Vets Limited, Crieff, UK*

Francesco.Marchesi@glasgow.ac.uk

Introduction: Feline gastrointestinal lymphoma is characterised by a higher prevalence of B-cell lymphoma in the stomach, and a higher prevalence of T-cell lymphoma in the small intestine. We describe a case of jejunal Large B-cell Lymphoma with multinucleated cells associated with the neoplastic population.

Materials and Methods: A 3 year old, FIV/FelV negative cat presented to a veterinary clinic with weight loss and diarrhoea. A large mass in the proximal jejunum was removed and submitted for histopathology and immunohistochemistry. PCR based clonality analysis was also performed.

Results: Histopathology and immunohistochemistry supported a diagnosis of Diffuse Large B-cell Lymphoma. Additionally, a clonal immunoglobulin heavy chain gene rearrangement was detected by PCR. Scattered multinucleated cells, CD18 and MHCII positive and negative for Pax5, CD3, S100 and Mac387, were present.

Conclusions: Multinucleated cells have been previously reported in feline lymphoma, and in T-cell lymphoma induced in mice by a fusogenic strain of Murine Leukaemia Virus. They were interpreted as macrophage/dendritic cells representing a non-lymphoid target of the fusogenic effect of virus. It is not possible to draw a definitive conclusion on the significance of these multinucleated cells in the present case but believe the most likely interpretation is as non-neoplastic bystanders associated with the neoplastic lymphoid population.

Poster Abstracts

Neoplastic Disease

PL-77

HISTOLOGICAL AND IMMUNOHISTOCHEMICAL FEATURES OF MNU-INDUCED RAT MAMMARY CARCINOMAS

R. Soares-Maia^{*}, A.I. Faustino-Rocha[‡], C.I. Teixeira-Guedes[‡], J. Pinho-Oliveira[‡], A. Rema^{*}, F. Faria^{*}, M. Ginja[‡], R. Ferreira[§], R.M. Gil da Costa[†], P.A. Oliveira[‡], C. Lopes^{*}

**Abel Salazar Institute for Biomedical Sciences, University of Porto, Portugal, ‡University of Trás-os-Montes and Alto Douro, Vila Real, Portugal, §Chemistry Department, University of Aveiro, Portugal and †Faculty of Engineering, University of Porto, Porto, Portugal*

rmcosta@fe.up.pt

Introduction: N-methyl-N-nitrosurea (MNU) has long been used to induce mammary tumours in rats, providing a useful model to study mammary carcinogenesis. However, some poorly-clarified issues remain, such as the lack of a clear description of morphological patterns of tumours, and the distribution and role of oestrogen receptors (ER) during tumour progression, especially as tumours overexpressing ER show a paradoxical tendency to recur after ovariectomy.

Materials and Methods: Mammary carcinomas were induced in Sprague-Dawley rats using MNU. The tumours were characterized histologically and the distribution of smooth muscle actin and oestrogen receptors was studied immunohistochemically.

Results: All tumours presented both an epithelial and a myoepithelial component, demonstrated by immunohistochemical detection of smooth muscle actin. Tumours showed distinct histological patterns: well-differentiated papillary and adenoid areas and poorly-differentiated, solid and spindle-cell foci. ER overexpression (>75% of labelled cells vs. 0-75% in control tissue) occurred in papillary and adenoid areas, but not in solid and spindle-cell foci.

Conclusion: Poorly-differentiated tumour foci are likely to represent a more advanced, oestrogen-independent phase in cancer progression, and to constitute the basis for tumour recurrence after ovariectomy.



Poster Abstracts

Neoplastic Disease

PL-78

EVALUATION OF MNU-INDUCED MAMMARY TUMOURS IN FEMALE SPRAGUE-DAWLEY RATS BY HISTOLOGY AND CONTRAST ENHANCED ULTRASOUND

A.I. Faustino-Rocha*, D. Talhada*, A. Andrade*, C.I. Teixeira-Guedes*, R.M. Gil da Costa[§], R. Ferreira[†], A. Gama*, P.A. Oliveira^{*,‡}, M. Ginja^{*,ψ}

**Department of Veterinary Sciences, UTAD, Vila Real, §Faculty of Engineering, UP, Porto, [†]Mass Spectrometry Centre, Department of Chemistry, UA, Aveiro, [‡]Centre for the Study of Animal Sciences, ICETA, UP, Porto,*

^ψCentre for Research and Technology of Agro-Environmental and Biological Sciences, UTAD, Vila Real, Portugal

rmcosta@fe.up.pt

Introduction: Breast cancer is the most common malignancy in women. N-methyl-N-nitrosourea (MNU) is recognized to induce rat mammary tumours similar to those identified in women. The aims of this study were to evaluate MNU-induced mammary tumours in female rats histologically and using contrast-enhanced ultrasound (CEUS).

Materials and Methods: Animal procedures were approved by Portuguese DGAV (no.008961). At seven weeks of age, female Sprague-Dawley rats (n=11) were injected with MNU (50mg/Kg). At 42 weeks of age, and after ultrasonographic analysis, all animals were sacrificed and mammary tumours were collected for histological analysis. For ultrasonographic examination (n=15 tumours), the contrast agent was administered intravenously.

Results: Mammary tumours were classified as carcinomas and divided into histological types: papillary-noninvasive and cribriform-noninvasive; papillary-invasive, cribriform-invasive and comedo-invasive. The majority of carcinomas showed a centripetal enhancement order of contrast agent (93.3%) and clear margins (73.3%), regardless of their histological type.

Conclusions: Mammary tumours were characterized by a centripetal enhancement order of contrast agent and clear margins, which agrees with their encapsulation and high vascularization.



Poster Abstracts

Neoplastic Disease

PP-79

PRIMARY PULMONARY CARCINOSARCOMAS IN TWO CATS

G. Avallone*, B. Brunetti*, F. Rossi†, M. Alberti‡, S. Comastri‡, G. Sarli*.

**Department of Veterinary Medical Sciences, University of Bologna, Italy*

†Clinica Veterinaria dell'Orologio, Sasso Marconi (Bologna), Italy

‡Ospedale Veterinario I Portoni Rossi, Zola Predosa (Bologna), Italy

giancarlo.avallone@gmail.com

Introduction: Carcinosarcomas are uncommon malignant neoplasm characterized by the simultaneous presence of neoplastic epithelial and mesenchymal cells. In the cat few cases have been reported.

Materials and Methods: Two female domestic shorthaired cats, 8 and 9 year old, presented respiratory distress, underwent total body computed tomography (CT) and revealed a single pulmonary mass. Both cases underwent pulmonary lobectomy. Histology and immunohistochemistry were performed. Follow up was collected.

Results: Histology revealed a neoplasm composed by two cell populations. Cords and cystic structures of polygonal cells with moderate amount of cytoplasm and paracentral nucleus composed the first population. Highly cellular bundles of spindle cells with small amount of cytoplasm and elongated nucleus composed the second population. Polygonal cells expressed cytokeratin and thyroid transcription factor-1, while spindle cells expressed vimentin. CT excluded the thyroid origin of the neoplasm, and histological and immunohistochemical findings were consistent with primary pulmonary carcinosarcoma in both case. Case 1 developed a new pulmonary mass 4 months after surgery and was euthanized. Case 2 was free of recurrence or metastasis 3 months after surgery.

Conclusions: The concurrent evaluation of CT, histology and immunohistochemistry were pivotal in the diagnosis of feline primary pulmonary carcinosarcomas and to exclude metastatic origin of the lesions.

Poster Abstracts

Neoplastic Disease

PP-80

CHORDOMA IN THE TATRA MOUNTAIN SHEEPDOG – A CASE REPORT

M. Sobczak-Filipiak*, J. Sterna**, I. Dolka*

**Department of Pathology and Veterinary Diagnostics, **Division of Small Animal Surgery and Anesthesiology, Department of Small Animal Diseases with Clinic, Faculty of Veterinary Medicine, Warsaw University of Life Sciences; Nowoursynowska Str. 159C, 02-776 Warsaw, Poland*

malgorzata_sobczak_filipiak@sggw.pl

Introduction: Chordomas are malignant tumors arising from notochordal elements. In humans affect predominantly middle-aged males, and tend to occur at the sacrum and the cervical vertebrae. In dogs chordoma is rare.

Materials and Methods: Tatra Mountain Sheepdog, male, 5 years 9 months old with clinical signs of paresis (3 weeks) and then – plegia of the left thoracic limb. Following a neurological examination and diagnostic imaging, a surgery procedure was performed. During C5 laminectomy on the left side soft, lobulated, gelatinous, extradural mass was found. This mass was removed, then fixed and stained routinely; moreover immunohistochemical staining for cytokeratin and S-100 protein were performed. The animal was euthanatized.

Results: Histopathological examination shows lobules, separated by fibrous septa, consist of tumour cells with small nuclei; some of cells were vacuolated. They showed weak immunostaining for cytokeratin and were stain positively for S-100 protein. On the basis of histopathological and immunohistochemical findings a diagnosis of chordoma, chondroid type was made.

Discussion and Conclusion: In dogs there are only few reports of chordoma, predominantly in cervical region of the vertebrae. This case is the first case of cervical chondroid chordoma, diagnosed in the Tatra Mountain Sheepdog in Poland.

Poster Abstracts

Neoplastic Disease

PP-81

CORRELATION BETWEEN EXPRESSION OF C-KIT PROTEIN AND VON WILLEBRAND FACTOR IN THE III GRADE CANINE MASTOCYTOMA

M. Kandefer-Gola*, R. Ciaputa*, M. Nowak*, J. A. Madej*, D. Poradowski †, J. Bąkowska‡, K. Kubiak‡

**Department of Pathology, Division of Pathomorphology and Veterinary Forensic, †Department of Biochemistry, Pharmacology and Toxicology, Division of Pharmacology and Toxicology, ‡Department of Internal Medicine and Clinic of Diseases of Horses, Dogs and Cats, University of Environmental and Life Sciences, Wrocław, Poland*

malgorzata.kandefer-gola@up.wroc.pl

Introduction: It is often difficult to determine the degree of mastocytoma malignancy only on the basis of H & E staining. The aim of the study is to compare expression of a c-kit protein and Von Willebrand factor in the III grade mastocytoma.

Materials and Methods: 30 skin tumors previously classified as the III grade mastocytoma were used. Changes were sliced to 4µm sections upon which the tested antibodies were applied (Polyclonal Rabbit Anti-Human CD117, c-kit - DAKO® and Polyclonal Rabbit Anti-Human Von Willebrand Factor - DAKO®).

Results: All examined slides indicated strong expression of a c-kit protein, the average level of 8 - 10 points according to the Remmele scale. In reactions using Von Willebrand factor average expression was observed [22 vessels at a magnification of 400x].

Conclusion: Comparing the level of expression of a c-kit protein and Von Willebrand factor a positive correlation coefficient (0.53) was obtained. It can be concluded that in the III grade mastocytoma with the increase of the expression of a c-kit protein the amount of blood vessels also increases.

Poster Abstracts

Neoplastic Disease

PP-82

PRIMARY ANGIOCENTRIC/ANGIOINVASIVE T-CELL LYMPHOMA OF THE TYMPANIC BULLA IN A FELV POSITIVE CAT

S.F. Santagostino*, C.M. Mortellaro*, A. Forlani*, G. Ghisleni*, P. Roccabianca*

* DIVET-Dipartimento di Scienze Veterinarie e Sanità Pubblica, University of Milano, Italy

annalisa.forlani@unimi.it

Introduction: Reports of primary middle ear lymphoma are rare in cats and their extension to internal organs seems exceptional. A 5-year-old, neutered female, FeLV positive domestic shorthair cat was referred for stertor, dyspnoea and head-tilt. CT scan revealed soft tissue opacity inside the right tympanic bulla with bone lysis and concurrent nasopharyngeal and intracranial invasion.

Materials and Methods: Endoscopic guided biopsy samples were collected for histology and immunohistochemistry. A full necropsy was performed.

Results: Grossly, the lesion was poorly demarcated, white and soft. Cytology identified round, large, plasmacytoid neoplastic cells. Histology revealed dense sheets of round neoplastic cells often surrounding or invading vascular walls (angiocentric/angiodestructive pattern). Neoplastic cells expressed CD3 (T cell phenotype) and FeLV p27 and gp70 antigens. A middle ear angiocentric-angioinvasive T-cell lymphoma was diagnosed. Following radiation therapy, clinical conditions improved, but dysphagia recurred and the cat died suddenly. At necropsy, a soft, red mass filled the ventro-medial compartment of the tympanic bulla. Extension to the base of the skull with right piriform lobe compression was recorded. Hepatic and splenic metastases were present.

Conclusions: Diagnosis of primary middle ear tumors is often delayed since clinical signs mimic more common otologic conditions. Multiple biopsy specimens and immunohistochemistry were pivotal for the diagnosis in this case. FeLV might have been involved in tympanic lymphoma development.

Poster Abstracts

Neoplastic Disease

PP-83

CANINE TESTICULAR TUMORS: CORRELATION OF MITOTIC INDEX WITH Ki-67 EXPRESSION

G.F. Machado[†], J.M. Silva[†], G.D. Melo[†], A. Schweigert[†], J.E.S. Silva[†], F.G. Grano[†]

[†]São Paulo State University (UNESP), College of Veterinary Medicine, Laboratory of Applied Pathology, Araçatuba-SP, Brazil

giselem@fmva.unesp.br

Introduction: Primary testicular tumors are common neoplasms in older dogs. Histopathology and immunohistochemistry can provide relevant information about tumor cell proliferation, which can be useful to predict the prognosis of the patient. Therefore, this study aimed to evaluate and to compare the Ki-67 with the mitotic index in canine testicular tumors.

Materials and Methods: 24 seminomas, 12 Leydig cell tumors (LCTs) and five Sertoli cell tumors (SCTs) were included. The mitotic index was determined in 10 high-power microscopic fields (obj.40x) in hematoxylin-eosin stained tissue sections. Immunohistochemistry with the Ki-67 antibody (clone MIB-1, Dako M7240) was used to evaluate the Ki-67 positive cells by computer-assisted image analysis.

Results: Ki-67 was markedly expressed in canine seminomas (2.9%), different from LCTs (0.2%) and SCTs (0.06%) ($P<0.0001$). The mitotic index was higher in seminomas (1.05%) than in LCTs (0.20%), but no different from SCTs (0.60%) ($P=0.0036$). Comparing the Ki-67 immunoexpression with the mitotic index, a moderate positive correlation was observed in seminomas ($r=0.483$) and a perfect positive correlation in LCTs ($r=1.000$).

Conclusion: The Ki-67 index seems to be a more reliable tool to identify proliferating cells in canine testicular neoplasms than the visual identification of mitosis, leading to more accurate tumor grading.

Poster Abstracts

Neoplastic Disease

PP-84

ABERRANT EXPRESSION OF OCCLUDIN IN CANINE AND FELINE MAMMARY TUMOURS

H. Warwick, L. Pritchard, K. Smith, I. McGonnell

The Royal Veterinary College, London, United Kingdom

lpritchard@rvc.ac.uk

Introduction: Occludin is a component of tight junctions, found in both mammary epithelia and myoepithelia. Reduction in occludin expression in epithelial cells is associated with malignancy in human mammary tumours. The aim of this study was to determine the expression of occludin in canine and feline mammary tumours.

Materials and Methods: 18 canine and 19 feline mammary tumours were labelled using a specific anti-occludin antibody.

Results: Benign tumours displayed normal occludin distribution; in the apical epithelium and the basal edge of the myoepithelium. However, nuclear occludin expression was also identified in these samples. Quantification of membrane occludin labelling showed a statistically significant reduction in occludin labeling in malignant tumours. Nuclear expression was also statistically significantly higher in malignant canine tumours but not feline tumours. Examination of two mammary epithelial cell lines also showed nuclear occluding labeling that did not relate to the centromere on double labeling for gamma tubulin (centromere marker).

Conclusion: Reduction in expression of both epithelial and myoepithelial occludin correlates with malignancy, which may point to the potential for occludin to act as a prognostic marker for mammary cancers. The appearance of nuclear occludin in these tissues is a new finding and further work in both tumour samples and breast cancer epithelial cells lines is required to elucidate its function in the disease process.

Poster Abstracts

Neoplastic Disease

PP-85

OVEREXPRESSION OF CYTOKERATIN 19, ALDOLASE A AND MANGANESE SUPEROXIDE DISMUTASE IN OVINE PULMONARY ADENOCARCINOMA

A. Kycko, M. Reichert

National Veterinary Research Institute in Pulawy, Poland

anna.kycko@piwet.pulawy.pl

Introduction: Ovine pulmonary adenocarcinoma (OPA) is a transmissible lung cancer of sheep caused by jaagsiekte sheep retrovirus. The present study was intended to compare the protein profiles of neoplastic and non-neoplastic lung tissues of sheep for the identification of potential protein biomarkers of OPA.

Materials and Methods: Protein lysates obtained from frozen lung tissues of five OPA-affected sheep and four negative controls were submitted to analysis with two-dimensional electrophoresis (2DE) and mass spectrometry. Expression of proteins identified in the spots presenting the highest overexpression in OPA proteomes, was verified with immunohistochemistry (IHC).

Results: As a result of 2DE gels analysis, 14 spots showed at least 2-fold higher expression in each OPA sample compared to non-neoplastic ones. In 11 out of 14 spots more than one polypeptide was detected with mass spectrometry. The single proteins identified in 3 spots were cytokeratin 19, aldolase A and manganese superoxide dismutase. IHC staining revealed the expression of the three proteins in the cytoplasm of neoplastic cells in OPA sections, as well as in epithelial cells of bronchioles and pneumocytes type II both in non-neoplastic sections and OPA ones.

Conclusions: The proteomic methods allowed for the identification of three polypeptides being a compartment of protein expression profile of OPA. The IHC examination of other identified proteins is still required to establish more markers of the disease.

Poster Abstracts

Neoplastic Disease

PP-86

CONTINUED INVESTIGATIONS OF ETHMOIDAL TUMORS IN SWEDISH MOOSE (*ALCES ALCES*)

E. O. Ågren*, H. Uhlhorn*, J. Malmsten*, T. Mörner*, D. Gavier-Widén*

**Department of Pathology and Wildlife Diseases, National Veterinary Institute, Uppsala, Sweden*

Erik.Agren@sva.se

Introduction: Ethmoidal tumors in moose (*Alces alces*) originate from nasal mucosa adjacent to the ethmoidal bone. Tumors are sarcomas, carcinomas, or collision tumors, and typically erode surrounding tissues such as bone, but not skin or brain. Ethmoidal tumors in Swedish moose have been described since before 1915. A 1985 study described 35 cases for the period 1947-1982, all in female moose. An infective agent has been suspected, as endemic clusters of tumor cases were found also in cattle and horses in early 20th century.

Materials and Methods: This study reports ethmoidal tumors found in moose within the Swedish wildlife disease surveillance program 1983-2013.

Results: Forty-six cases of ethmoidal tumors in moose were found. The prevalence of ethmoidal tumors calculated from submitted moose samples was 1%, for both the present and the 1985 study period. Cases were in both studies most prevalent in mid-Sweden, and mean age was 10 years. The first evidence of an affected male moose was found 2013.

Conclusions: In Sweden, ethmoidal tumors have generally only been found in female moose, probably as hunting regulations protect adult females whereas few males reach old age. Ongoing studies use computer tomography for anatomic visualization and immunohistochemistry for tumor type classification. Molecular methods to screen for viruses will be used to search for a viral component of tumor genesis.

Poster Abstracts

Neoplastic Disease

PP-87

SCIATIC T-CELL NEUROLYMPHOMATOSIS IN A DOG

A. Rupp, E. Ives, H. Rudolf, A.C. Palmer, A. Williams, F. Constantino-Casas

Department of Veterinary Medicine, University of Cambridge, Cambridge, UK

afr32@cam.ac.uk

Introduction: Neurolymphomatosis is rarely reported in canines. One previous report documents B-cell infiltration of the femoral nerve, whilst other accounts predominantly focus on lymphocytic infiltrates in the cranial nerves and nerve roots.

Materials and Methods: A 4.5 year-old female cross-breed presented with a one week history of anorexia, weight loss, tenesmus, tail flaccidity and progressive monoparesis of the right hindlimb. Ultrasound imaging revealed a thickened stomach wall with loss of its normal layering and a large mass at the mesentery. MRI showed an enlargement of the right L7 spinal nerve root and thickening of the proximal aspects of the right sciatic nerve.

Results: At necropsy, multiple thickened areas were found within the gastric wall and the mesenteric lymph nodes were confluent and enlarged. The right L7 spinal nerve and the proximal areas of the right sciatic nerve were discoloured red and enlarged. Histology of stomach, lymph nodes, right L7 spinal nerve and right sciatic nerve revealed marked infiltration with sheets of CD3-positive cells (T-cell lymphoma). The spinal cord appeared free from infiltration; mild bilateral lymphocytic infiltrates, however, could also be found in more caudal spinal nerve roots.

Conclusions: Whilst the majority of human cases of neurolymphomatosis and the recently described femoral infiltration in a dog are B-cell lymphomas, the possibility of T-cell lymphoma should also be considered in cases of peripheral nerve enlargement.

Poster Abstracts

Neoplastic Disease

PP-88

IDENTIFICATION OF THE TRUNCATED FORM OF FELINE RON/STK TRANSCRIPT IN FELINE MAMMARY CARCINOMA CELL LINES

L. Maniscalco*, S. Iussich*, F. Gattino*, Y. Millán§, N. Sasaki†, T. Nakagawa†, B. Biolatti*, J. Martín de Las Mulas§, R. De Maria*

* Dep. Veterinary Sciences, University of Turin, Italy; §dep. Comparative Pathology, University of Córdoba, Spain; †dep. Veterinary Surgery, University of Tokyo, Japan

lorellamaniscalco@yahoo.it

Introduction: RON/stk is a member of the MET receptor family, over-expressed in human breast cancer and identified in cat as feline-stk. The human RON gene codifies the full length and the short length transcripts, encoding for the full-size and the truncated form of the receptor respectively. The aim of this research was to evaluate the expression of RON in feline mammary carcinomas (FMC) samples and to identify the presence of the truncated form.

Materials and Methods: immunohistochemical expression of RON was evaluated on 46 FMCs. RON was detected by western blot after immunoprecipitation on 6 FMC cell lines. To detect the truncated form of feline RON, PCR with primers annealing on exon 10 and exon 11 was performed on cDNA from FMC cell lines.

Results: the 78.26% of FMCs analysed expressed RON. The truncated form of feline RON was detected in 2/6 cell lines and the genomic sequence of introns 10 and 11 was determined.

Conclusions: In cats, as in humans, the truncated form of RON receptor is present. These data suggests that the truncated receptor may be involved progression of feline mammary carcinomas as well in other feline tumors.

Poster Abstracts

Neoplastic Disease

PP-89

N-CADHERIN EXPRESSION IN CANINE MAMMARY MALIGNANT TUMOURS

A. Santos[‡], D. Pereira[‡], J. Paredes^{*}, F. Schmitt^{*} and A. Gama[‡]

[‡]*Veterinary Sciences Dep., CECAV-UTAD, Vila Real, Portugal*

^{*}*IPATIMUP, Universidade do Porto, Porto, Portugal*

agama@utad.pt

Introduction: Cadherins are calcium-dependent cell-cell adhesion molecules, which play significant roles in many cellular events. Several studies have been focusing on the possible role of classical cadherins, in particular Epithelial (E-) cadherin, in canine mammary tumour (CMT) biopathology. The present study aimed to investigate the immunohistochemical expression of Neural (N-) cadherin in CMTs, which, to the best of our knowledge, has not been addressed.

Materials and Methods: N-cadherin expression was evaluated in 100 canine malignant mammary tumours, by using an immunohistochemical approach. Immunoreactivity was scored according to the percentage of immunopositive cells and to the staining intensity.

Results: Adjacent normal mammary glands showed no epithelial reactivity for N-cadherin, whereas there was a frequent faint to moderate epithelial cytoplasmic expression in hyperplastic mammary tissue with secretory/cystic changes. An abnormal epithelial expression of N-cadherin was found in 41 out of 100 carcinomas (41%), which was characterized by at least 10% stained cells, showing a moderate to strong staining intensity. Reactivity was predominantly cytoplasmic, although membrane staining was also observed.

Conclusions: In this study, we observed that N-cadherin overexpression is a common finding in CMTs, which suggests that this adhesion molecule might have an important role during tumour progression. In fact, recent human data indicate the proinvasive effects of N-cadherin expression, which has yet to be confirmed in this animal model.

Poster Abstracts

Neoplastic Disease

PP-90

EVALUATION OF HISTOPATHOLOGICAL GRADING, MITOTIC INDEX AND KIT STAINING PATTERNS AS PROGNOSTIC INDICATORS FOR CANINE CUTANEOUS MAST CELL TUMOURS

R. F. Strefezzi^{a,*}, J. G. Xavier[‡], S. R. Kleeb[‡], J. L. Catão-Dias[†]

** Departamento de Medicina Veterinária da Faculdade de Zootecnia e Engenharia de Alimentos and ** Departamento de Patologia da Faculdade de Medicina Veterinária e Zootecnia, Universidade de São Paulo, Brazil, and † Universidade Metodista de São Paulo, Brazil*

rstrefezzi@usp.br

Introduction: Mast cell tumours (MCTs) are the most frequent skin neoplasms in dogs. The cytoplasmic KIT-staining patterns have been associated with worse prognosis. The aim of the present work was to compare the histopathological grading system, the KIT-staining system and the mitotic index as prognostic indicators for canine cutaneous MCTs.

Materials and Methods: Twenty-four cases of canine cutaneous MCTs were selected. The tumours were graded by four pathologists with no clinical information about the cases according to the grading systems of Patnaik et al. (Vet. Pathol. 1984), Kiupel et al. (Vet. Pathol. 2004) and Romansik et al. (Vet. Pathol. 2007).

Results: KIT-staining was not associated with disease-related mortality or survival. Survival was significantly different between histopathological grades. Mitotic index and survival were correlated. Best results were obtained for histopathology, followed by MI and KIT-staining patterns as prognostic indicators.

Conclusions: KIT-immunostaining and the Mitotic Index add information to the Patnaik grading system. However, the histopathological grading system still remains as the gold standard to classify canine cutaneous MCTs until the development of a more efficient approach.

Poster Abstracts

Neoplastic Disease

PP-91

INCREASED HYPOTHALAMIC DOPAMINERGIC NEURON TYROSINE HYDROXYLASE EXPRESSION IN LEAN WISTAR RATS

Jayne Wright¹, Simon Plummer², Rolly Weigand³, Mike Millar³

¹Syngenta, United Kingdom, ²Micromatrics, United Kingdom, ³MRC Centre for Reproductive Health, United Kingdom

jayne.wright@syngenta.com

Introduction: Calorific restriction in Wistar rats has been reported to show a decrease in mammary and pituitary tumours and an increase in uterine tumours associated with delayed hypothalamic dopaminergic neuronal senescence.

Experimental Design: Hypothalamus from Formalin Fixed Paraffin Embedded (FFPE) brain blocks from 12 control and 12 lean 106 weeks old Wistar rats were evaluated, using a combination of immunostaining (IHC), RNAscopeTMTM in situ hybridisation (ISH) for Tyrosine Hydroxylase (TH) protein, TH dual fluorescence IHC/ISH, and microarray analysis following Laser Dissection. The staining was quantified by image analysis

Results: IHC staining was observed in the TIDA (Tubular Infundibular Dopaminergic) neurons, and the axonal projections onto the median eminence (ME), with stronger staining in the ME. TH RNA expression was detected predominantly in the TIDA neurons. Dual fluorescence, IHC/ISH, demonstrated coincident TH protein and TH RNA staining in some neuronal cell bodies and axons. The rats with reduced bodyweight gain showed an increase in TH RNA (TIDA) and TH protein staining in both TIDA and ME. Microarray analysis of the hypothalamus revealed downregulation of GABA B receptor, which is known to control dopamine production.

Conclusions: These results support previous observations, that chronic reduction in bodyweight gain may alter regulation of TH expression at the RNA and protein levels in the TIDA hypothalamic nuclei. They also demonstrate a possible GABA control mechanism

Impact Statement: FFPE tissue can be used to demonstrate gene expression, at the RNA and protein levels, and to explore gene pathways.

Poster Abstracts

Neoplastic Disease

PL-92

CASE REPORT: A RAT HEPATIC SCHWANNOMA

C.I. Teixeira-Guedes^{*†}, A.I. Faustino-Rocha^{*†}, D. Talhada[†], A. Andrade[†], R. Pacheco[†], R.M. Gil da Costa^ψ, J.A. Duarte[§], R. Ferreira[‡], F. Seixas[†], P.A. Oliveira[†]

*Both authors contributed equally to this work

[†]Department of Veterinary Sciences, UTAD, Vila Real, ^ψFaculty of Engineering, UP, Porto, [§]Research Centre in Physical Activity, Health and Leisure, UP, Porto and [‡]Department of Chemistry, UA, Aveiro, Portugal

rmcosta@fe.up.pt

Introduction: Schwannomas occur naturally in several body tissues, in both humans and animals, exhibiting uniform immunoreactivity for vimentin, S-100 protein and neuron-specific enolase (NSE). We describe a case of a hepatic schwannoma, found in a rat model of chemically-induced mammary cancer.

Materials and Methods: Animal procedures were approved by the Portuguese DGAV (no.008961). A female Sprague-Dawley rat was injected with N-methyl-N-nitrosourea (MNU) at seven weeks-old and died spontaneously fifteen weeks later. A complete necropsy was performed and lesions were studied histologically.

Results: On necropsy, a haemorrhagic, multicystic, well-circumscribed hepatic mass was observed. Histologically, hepatic parenchyma was replaced by a well-circumscribed mass composed of spindle-shaped cells disposed in a waving pattern, supported by a poorly-stained matrix. Large, haemorrhagic and necrotic cystic areas were multifocally present. The lesion invaded the costal wall and the diaphragm. Tumour cells displayed occasional positivity to vimentin and diffuse positivity to S-100 and NSE.

Conclusions: Macro and microscopic findings are compatible with the diagnosis of hepatic schwannoma, chemically-induced by MNU administration. Although infrequent, the occurrence of schwannomas has been described in other species, and different organs, associated with N-ethyl-N-nitrosourea and MNU exposure.

Poster Abstracts

Neoplastic Disease

PP-93

PAROTID ADENOCARCINOMA WITH OSTEOLYTIC ACTIVITY FELINE CASE REPORT

A. Calado^{*,†}, A. Duarte A^{*}, J. Pego^{*}

^{*}Faculdade de Medicina, University of Coimbra, Portugal; [†]Escola Universitária Vasco da Gama, Coimbra, Portugal

geral@euvg.pt; anacaladolopes@gmail.com

History: A 9 year-old DSH female Siamese cat presented with ataxia, right ear canal bleeding and head tilt to the right. The antibiotic treatment for otitis was non-responsive. Over a week the cat developed anorexia, tongue displacement and a right ranula, left tracheal displacement for a right consistent mass. The untreated advanced condition justified euthanasia.

Necropsy findings: On the right parotid region there was a sessile tumour, white, lobulated, friable profusely infiltrative and osteolytic. The temporal and parietal bones were absent and the tumour was in contact to the brain. Several branches extended to the tongue, regional lymph nodes and surrounding soft tissues.

Histopathological findings: The tumour and the infiltrating branches were heterogeneous with pale cells of eccentric small nucleus arranged in solid shape, pleomorphic polyhedral cells with pleomorphic dense nucleus in a papillary pattern and central necrosis. Abundant spindle cells resembling myoepithelium surrounded the basement membranes. Normal parotid gland was present adjacent to the tumour.

Diagnosis: Parotid adenocarcinoma.

Clinical Relevance: Salivary gland tumours are rare in cats. The osteolytic behaviour of salivary adenocarcinomas is not commonly reported and it should be included in the differentials of skull osteolytic conditions and on central neurological presentations.

Poster Abstracts

Neoplastic Disease

PP-94

FELINE DIFFUSE IRIS MELANOMA WITH ATYPICAL METASTATIC BEHAVIOUR

A. Calado ^{*}, T. Silva ^{*}, C. Santos ^{*}, A. C. Figueira ^{*}, J. Prada[†], I. Canavarro ^{*,&}

^{}Escola Universitária Vasco da Gama, Coimbra, Portugal, [†]Universidade de Trás-os-Montes e Alto Douro, Vila Real, Portugal and [&]Clínica Veterinária Vetpóvoa, Coimbra, Portugal*

geral@euvg.pt; anacaladolopes@gmail.com

History: A 13 year-old DSH female grey tabby cat treated surgically (enucleation) to a right eye tumour diagnosed as a feline diffuse iris melanoma (FDIM). Fourteen months later an abdominal ultrasound revealed an unidentified mass approached by laparotomy. The advanced untreatable stage of numerous pigmented lesions justified the euthanasia.

Necropsy findings: diffuse dark pigmented foci ranging from punctiform to macules were present in multiple organs and tissues: regional and distant lymph nodes, parotid, lungs, pleural fat, rib, diaphragm, mesentery, spleen, liver and pancreas.

Histopathological findings: all metastasis were composed by round neoplastic melanocytes, ranging from amelanotic to highly pigmented cells. The cells were pleomorphic, presenting vesicular nucleus with large prominent nucleoli. The supporting conjunctive stroma was sparse. Neoplastic emboli were present on peripancreatic lymphatic vessels and on lymph node sinuses.

Diagnosis: Advanced FDIM with metastasis widely disseminated.

Clinical Relevance: Advanced FDIM is a common primary intraocular tumour in old cats. The prognosis is poor despite enucleation due to the high metastatic potential. Metastases by haematogenous spread are commonly referred in the liver, kidneys and lungs. This case, in addition to the common location, reports a wider dissemination over multiple organs and tissues. Moreover, the cavitory and lymphatic spread are evident in addition to the haematogenous spread.

Poster Abstracts

Neoplastic Disease

PP-95

IMMUNE CELLS INFILTRATE FELINE ENDOMETRIAL ADENOCARCINOMAS IN THE PRESENCE OR ABSENCE OF PYOMETRA

M Tavares Pereira ^{*}, AL Saraiva ^{*,†}, A Gama ^{*}, R Payan-Carreira ^{*}, MA Pires ^{*}

^{*}CECAV-ECAV-UTAD, Vila Real

[†]EUVG, Coimbra, Portugal

agama@utad.pt

Introduction: Immune cells play important roles in tumourigenesis, through the establishment of a dynamic relationship. In cats endometrial adenocarcinomas (FEA) are commonly associated with pyometra. The aim of this study was to assess the immune cell infiltrate in FEA with or without concurrent pyometra.

Materials and Methods: We evaluated ten samples of FEA (five presenting pyometra and five without inflammation) and 10 control samples of endometrium. Indirect immunohistochemistry was performed using antibodies against macrophages (Mø), T and B cells respectively: MAC 387 (Ab-Serotec®, 1:100); CD3 (Dako®, 1:50); and CD79 (Cell Marque®, 1:50). Cells were counted in two different layers of the tumours and also in the surrounding tissues.

Results: Overall immune cell infiltration was significantly increased in tumours in comparison to controls ($P < 0.001$). T-cell presented a five-fold increase in tumours, whether pyometra co-existed or not. In contrast, B-cell numbers were slightly increased in tumours without pyometra but showed a huge increase with inflammation. Mø showed only a two-fold increase in tumours in comparison to controls; yet a 8-fold increased Mø was found in cases of co-existing pyometra.

Conclusions: The inflammatory infiltrate differed in tumours with and without pyometra. In the absence of pyometra, T-cells were the predominant population, while if pyometra was present B-cells were the major cell population.

Poster Abstracts

Neoplastic Disease

PP-96

INFLUENCE OF BLV INFECTION ON TELOMERE LENGTH AND TELOMERASE ACTIVITY IN CATTLE

M. Szczotka, J. Kuzmak, E. Iwan

National Veterinary Research Institute, Department of Biochemistry, Pulawy, Poland

szczotka@piwet.pulawy.pl

Introduction: The bovine leukemia virus (BLV) is a causative agent of bovine leukemia. The aim of the studies was determination of telomerase activity and telomere length in lymphatic organ cells. Telomerase - a telomere – synthesizing reverse transcriptase compensates the loss of telomere associated with cell division. Telomeres are important structures for the correct function and stability of chromosomes. Telomerase activity is expressed in most human tumor tissues, but not in normal tissues, except for those of the germline (ovaries/testes).

Materials and Methods: Telomerase activity was determined with the use of PCR-ELISA method in blood sera, lymphatic organ cells and dendritic cells generated from lymphatic tissues. The telomere length and fluorescence intensity was determined in interphase nuclei and metaphase spreads with the use of fluorescence *in situ* hybridization (FISH) method and by flow cytometry. Human tumor cell lines were used as positive control.

Results: Very high relative telomerase activities were found in dendritic cells, sera of cattle with lymphocytosis and in FLK-BLV cell line. The relative telomere length (RTL) was much shorter in leukemic animals.

Discussion & Conclusion: High telomerase activity and shortened telomeres almost always correlate with disease severity in lymphoproliferative disorders. Measurement of telomere length and telomerase activity might be practically useful to monitor disease condition, and as well prognostic marker and therapeutic target in therapy of tumors.

Poster Abstracts

Neoplastic Disease

PP-97

DETECTION AND QUANTIFICATION OF BPV-2 DNA IN BOVINE URINARY BLADDER LESIONS FROM THE AZORES ARCHIPELAGO - PORTUGAL

J. Cota*, A. Duarte*, T. Carvalho†, C. Pinto‡, L. Tavares*, M. C. Peleteiro*

**CIISA, Faculdade de Medicina Veterinária, Universidade Técnica de Lisboa, Portugal; †IMM, Faculdade de Medicina, Universidade de Lisboa, Portugal and ‡ Serviços de Desenvolvimento Agrário, Ponta Delgada, Portugal*

adjoaobcota@fmv.utl.pt

Introduction: Bovine papillomavirus type 2 (BPV-2) DNA has been identified in the urinary bladder (UB) from animals suffering from Bovine Enzootic Hematuria (BEH). Few reports have given information on the viral load. The aim of this study was to quantify the number of BPV-2 virions in animals slaughtered in the Azores Archipelago, a BEH endemic region.

Material s and methods: Fifty-one animals were tested using a Real Time PCR system for detection and quantification of BPV-2. Thirty-eight animals had macroscopic lesions in the UB and 13 had no lesions. The iliac lymph nodes of 35 animals were also tested.

Results: BPV-2 DNA was detected in 27 of the 38 UB with lesions (71%) and in 7 of the 13 bladder with no lesions (54%).and in 7 of the 35 lymph nodes (20%). The highest number of BPV-2 DNA copies was 4.2/cell and the lowest was 0.0002/cell, with an average value of 0.08 copies/cell.

Conclusions: This is the first report on the quantification of BPV-2 in UB lesions from animals of the Azores Archipelago, which is a step forward on the research on the role of BPV-2 in the UB carcinogenesis.

Poster Abstracts

Neoplastic Disease

PL-98

CARCINOMA IN A QUARTER HORSE INVOLVING THE OVARY WITH WIDESPREAD METASTASES

V. Saey*, T. Picavet^β, H. De Cock*, K. Chiers* and R. Ducatelle*

*Department of Pathology, Bacteriology and Avian Medicine, Faculty of Veterinary Medicine, Ghent University, Merelbeke, Belgium

^βDe Bosdreef, Animal Hospital, Moerbeke-Waas, Belgium

•Medvet – Veterinary Pathology Services, Antwerpen, Belgium

veterinaire.pathologie@ugent.be

Introduction: In mammals, ovarian carcinomas are reported only commonly in dogs and arise from the surface epithelium of the ovary or from the rete ovarii. In horses, they occur seldom. A 6-year-old Quarter mare was diagnosed during gynaecological examination with an enlarged right ovary. Laparoscopic ovariectomy was performed in November 2012. Histopathological examination showed a highly malignant carcinoma infiltrating the right ovary. The condition of the horse improved until April 2013 when she developed fever, anorexia, anemia, neutrophilia and monocytosis. Ultrasound revealed a high amount of abdominal fluid and a large, heterogeneous mass in the cranio-ventral abdomen. The mare was euthanized.

Materials and Methods: Full post-mortem examination, histology and immunohistochemistry were performed.

Results: A large, nodular, cystic mass with central necrosis was noticed in the omentum. Similar smaller masses were present in the liver, on the pleural and peritoneal surface of the diaphragm, the peritoneum and the serosa of the stomach and spleen. The remaining left ovary was normal. Histopathology of post-mortem samples revealed proliferating kuboidal cells with prominent necrosis, cellular atypia, anisocytosis and anisokaryosis forming disorganized cords and acini separated by dense collagenous stroma. On immunohistochemistry the neoplastic cells were cytokeratin positive.

Conclusion: The horse reported clinically presented with a carcinoma first noticed in one ovary. Widespread metastases were noticed abdominal. An ovarian carcinoma is suspected based on gross and histopathological examination. Currently no specific immunohistochemical markers are available for ovarium epithelium.

Poster Abstracts

Other

PP-99

IMMUNOHISTOLOGICAL IDENTIFICATION OF DISSEMINATED TUMOR CELLS IN THE LUNGS OF A MOUSE ORTHOTOPIC XENOGRAFT MODEL OF HUMAN RHABDOMYOSARCOMA

V. Castiglioni^{*§}, M. De Maglie^{*§}, S. Rodighiero^{*}, G. Cassinelli[‡], C. Lanzi[‡], E. Scanziani^{*§} and C. Recordati^{*}

**Fondazione Filarete, Milano, Italy and [§]DIVET, Facoltà di Medicina Veterinaria, Università degli Studi di Milano, Milano, Italy and [‡]Fondazione IRCCS Istituto Nazionale dei Tumori, Milano, Italy*

camilla.recordati@fondazionefilarete.com

Introduction: Murine xenografts are extensively used in the study of human malignancies. One of the major criticism of this animal model is its low metastatic potential. The aims of this study were to investigate a promising metastatic sarcoma model and develop an immunohistological method able to detect human disseminated tumor cells in murine lungs.

Materials and Methods: 7 SCID mice were injected intramuscularly with human A204 rhabdomyosarcoma cells and euthanized after 9 weeks. Standard histology, immunohistochemistry and immunofluorescence using specific anti-human Vimentin and MHC class I antibodies were used for the assessment of tumor cell dissemination in the lungs.

Results: Histological examination alone was not successful in identifying neoplastic dissemination to the lungs. Immunohistological methods enhanced the sensitivity of the analysis and both Vimentin and MHC class I allowed to appreciate either single or clustered cells of human origin within pulmonary interstitium. Both markers co-localized in the same atypical cells with double-immunofluorescence.

Conclusions: Intramuscular injection of A204 rhabdomyosarcoma cells can be regarded as a valuable metastatic orthotopic xenograft model. Immunohistological methods using specific anti-human antibodies are a reliable tool for the detection of disseminated xenografted tumor cells.



Poster Abstracts Other

PP-100

HERMAPHRODITISM AND UROLITHIASIS IN YORKSHIRE TERRIER WITH CONGENITAL EXTRAHEPATIC PORTOSYSTEMIC SHUNTS – A CASE REPORT

K. Warchulska*, M. Sobczak-Filipiak*, M. Galanty**

**Department of Pathology and Veterinary Diagnostics, **Division of Small Animal Surgery and Anesthesiology, Department of Small Animal Diseases with Clinic, Faculty of Veterinary Medicine, Warsaw University of Life Sciences; Nowoursynowska Str. 159C, 02-776 Warsaw, Poland*

karolina_warchulska@sggw.pl

Introduction: Congenital portosystemic shunts are abnormal vascular connections between the portal vein system and the systemic vein circulation, that allow blood bypassing the liver. The clinical symptoms vary, depending on the size and location of the shunt. Neurological signs predominates, gastrointestinal symptoms and urinary symptoms are reported.

Materials and Methods: Yorkshire terrier, 5 years old, female with urolithiasis.

Results: During clinical examination, os penis was found in the vulva. During laparotomy pathological vessels were diagnosed (congenital extrahepatic portosystemic shunt), and left gonad - adherent of the urinary bladder. The stone from the urinary bladder, uterus and left gonad were removed; pathological vessels were closed. Liver biopsy was performed (material was fixed and stained routinely). Histological examination of the liver revealed degeneration of hepatocytes, decreased diameter of portal veins and proliferation of arterioles and biliary ducts. The male gonad was an inactive testis and the female tubular tract was an atrophic uterus.

Discussion and Conclusion: Congenital extrahepatic shunts result from the abnormalities that occur during the development of circulation in the vitelline system. In some patients they are accompanied with urolithiasis and cryptorchidism, but hermaphroditism in conjunction with a portosystemic shunt is extremely rare diagnosis in dogs.

Poster Abstracts Other

PP-101

OBESITY-INDUCED INFLAMMATION INFLUENCE ON NEOVASCULARIZATION OF ADIPOSE TISSUE IN RATS

G. Borza*, C. Catoi*, A.F. Gal*, M. Taulescu*, P. Bolfa*, A.F. Catoi**

* University of Agricultural Sciences and Veterinary Medicine Cluj-Napoca, Romania

**University of Medicine and Pharmacy Iuliu Hatieganu Cluj-Napoca, Romania

cornel.catoi@usamvcluj.ro

Introduction: Obesity, with all its comorbidities, is recognized as a major health problem in humans. Obesity induces adipose tissue macrophage infiltration, a significant source of nitric oxide in both humans and mice. Adipose tissue macrophages seem to have an important angiogenetic effect. The aims of the present study were to determine the role of inflammation in obesity-induced neovascularization.

Materials and Methods: Twenty Whistar male rats 30 days aged were used as experimental group. To induce obesity, rats were fed with a high-caloric diet over a 30 weeks period. A control group of 20 rats was used. Blood samples for plasma inflammation markers (TNF- α , IL-6) were taken after 8 weeks and at the end of the experiment (30 weeks). Adipose tissue samples (subcutaneous, omentum and perirenal) were used for histology and immunohistochemistry (macrophages, endothelial cells, iNOS and VEGFR-2).

Results: Plasma inflammation markers and adipose tissue VEGFR-2 expression were significantly increased in obese rats. The number of macrophages was significantly increased in the omental adipose tissue in obese rats. The expression of iNOS and the number of capillaries revealed significantly increase in omental and subcutaneous adipose tissue.

Conclusions: According to our experiment, there is a direct correlation between obesity, general and local adipose inflammation, and neovascularization.

Poster Abstracts

Other

PP-102

PORCINE ULCERATIVE DERMATITIS SYNDROME IN SOWS: RESEMBLING HERPES-ASSOCIATED ERYTHEMA MULTIFORME

Ruetten M.^{*}, Buergi E.[§], Engels M.⁺, Sydler T.^{*}, Sidler X.[§], Ackermann M.⁺, Stahel A.⁺

^{*}Institute of Veterinary Pathology, Vetsuisse Faculty Zürich, Switzerland

⁺Departement of farm animals, Division of pig medicine, Vetsuisse-Faculty Zürich, Switzerland

[§]Institute of Virology, Vetsuisse-Faculty Zürich, Switzerland

Maja.ruetten@uzh.ch

Introduction: Porcine ulcerative dermatitis syndrome is an important skin disease in pigs.

Materials and Methods: Six adult German Large White sows developed during late pregnancy or weaning, severe multifocal ulcerations of the hind legs, flanks and abdomen, sparing only the teats. The histological lesions consisted of lymphocytic (T-cells), interfacial dermatitis with vesicle formation at the epidermal-dermal junctions and multifocal epidermal degeneration and apoptosis. These lesions were interpreted as erythema multiforme.

Results: Using PCR with panherpesvirus DNA polymerase gene primers and the *porcine lymphotropic Herpesvirus 1 (PLHV 1)* could be detected in the diseased skin, blood leucocytes, lymph nodes, ganglia and brain of diseased animals. All animals were negative for *porcine Circovirus 2* by immunohistochemistry. All treatment attempts with dexamethasone and antibiotics in these animals failed. In addition fourteen healthy animals were tested for *porcine lymphotropic Herpesvirus 1, 3, 4 (formerly 2)*. Six animals were as well positive for *porcine lymphotropic Herpesvirus 4*, only one animal was positive for PLHV 1.

Conclusions: These findings suggest that *PLHV 1* could be a trigger in the development of a delayed hypersensitivity reaction (erythema multiforme) in these pigs and is more likely to be one cause of porcine ulcerative dermatitis syndrome rather than *PLHV 4*, which was only found in healthy control animals.

Poster Abstracts Other

PP-103

THYMUS APOPTOSIS IN BEEF CATTLE TREATED WITH LOW DOSES OF DEXAMETHASONE: PRELIMINARY RESULTS

M. Vascellari*, C. Zanardello*, L. Gagliazzo*, W. Marchioro*, F. Mutinelli*

*Istituto Zooprofilattico Sperimentale delle Venezie, Legnaro (PD), Italy

mvascellari@izsvenezie.it

Introduction: glucocorticoids (GC) are illegally used as growth promoters in beef cattle, to enhance carcasses and meat quality traits. Ample evidence has been provided for extensive apoptosis in the CD4+CD8+ T cell subpopulation after GC treatment in adult animals, followed by thymus recovery within 14 days. The aim of this study was to evaluate thymus apoptosis in beef cattle treated with low doses of dexamethasone (DEX).

Materials and Methods: 74 beef cattle, were randomly divided in 3 groups: group A (control, n=50), group B (n=16) treated with DEX for 42 days; group C (n=8) treated with DEX and clenbuterol. Thymus samples were collected at the slaughterhouse and investigated by immunohistochemistry, using the cleaved Lamin A primary antibody. Positive cells were counted in 5 high power fields (HPF), and the mean value was considered.

Results: In group A (controls) the mean value of cleaved Lamin A positive cells ranged between 5.2 and 200, while in treated animals (group B+C) the mean value ranged between 0 and 28.4, being the apoptotic rate significantly lower in treated than in control animals ($p < 0.001$).

Conclusions: Laminins are nuclear membrane structures, specifically cleaved during apoptosis. Cleaved Lamin A, could be considered as useful biomarker of illicit treatment. However, further investigations are required to understand why the apoptotic rate fell in treated animals, and which pathway is involved in the apoptotic process.

Poster Abstracts

Other

PP-104

OBESITY-INDUCED INFLAMMATION INFLUENCE ON NEOVASCULARIZATION OF ADIPOSE TISSUE IN RATS

G. Borza*, C. Catoi*, A.F. Gal*, M. Taulescu*, P. Bolfa*, A.F. Catoi**

* University of Agricultural Sciences and Veterinary Medicine Cluj-Napoca, Romania,

**University of Medicine and Pharmacy Iuliu Hatieganu Cluj-Napoca, Romania

cornel.catoi@usamvcluj.ro

Introduction: Obesity, with all its comorbidities, is recognized as a major health problem in humans. Obesity induces adipose tissue macrophage infiltration, a significant source of nitric oxide in both humans and mice. Adipose tissue macrophages seem to have an important angiogenetic effect. The aims of the present study were to determine the role of inflammation in obesity-induced neovascularization.

Materials and Methods: Twenty Whistar male rats 30 days aged were used as experimental group. To induce obesity, rats were fed with a high-caloric diet over a 30 weeks period. A control group of 20 rats was used. Blood samples for plasma inflammation markers (TNF- α , IL-6) were taken after 8 weeks and at the end of the experiment (30 weeks). Adipose tissue samples (subcutaneous, omentum and perirenal) were used for histology and immunohistochemistry (macrophages, endothelial cells, iNOS and VEGFR-2).

Results: Plasma inflammation markers and adipose tissue VEGFR-2 expression were significantly increased in obese rats. The number of macrophages was significantly increased in the omental adipose tissue in obese rats. The expression of iNOS and the number of capillaries revealed significantly increase in omental and subcutaneous adipose tissue.

Conclusions: According to our experiment, there is a direct correlation between obesity, general and local adipose inflammation, and neovascularization.



Poster Abstracts Other

PP-105

PENTALOGY OF FALLOT WITH BOTH AN ATRIAL SEPTUM DEFECT AND A PATENT FORAMEN OVALE IN A 2-YEAR-OLD HEIFER

L Bosseler*, V. Saey*, M Cools*, J De Latthauwer*, S Van der Heyden*, S Roels*, R Ducatelle*, K Chiers*

*Faculty of Veterinary Medicine, Ghent University, Belgium

*CODA-CERVA, Belgium

leslie.bosseler@ugent.be

Introduction: Congenital heart disease (CHD) in ruminants is rare. The most common abnormalities are ventricular septum defects (VSD) and atrial septum defects (ASD). Very rarely do cattle with CHD survive into adulthood. Pentalogy of Fallot is the combination of the tetralogy of Fallot, with either an ASD or a patent foramen ovale. Here, we present the first reported case of a pentalogy of Fallot with both an atrial septum defect and a patent foramen ovale.

Case: A 2-years-and-9-months-old Holstein heifer presented various nervous symptoms including head pressing, unilateral blindness and balance problems, and had increased vesicular breath sounds. After unsuccessful treatment with penicillines, the heifer was euthanized and necropsied.

Results: Gross examination revealed an overriding aorta, a VSD, hypertrophy of the right ventricle and stenosis of the truncus pulmonalis (tetralogy), as well as a patent foramen ovale and an ASD (pentalogy). There was severe pulmonary edema and congestion.

Conclusions: This is the first report of a pentalogy of Fallot in an adult ruminant and the first report of a pentalogy of Fallot with both an ASD and a patent foramen ovale.

Poster Abstracts Other

PP-106

PRIMARY PULMONARY DYSPLASIA IN THREE ADULT CATS

V. Karkamo, K. Dillard and M. Anttila

Pathology Unit, Evira, Helsinki, Finland

veera.karkamo@evira.fi

Introduction: Pulmonary hypoplasia or dysplasia is a rare finding in domestic animals. Hypoplasia of the lung is usually accompanied by other malformations such as diaphragmatic hernia and thus it is a secondary phenomenon. Primary dysplasia of trachea and bronchi has been reported in several dog breeds. There are, however, no reports of primary lung hypoplasia or dysplasia in companion animals. Here we report three cases of primary lung dysplasia in cat.

Materials and Methods: The animals were sent for routine necropsy. None of the animals had had clinical signs typical for respiratory disease. A complete necropsy was performed and samples of all major organs and macroscopically abnormal tissues were fixed in buffered 10% formalin, routinely processed and embedded in paraffin. 4 µm sections were cut and stained with H&E.

Results: In three adult domestic cats the cranial lung lobes were severely malformed. They were composed of variably sized blood vessels, bronchi and bronchioles surrounded by loose fibrous connective tissue. Normal alveolar structures were not present. The macroscopically unaffected (80-90%) lung lobes were histologically normal.

Discussion: It appears that there was a problem in branching morphogenesis of the lung and an arrest at the pseudoglandular developmental stage in these cats. Most of the lung was structurally normal which together with the sedentary life-style of these house-cats explains the lack of observable respiratory impairment. In humans lung bud malformation has more severe consequences.

Poster Abstracts Other

PP-107

FOCAL THORACIC INTRA-MEDULLARY DIPLOMYELIA IN AN ADULT HORSE WITH LYMPHOMA

R. J. Blundell*, E. Ricci*, M. Robin[†], H. Carslake[†]

**Veterinary Pathology and [†]Philip Leverhulme Equine Hospital, School of Veterinary Science, University of Liverpool, UK*

r.j.blundell@liv.ac.uk

Introduction: Diplomyelia is a form of myelodysplasia in which there is duplication of the spinal cord. This may manifest as two distinct spinal cords within a common meningeal lining, or a mixture of grey and white matter within partially merged spinal cords.

Materials and Methods: A 16 year old Thoroughbred pregnant mare presented with a history of acute onset severe obtundation, right sided absence of menace response and reduced sensation over the right side of the face and trunk. Previous serum biochemistry revealed increased liver enzymes.

Results: Post-mortem examination revealed a severe haemoabdomen and haemorrhage throughout the uterus and vagina; the liver was pale and enlarged. Histopathological examination of major organs revealed multicentric T-cell lymphoma. The only significant brain lesion was a focally extensive haemorrhagic infarct in the left cerebellar nuclei. Along the thoracic spinal cord, from T2 to T4, grey matter of the right dorsal horn was expanded and replaced by a well demarcated structure composed of disarranged grey and white matter surrounding an additional ependymal canal.

Conclusions: The horse displayed signs consistent with disseminated intravascular coagulation, secondary to disseminated neoplasia, including the cerebellar haemorrhage. The spinal cord dysplasia, characterised by duplication of the ependymal canal may be defined as diplomyelia, which explains some of the neurological deficits which complicated lesion localisation at neurological examination.

Poster Abstracts Other

PP-108

HISTOPATHOLOGICAL STUDIES OF UTERI FROM SUBFERTILE COWS

J. Bartels*, M. Leipig[‡], F. Weber*, H. Zerbe* and W. Hermanns[‡]

*Clinic for Ruminants with Ambulatory and Herd Health Services and [‡]Institute of Veterinary Pathology at the Centre for Clinical Veterinary Medicine, Ludwig-Maximilians-Universität München

leipig@patho.vetmed.uni-muenchen.de

Introduction: The aim of the study was the histological characterisation of uteri from subfertile cows (suspected chronic subclinical endometritis) in comparison to heifers and cows with pyometra.

Materials and Methods: Uteri from heifers (n=14), cows with pyometra (n=10) and subfertile cows were investigated. Per uterus at least 14 localisations were investigated having regard to morphological features (epithelial injury, fibrosis, glandular changes, endometrosis) and the presence and distribution of inflammatory cells (lymphocytes, plasma cells, PMN, macrophages, mast cells, eosinophils).

Results: Overall the results of subfertile cows resembled those of the heifers, although a slight increased incidence of glandular atrophy, consolidation of the stratum compactum, dilations of distal glandular layers, interstitial oedema and dilation of lymph vessels occurred. Endometrosis was found but did not play a dominant role in this group. Inflammatory cell infiltrates (lymphocytes, plasma cells, PMN) were increased compared to the heifers and were lower than in cows with pyometra.

Conclusion: Changes in uteri of subfertile cows differ from those in cows with pyometra and from heifers.

Poster Abstracts Other

PP-109

ENDOCANNABINOID SIGNALLING IN SKIN WOUND HEALING

Ji-Seung Ko, Han-Jun Kim, Hye-Rim Lee, Kyung Hyun Lee[†], Sun Hee Do^{*}

Department of Veterinary Clinical Pathology, College of Veterinary Medicine, Konkuk University, Seoul 143-701, Korea, [†]Pathodiagnostic lab. Animal Disease Diagnostic Division, Animal, Plant and Fisheries Quarantine and Inspection Agency, Anyang 430-824, Korea

shdo@konkuk.ac.kr

Introduction: Endocannabinoid system (ECS) role in re-establishing cellular homeostasis in the central nervous system as well as peripheral cells of the most tissue. In this study, we attempt to determine if cannabinoid receptor (CB)1 had an effect on cutaneous wound healing using CB1 knockout (KO) mice.

Materials and Methods: Full-thickness wound were made on the dorsal region of CB1-KO mice and wild type (WT) mice for histopathological evaluation. To determine the underlying cellular and molecular mechanisms in inflammatory and proliferative phase, we performed further investigations primary fibroblasts cultures.

Results: CB1-KO mice revealed decrease of wound contraction ratio relation with increase of total inflammatory cells infiltration and wound bed size including delay of re-epithelialization compared with WT mice. In vitro, primary cultures of CB1-deficient fibroblasts released increased amounts of TNF- α after stimulation with LPS compared with controls. However, the level of NF- κ B and TGF- β 1 was not distinguishable changes between groups. In addition, CB1-deficient fibroblasts showed enhanced expression of Smad2 and Smad3 without LPS and then decreased by LPS stimulation.

Conclusions: The data revealed that CB1 are functionally expressed by cutaneous fibroblasts in vivo and help to limit the secretion of inflammatory cytokines. Taken together, CB1 regulate Smad2/3 mediated with wound closure and re-epithelialization.

Poster Abstracts Other

PP-110

META-ANALYSIS OF MULTIPLE SCLEROSIS AND EXPERIMENTAL MODELS OF DEMYELINATION

B. Hierlmeier^{*}, F. Hansmann^{*}, I. Spitzbarth^{*}, A. Kalkuhl[†], U. Deschl[†], W. Baumgärtner^{*} and R. Ulrich^{*}

^{*}Department of Pathology, University of Veterinary Medicine Hannover, Germany and [†]Department of Non-Clinical Drug Safety, Boehringer Ingelheim Pharma, Biberach (Riß), Germany

reiner.ulrich@tiho-hannover.de

Introduction: Microarray studies of Multiple sclerosis (MS) and its experimental models use diverse methodologies and display a low overlap of differentially expressed genes (DEGs). The aim of this study was to compare multiple gene expression studies employing a consistent methodology.

Materials and Methods: Included studies with publically available raw data for re-analysis using LIMMA ($q \leq 0.05$) and a fold change filter (≤ -2.0 or ≥ 2.0), cross-species and cross-platform comparison, and Gene Set Enrichment Analysis (GSEA) were MOG-induced experimental allergic encephalomyelitis in rats, Theiler's murine encephalomyelitis, and a TNF-overexpressing mouse line. Since MS raw data were unavailable, the original results of two MS studies were included in the comparisons of DEGs only.

Results: The intersection of MS and its models was zero DEGs. The intersection of the three models comprises 46 DEGs, functionally related to activation of the immune response, MHC II-dependent antigen presentation, and complement activation. GSEA analysis suggests pathogenic involvement of the immune response, inflammatory response, coagulation, lipid transport, cytokine production, regulation of signal transduction, and JAK/STAT-signaling.

Conclusions: In contrast to simple comparisons of DEGs, GSEA generates new pathomechanistic hypotheses. Conclusively, publically available MS microarray raw data are needed to exploit the full potential of up-to-date biostatistical methods.

Poster Abstracts Other

PP-111

PROBIOTICS RESTORING THE PATTERN OF APICAL JUNCTION COMPLEX PROTEIN (AJC) EXPRESSION IN THE ENTERO-COLIC MUCOSA OF DOGS WITH INFLAMMATORY BOWEL DISEASE (IBD)

G. Rossi^{*}, A. E. Jergens[†], J. S. Suchodolski[†], G. Pengo[‡], A. Piccinini^{*} and G. E. Magi^{*}

^{*}School of Veterinary Medical Sciences, University of Camerino, Italy, [†]Texas A&M University, College Station and [‡]Practitioner, Cremona, Italy

giacomo.rossi@unicam.it

Introduction: The apical junction complex (AJC) plays a significant role in regulating epithelial paracellular permeability.

Materials and Methods: We have studied by immunohistochemistry the distribution of tight junction components (claudin-2, occludin) and adherens junction (E-cadherin) proteins in normal enterocolic tract from 3 control dogs (CD) and from 10 dogs with IBD, before and after a probiotic treatment (VSL#3, VSL Pharmaceuticals, Inc; 450 billion lyophilized bacteria daily for 60 days).

Results: In CD group occludin-specific labelling was most intense at the epithelial cell AJC and appeared uniformly expressed throughout the epithelium of small and large intestine, but in IBD group a weak to absent expression was observed in luminal epithelium and in some intestinal glands of the small intestine. No differences in the distribution or staining intensity of E-cadherin were observed between normal and affected dogs. In CD group claudin-2 was detectable in duodenal epithelium and glands and in colonic crypt epithelium, decreasing in intensity from the distal to the proximal crypt and becoming barely detectable at the luminal surface of the colon. However claudin-2 expression was increased in the proximal crypt and luminal epithelium of all dogs with IBD.

Conclusions: The observation that the expression and distribution of occludin and claudin-2 were restored after VSL#3 treatment, may provide insight into the effects of probiotics on intestinal barrier function.

Poster Abstracts Other

PP-112

THE EFFECT OF INTENSE PULSED LIGHT IN MOUSE SKIN

D. Rodrigues*, A. Gama*, M. J. Pires*, B. Colaço*, P. A. Oliveira*

**Department of Veterinary Sciences, UTAD, Vila Real, Portugal*

agama@utad.pt

Introduction: The use of Intense Pulsed Light (IPL) devices has increased significantly last years and there are few studies about its side effects. The aim of this study was to understand the influence of IPL in mouse normal skin and in the development of precancerous skin lesions using an animal model of skin carcinogenesis.

Materials and Methods: Animal procedures were performed in accordance with the European Guidelines. ICR female mice were used and they were divided into: group I, exposed to the skin carcinogenesis initiator 7,12-dimethylbenz(a)anthracene (DMBA), without further treatment; group II, subjected to IPL treatment after DMBA initiation; group III, exposed to the promoter 12-o-tetradecanoylphorbol-13-acetate, after DMBA initiation; group IV, exposed only to IPL and group V, the control group. The experimental protocol lasted 25 weeks.

Results: At the end of the experimental protocol, 87 papillomas and 7 squamous cell carcinomas were identified in group III (DMBA+TPA). Histologically, it was observed that IPL was not linked to neoplastic development, but dermal fibrosis was identified (groups II and IV). Nevertheless, 50% of the animals in group II developed epidermal focal hyperplasia, a result that may suggest IPL as a carcinogenesis promoter.

Conclusions: We consider essential to carry out further studies in order to confirm these results and to verify the hypothesis of IPL being a carcinogenesis promoter.

Poster Abstracts Other

PP-113

PATHOLOGICAL EFFECTS OF APPLICATION OF SILICIUM CARBIDE ENGINEERED NANOPARTICLES

T. Ristoski¹, V. Vasilevska², K. Mladenovska³, A. Grozdanov⁴

¹Faculty of Veterinary Medicine, ²Clinic of surgery diseases "St. Naum Ohridski", ³Faculty of Pharmacy, ⁴Faculty of Technology and Metallurgy, University "Ss Cyril and Methodius", Skopje, R. Macedonia

tristoski@fvm.ukim.edu.mk

Introduction: Nanotechnology is an emerging science and the research work on the new nanotechnologies has been intensively performed. In this study, the influence of the Silicium Carbide (SiC) nanoparticles on the haematological and pathohistological changes was analysed.

Materials and Methods: The toxicity of nano-sized SiC particles on 4 weeks old female Wistar rats was investigated. The rats were divided into four groups: 2 control groups, one control, not-treated group and the second one, vehicle-control group, and 2 experimental groups treated with different dose of nanoparticles (1 g/kg and 5 g/kg body weight). Animals were sacrificed 2, 7 and 14 days of the exposure. Biochemical and histopathological examination were carry out.

Results: Loss of weight, significant increasing of the platelet count in both experimental groups as well as significant changes of serum LDH and the levels of enzymes was found. Due to the presence of nanoparticles, the histopathological investigations showed hepatocytes degeneration, stasis with micro haemorrhages, lymphocytes and eosinophil infiltration in almost all examined tissues.

Conclusions: The specific structure parameters of nanomaterials to enable numerous practical applications of this material, but some toxicological effects could be provoked. The results of this study confirm the important influence of nanoparticles on the haematological parameters and tissue structure.



Poster Abstracts Other

PP-114

BRAIN DEVELOPMENT IN A MOUSE MODEL OF MUSCLE EYE BRAIN DISEASE

H. S. Booler, J. Williams, S.C.Brown

Neuromuscular Diseases Group, Department of Comparative Biomedical Sciences, Royal Veterinary College, London, NW1 0TU

hbooler@rvc.ac.uk

Normal brain development is a complex, tightly regulated, multi-step process, which requires the formation of a stem cell pool, division and differentiation of these progenitors into neurons and glia, and the ordered migration of post-mitotic neurons.

Type II lissencephaly (also referred to as cobblestone lissencephaly) is a neuronal migration defect pathognomonic of a group of severe congenital muscular dystrophies, which are characterised by brain, eye and muscle defects. These disorders include **Walker-Warburg syndrome (WWS)** and **Muscle-Eye-Brain (MEB)** disease, and show a range of substantial structural brain abnormalities associated with defects in neuronal migration. They represent the severe end of the phenotypic spectrum of a heterogeneous group of muscular dystrophies called the **dystroglycanopathies**. These are characterised by the hypoglycosylation of alpha dystroglycan and vary in severity from the severe congenital muscular dystrophies (such as WWS and MEB) with substantial structural brain and eye defects, through to milder limb girdle muscular dystrophies (LGMD).

To date, more than 14 genes have been implicated in the glycosylation of alpha dystroglycan. **Fukutin-related protein (FKRP)** is one of these genes. In this developmental study, we investigate the pathogenesis of brain lesions in the FKRP^{KD} - a mouse model of muscle-eye-brain disease with an 80% knock down in FKRP expression. Work from other groups involving mouse models of dystroglycanopathy has shown that the brain initially develops normally, but basement membrane defects begin to develop around E13.5 (Hu et al., 2007). Here, we investigate the origin of the brain lesions in the FKRP^{KD} mouse.



Poster Abstracts Other

PP-115

THE EFFECT OF PROBIOTICS ADMINISTRATION ON INTESTINAL MORPHOLOGY IN POSTWEANING PIGS

A. Szczotka-Bochniarz*, K. Podgorska*, M. Szczotka*, Z. Osinski[†], H. Burchardt[‡], K. Kamieniecka* and Z. Pejsak*

**Department of Swine Diseases and *Department of Biochemistry and [†]Department of Hygiene of Animal Feedingstuffs, National Veterinary Research Institute, Poland and [‡]JHJ, Poland*

anna.szczotka@piwet.pulawy.pl

Introduction: After withdrawal of antibiotic growth promoters probiotics serve as a promising alternative in animal production. The aim of this study was to analyze the effect of probiotics administration on intestinal morphology in postweaning pigs.

Materials and Methods: A total of 240 weaned piglets were divided into 5 groups. Group 1 served as negative control, while others received supplementation with: group 2 - Lactobacillus lactis, 3 - Carnobacterium divergens, 4 - Lactobacillus plantarum, Lactobacillus casei, Lactobacillus parcasei, 5 – L. lactis, L. plantarum, L. casei, L. parcasei, C. divergens, Saccharomyces cerevisiae. Sections of duodenum, jejunum and ileum were subjected to morphometric analysis using microscope-linked image analysis software. Also, the analysis of variation of results was performed.

Results: Significant shortening of villus length in duodenum in probiotics-fed groups was found. A statistically significant increase in villus length in jejunum was observed in group 2. In group 5 villus width was reduced. Also, a statistically significant decrease in crypt width in jejunum in all groups was found.

Conclusions: Probiotic supplementation in postweanig pigs did not result in a significantly beneficial effect on the analyzed morphometric parameters. The use of probiotic preparations based on a single strain gave significantly better effects than a multi-composed formula.

Poster Abstracts

Other

PP-116

ULTRASTRUCTURAL PATTERN OF THE LIVER IN RAINBOW TROUT (*ONCORHYNCHUS MYKIS*, WALBAUM 1792) REARED EXTENSIVELY (OS) AND INTENSIVELY (RAS)

J. Szarek*, B. Szynaka**, I. Babińska*, A. Andrzejewska**, E. Strzyżewska*, S. Dobosz***, J. Zakrzewski*, A. Wiśniewska* and J. Wojtacka*

University of Warmia and Mazury, Olsztyn, **Medical University, Białystok, *Inland Fisheries Institute, Rutki, Poland*

szarek@uwm.edu.pl

Introduction: There is a tendency to develop intensive rainbow trout rearing with the use of water circulation system (RAS) instead of extensive rearing - open system (OS). The study presents the morphology of hepatocyte organelles in rainbow trout reared in these different ways.

Materials and Methods: Forty trout were taken from 3 fish farms of OS and 3 of RAS type in the spring and autumn in the period of two years. Each time 20 fish of 350-500g b.m. (T-typical) and 20 of 501-800g b.m. (B-big) – n=20, were taken. Ultrastructural analysis was conducted with the use of electron microscope TEM 900 PC Opton (Germany).

Results: Ultrastructural analysis of the liver showed minor lesions in mitochondria (oedema, dense bodies and sporadically effaced crest structure and matrix rarefaction). Myelin-like structures and partial necrosis of hepatocytes as well as mitochondria proliferation and their polymorphism were sporadically found. Steatosis simplex was noted quite frequently, especially in the fish from group B.

Conclusions: Ultrastructural analysis showed minor lesions - similar in the fish from OS and RAS. However they were slightly more intensive in RAS fish, especially in the autumn. Ultrastructural pattern of the trout's liver was more diversified between fish from the particular fish farms.

Poster Abstracts

Other

PP-117

PATTERNS OF THE CONCENTRATION OF GLYCOSAMINOGLYCANS IN THE LIVER OF THE RAINBOW TROUT (*ONCORHYNCHUS MYKISS*, WALBAUM 1792) REARED IN TWO DIFFERENT TECHNOLOGIES

I. Babińska*, J. Szarek*, E. Strzyżewska*, J. Wojtacka*, K. Wąsowicz*, K. Dublan*, J. Zakrzewski*, H. Białowas** and A. Penkowski*

**University of Warmia and Mazury, Olsztyn, **Polish Academy of Science, Gołysz, Poland*

Izabella.Babinska@uwm.edu.pl

Introduction: In the EU countries, trout are cultured in an open system (OS) with a single water flow or with water recirculation (RAS). While searching for the best solutions in aquaculture, levels of glycosaminoglycans in livers of trout were analyzed.

Materials and Methods: The tests were carried out in spring and autumn in 2010-2012. Each time 20 trout were sampled from 6 fish farms (3-OS and 3-RAS). Ten fish weighed 350-500 g and ten 501-850 g. Liver sections were stained according to PAS method as described by McManus. The concentration of glycosaminoglycans was determined according to Pearse's protocol and a scale proposed by Szarek et al. (1985).

Results: In most of the trout fish, irrespective of the season of the year, the liver was characterized by a moderate and high content of glycosaminoglycans. U-Mann-Whitney's test demonstrated lack of statistically significant differences in concentrations of the polysaccharides in livers of fish reared in the OS and RAS systems, although higher concentrations tended to appear in fish reared in the RAS farm and captured in spring.

Conclusion: The patterns of the concentrations of glycosaminoglycans were similar in fish from OS and RAS farms, but varied between individual farms.

Poster Abstracts Other

PP-118

SMALL INTESTINE APOPTOSIS AFTER HAEMORRHAGE FOLLOWED BY VOLUME REPLACEMENT – A PRELIMINARY STUDY

Ana Ortiz¹, Helena Vala², Carla Garcia², Rita Cruz², Carlos Venâncio³, Aura Silva⁴, David Ferreira⁵

1 – University of León, Spain.

2 – CEETS-IPV Viseu, Portugal

3 – IBMC-Porto, Portugal

4 – REQUIMTE, Porto, Portugal

5 – CICV-ULHT, Lisboa, Portugal

liza.oliveira@gmail.com

Background: Apoptosis plays a key role in intestinal injury, as response to ischemia. Furthermore, reperfusion exacerbates abnormal intestinal apoptosis. In this study, the apoptotic index (AI) in the small intestine after haemorrhage and volume replacement with Ringer's solution was evaluated, in a pig model.

Materials and Methods: 15 Large White pigs underwent total intravenous anaesthesia (TIVA) with propofol and remifentanyl. In group1, animals underwent controlled bleeding and volume was replaced using Ringer's lactate. In group2 (control group), animals underwent TIVA, without any procedure. One hour after volume replacement, pigs were euthanized. Immunohistochemistry was performed, using *in situ* TUNEL method, in small intestine segments. National authority approval–DGV000228.

Results: AI of small intestine mucosa was, for group1, 41.68% (duodenum), 33% (jejunum) and 32.23% (ileum); group 2: AI was 36.44% (duodenum), 34.78% (jejunum) and 23.84% (ileum). AI was significantly higher in group1, in the ileum ($P<0.01$).

Discussion & Conclusions: Apoptosis occurred mainly in the epithelium of the villi, appearing to precede the intestinal mucosa desquamation described in ischemia situations; duodenum was the most affected intestinal segment. Although further studies are underway to corroborate Tunel results, is possible to conclude that, in a situation of hypoperfusion and volume replacement, small intestine undergoes a significant apoptotic rate, more severe in the duodenum.

Funding: FEDER-COMPETE Program, FCT, project COMPETE: FCOMP-01-0124-FEDER-009525

Poster Abstracts Other

PP-119

RENAL APOPTOSIS SIGNALLING IN A PIG HAEMORRHAGIC MODEL, AFTER VOLUME REPLACEMENT WITH HES 130/0.4 OR RINGER SOLUTION

Cruz R^{1,2,3}, Vala H^{1,2}, Machado A^{1,2}, Venâncio C³, Mesquita JR^{1,2}, Silva A⁴, Ortiz AL⁵, Ferreira D⁶

1-ESAV, IPV, Portugal

2-CI&DETS, IPV, Portugal

3- UTAD, Portugal

4 – REQUIMTE, Portugal

5-León University, Spain

6-CICV/FMV-ULHT, Portugal

liza.oliveira@gmail.com

Objective: TUNEL staining is one of the most frequently used method to detect apoptosis in renal tissues. The aim of this part of the study was to evaluate kidney damage after acute bleeding and volume replacement, with a colloid or a crystalloid, in a pig model.

Methods: According to the actual animal welfare regulation, three groups (n=6) of Large White pigs were enrolled in the study. All groups underwent a total intravenous anaesthesia and submitted to acute bleeding and volume replacement with Ringer lactate or HES 130/0.4, 20 min after. Control group did not face bleeding and volume reposition. Pigs were euthanized and renal samples were taken and analyzed with TUNEL method. ANOVA was used to compare data between groups.

Results: An intense positive signal in epithelial tubular cells was observed in all samples, the level of signalling per mm² was significantly lower in Ringer Lactate group(11.94), comparing with HES130/0.4 group(67.94) and control group(146.34)for epithelial tubular cells (P<0.05).

Conclusion: In this model, we conclude that signalling levels were lower in pigs, subjected to fluid replacement with RL, when compared with control group. Ringer lactate might promote better renal perfusion in the presence of severe hypoperfusion.

Funding: FEDER (COMPETE Program) and FCT (project COMPETE: FCOMP-01-0124-FEDER-009525)



Poster Abstracts Other

PP-120

HISTOLOGICAL EVALUATION OF THE SPLEEN AFTER ACUTE BLEEDING FOLLOWED BY VOLUME REPLACEMENT WITH TWO DIFFERENT PHYSIOLOGIC SOLUTIONS

Marlene Cabral¹, Ana Ortiz², Carlos Venâncio³, João Mesquita⁴, Carmen Nóbrega⁴, Aura Silva⁵, Helena Vala⁴, David Ferreira⁶

¹ - Agrarian Superior School, IPV Viseu, Portugal

² - University of León, Spain.

³ - IBMC-Porto, Portugal

⁴ - CEETS-IPV Viseu, Portugal

⁵ - REQUIMTE, Porto, Portugal

⁶ - CICV-ULHT, Lisboa, Portugal

liza.oliveira@gmail.com

Introduction: Spleen is important for many hematopoietic and immunological functions, namely in hemodynamic compensation during hemorrhagic shock, with a crucial role in restoring blood volume in situations of acute haemorrhage. Also, the administration of physiological solutions is of great importance for the correction of circulating volume, avoiding complications due to hypovolemia. The aim of this study was to evaluate spleen's histopathological changes, associated with volume replacement using two different physiologic solutions (Hydroxyethyl Starch (HES) 130/0.4 and Ringer Lactate), after acute controlled bleeding, in a pig model.

Materials and Methods: 31 Large White pigs underwent total intravenous anaesthesia with propofol and remifentanyl. A total of 25ml/kg of blood was passively removed over 20 minutes. Intravascular volume was replaced using Ringer Lactate 25ml/kg (group1- n=13) and HES130/0.4 20ml/kg (group2- n=11). Spleen samples were processed for routine histopathological evaluation.

Results: Regarding the follicular lymphoid hyperplasia, statistically significant differences were found between the control group and group1, and between group1 and group2, with an increased follicular lymphoid hyperplasia in group1.

Conclusion: Volume replacement with HES130/0.4 may reduce follicular lymphoid hyperplasia when compared with volume replacement with Ringer Lactate, after acute bleeding.

Funding: FEDER (COMPETE Program) and FCT (project COMPETE FCOMP-01-0124-FEDER-009525)



Poster Abstracts Other

PP-121

EFFECTS OF TOPICAL NITROGLYCERIN ON WOUND HEALING IN RABBIT

Moshaveri Arman², Sasani Farhang¹, Babazadeh Daryoush³, Alyari Gavaher Mahdi², Sadeghi Alireza³, Arekhi Yashar²

¹ Department of Veterinary Pathology, Faculty of Veterinary Medicine, Tehran University, Tehran, Iran

² Faculty of Veterinary Medicine, Karaj Branch, Islamic Azad University, Karaj, Iran

³ Young Researchers and Elite Club, Tabriz Branch, Islamic Azad University, Tabriz, Iran

fsasani@ut.ac.ir

Introduction: Nitroglycerin enhances nitric oxide rate in tissues, dilates vessels and intensifies tissue perfusion.

Materials and Methods: 6 adult male New Zealand white rabbits, weighting approximately $2\text{ kg} \pm 2.25$ were used. Two wounds were created on each side of the spinal column. The wound dimensions were 15×15 mm. The right wounds were treated with nitroglycerin and the left wounds were untreated. After creation of the wounds a layer of Nitroglycerin 2% with 1 mm thickness was put on experimental wound daily for seven days. On 3th, 5th, 7th, 14th days after cutting, both tissues were taken for histopathological examination.

Results: The wound edges were closer together in the treatment group on 14th day ($p < 0.05$). The number of inflammatory cells was less than control group on 5th, 7th, 14th day ($p < 0.05$). On 5th, 7th, 14th day the fibrin clot diameter in treatment group was less than control group ($p < 0.05$). At the beginning of the experiment angiogenesis in the control group was more than in the treatment group but in 7th day it was the same in both group, but after 7th day, angiogenesis in the treatment group was more than in the control group ($p < 0.05$). The volume of granulation in the treatment group was more than in the control group on 5th, 7th, 14th day ($p < 0.05$). Epithelial tissue diameter was more in the treatment group on 14th day ($p < 0.05$).

Conclusion: Topical treatment with nitroglycerin affected wound healing in this experimental model.

Poster Abstracts Other

PP-122

EFFECT OF THE PHYSIOLOGICAL STATE AND OF A DIET RICH IN POLYUNSATURATED FATTY ACIDS (PUFA) ON THE IMMUNE RESPONSE OF THE MAMMARY GLAND IN THE SHEEP

C. Brachelente*, E. Lepri*, G. Acuti†, A. Giontella†, M. Trabalza Marinucci†, L. Mechelli*, I. Porcellato*

**Department of Biopathological Sciences and Hygiene of Animal and Alimentary Productions; †Department of Pathology, Diagnostic and Veterinary Clinic, University of Perugia, Perugia, Italy*

chiara.brachelente@unipg.it

Introduction PUFA have been demonstrated to play an important role in the prevention of several diseases in human beings. The aim of this research was to analyze the influence of a dietary supplementation with extruded linseed (source of omega-3 fatty acids) on the physiological state of the ovine mammary gland.

Materials and Methods The study was conducted on a flock of Sarda sheep, divided in two groups (S: supplemented, C: control). S group diet was supplemented with linseed. Biopsies from mammary glands were morphologically and immunohistochemically analyzed to evaluate the health status of the organ.

Results The dietary supplementation with linseed did not result in substantial changes on the immune response of the mammary gland. Although the incidence of mastitis was higher in S sheep compared to C sheep (52.73% vs 47.27%), this was related to the physiological state (pregnancy/lactation). Immunohistochemistry showed that, when present, the inflammatory process was milder in S sheep than in C sheep, with lower T- and B-cell counts.

Conclusions The study demonstrates that dietary linseed supplementation has no detrimental effect on the mammary gland health status and possibly has an immunomodulatory action.

Poster Abstracts Other

PL-123

VASCULAR HAMARTOMA IN THE CAUDAL BRAIN STEM OF A FOAL

N. Borel^{*}, P. Grest^{*}, H. Junge[§], M. Wehrli-Eser[§]

^{}Institute of Veterinary Pathology and [§]Internal Medicine Unit, Clinic for Horses, Vetsuisse Faculty, University of Zurich, Switzerland*

n.borel@access.uzh.ch

Introduction: Vascular hamartomas are non-neoplastic developmental anomalies of the vasculature. Cases of cerebral vascular hamartomas have been mostly reported in dogs and cats.

Materials and Methods: A four-week-old Freiburger foal showed problems with swallowing since birth and developed larynx and facial nerve paralysis thereafter. Necropsy revealed a pinkish mass in the caudal brain stem. The mass was further investigated by histopathology and immunohistochemistry.

Results: Histologically, the mass consisted of many thin-walled blood-filled vascular structures of variable diameter, involving the white matter in the caudal brain stem. The predominant population was immunohistochemically positive for Factor VIIIa (Von Willebrand factor), interpreted as endothelial cells. The endothelial-lined vascular spaces were supported by a second cell population that was positive for smooth muscle actin (SMA), interpreted as pericytes.

Conclusions: A diagnosis of focal vascular hamartoma in the caudal brain stem was made. To the authors' knowledge, this is the first report of a vascular hamartoma in the caudal brain stem of a foal. In this case, the development of clinical signs is attributed to the compression of the surrounding cerebral parenchyma.

Poster Abstracts

Other

PP-124

ATYPICAL CEREBELLAR CORTICAL ABIOTROPHY IN A MIXED BREED DOG

K. Bernodt*, S. Fors**, K. E. Soerensen* and E. Karlstam*

* National Veterinary Institute, Department of Pathology and Wildlife Diseases, Uppsala, Sweden and

**Bagarmossen Referral Small Animal Hospital, Sweden

karin.bernodt@sva.se

Introduction: One of the most common abiotrophies in domestic animals are those affecting cerebellar cortex (CCA). Typical histopathological lesions are loss and degeneration of Purkinje cells, with or without loss of granular cells. Two cases of atypical CCA have previously been described in the dog breed Lagotto Romagnolo. This case report describes a mixed-breed dog with 75% Lagotto Romagnolo showing similar histological lesions as one of the dogs diagnosed with atypical CCA.

Materials and Methods: The dog showed clinical signs of ataxia and head tremor. Symptom was observed at 3,5 months of age and the clinical signs progressed during the next two months. The dog was finally euthanized. The clinical veterinarian suspected CCA based on clinical examination, MR and analysis of CSF. A necropsy was conducted including histopathological examination of representative areas of the brain and cerebellum in sections stained with H&E.

Results: No significant macroscopic lesions were observed. Histologically the cerebellum showed a severe depletion of granular cells with a mild-moderate gliosis. Purkinje cells showed mild degeneration but their number was estimated to be normal.

Conclusions: CCA has been reported in many dog breeds and the histological picture is similar in affected dogs of the same breed. To the authors' knowledge, this is the third report of this atypical type of CCA in Lagotto Romagnolo dogs.

Poster Abstracts Other

PP-125

SUBCUTANEOUS CHRONIC EXPANDING HEMATOMAS IN 6 DOGS

G. Avallone*, M. Daresta*, P. Roccabianca†, D. Stefanello†, L. Crippa‡, G. Ghisleni†, E. Laddaga**, L. Pazzini†, G. Sarli*

*Department of Veterinary Medical Sciences, University of Bologna, Italy

†Dipartimento di Scienze Veterinarie e Sanità Pubblica, University of Milano, Italy

‡Istovet, Besana Brianza, Milano. Italy

**Ospedale Veterinario I Portoni Rossi, Zola Predosa, Bologna, Italy

*Clinica Veterinaria Centro Storico, Bolzano, Italy

giancarlo.avallone@gmail.com

Introduction: Chronic expanding hematoma (CEH) is a slow-growing reactive lesion that can mimic soft tissue sarcoma (STS) and that is associated with trauma or surgery in man. CEH has been reported in dogs following injection or trauma.

Materials and Methods: Six cases of canine CEH were examined. Anamnesis and follow-up were collected. Tissues were routinely processed and stained. Microscopical findings in canine CEH were evaluated and compared with 3 cases of injection-type panniculitis (ITP).

Results: CEH were located on ischial tuberosity (2/6), flank (2/6), neck and shoulder and ranged from 3 to 20 cm in diameter. Histology evidenced a central cavity, containing fibrin and erythrocytes, surrounded by a multilayered capsule composed of an internal band of immature granulation tissue, an intermediate layer of perpendicularly oriented vessels, and an external fibrous layer infiltrating adjacent tissues. After surgery 3 cases recurred and 3 had delayed healing. Three cases of ITP lacked prominent layering, had a thinner capsule and mild inflammation.

Conclusions: CEH may represent an uncommon evolution of necrotizing panniculitis that can undergo post-surgical complications and, because of the infiltrative growth, may need to be differentiated from STS.

Poster Abstracts Other

PP-126

MASSIVE PULMONARY ALVEOLAR LIPOPROTEINOSIS IN AN ENGLISH BULLDOG

A. Forlani ^{*}, C. Palmieri [†], S. F. Santagostino ^{*}, R. Queliti [‡], P. Roccabianca ^{*}

^{*} DIVET, School of Veterinary Medicine, University of Milan, Italy and [†] School of Veterinary Science, University of Queensland, Gatton Campus, QLD and [‡] Bracco Imaging spa, Turin, Italy

annalisa.forlani@unimi.it

Introduction: A 7 year, male, English Bulldog with a history of juvenile idiopathic epilepsy treated with phenobarbital and bromide developed sudden severe dyspnoea with respiratory arrest 12 hours post-admission. Thoracic X-Rays revealed alveolar and interstitial abnormal patterns.

Materials and Methods: Necropsy was carried out, tissues were routinely processed and stained. PAS, von Kossa and Congo red of lungs were performed. Selected lung samples were submitted for transmission electron microscopy (TEM).

Results: Necropsy revealed severe hepatomegaly with reduced liver consistency, mitral valve endocardiosis and pulmonary oedema with disseminated 1-8 mm, umbilicated lesions in apical, accessory and right principal lung lobes. Microscopically, alveoli (60-80%) were filled by a pale eosinophilic, amorphous to granular PAS-positive, von Kossa and Congo red negative material associated with macrophages, neutrophils. Interstitial fibrosis and mineralization were moderate. Myocardial septal and right ventricle fatty infiltration was present. TEM revealed short lamellar 3.125 nm fascicles at 6.25 nm periodic distance compatible with accumulation of surfactant.

Conclusions: Differential diagnoses included alveolar proteinosis, lipidosis and hyalinosi. The conjunction of lesions was suggestive of an alveolar lipoproteinosis/phospholipidosis. Association with mineralization and inflammation explained the dyspnoea. The alveolar storage could have derived from chronic administration of bromide.

Poster Abstracts Other

PP-127

APOPTOSIS IN THE NORMAL CANINE UTERUS

MA Pires*, F Fontinha*, A Gama*, R Payan-Carreira*

*CECAV-ECAV-UTAD, Vila Real, Portugal

agama@utad.pt

Introduction: During the canine estrous cycle, endometrium undergoes several morphological changes that determine female fertility. It has been demonstrated that apoptosis participates in the regulation of endometrial cycle. Caspase-3 is required for critical hallmarks of apoptosis. In this study we purpose to assess the activated caspase-3 immunolabeling in canine endometrium during the estrous cycle.

Materials and Methods: Six uteri in different stages of oestrous cycle were used. Indirect immunohistochemistry was performed using an antibody against activated caspase-3 (Cell Signaling®, 1:1000). The labeled apoptotic cells were counted in ten fields, separately for the surface epithelium, the superficial (SG) and deep glandular (DG) layers. Data was analyzed as the average of apoptotic cells for each endometrial structure.

Results: Overall immunoreaction for activated caspase-3 was always lower for the surface epithelium than for the glandular epithelia, exception made for anoestrus when apoptotic cells do not differ amongst the 3 epithelial types. In all the stages but the anoestrus, the DG showed the highest number of apoptotic cell, the number being statistically higher in early dioestrus, when progesterone levels are rising. Stroma seldom marked for active caspase-3, why the results were not considered.

Conclusion: In canine endometrium, the glandular showed the most important changes in activated caspase-3 during the oestrous cycle. This molecule increases in parallel to the rising of progesterone in blood. In anoestrus, apoptosis is almost absent.

Poster Abstracts Other

PL-128

ALOPECIA AREATA UNIVERSALIS IN A DOG

E. Mozos*; B. Blanco†, J. Pérez*, R. Zafra‡, J. Negrini* P.J. Ginell†

* Department of Comparative Pathology, †Department of Animal Medicine & Surgery, Faculty of Veterinary Medicine, University of Córdoba and ‡IUSA, University of Las Palmas de Gran Canaria, Spain

an1momoe@uco.es

Introduction: Human alopecia *areata* (AA) is an autoimmune disease directed preferentially against hair follicles. It manifests clinically as patchy, non-scarring hair loss, although it may progress to total hair loss (alopecia *universalis*). The dog has been proposed as a natural model for the study of the pathogenesis of this autoimmune disease of humans but AA *universalis* has not been reported in dogs.

Materials and Methods: A 9 year-old entire male cross-breed dog was presented for non-inflammatory alopecia. Hair-loss begun on the head and over 1 year progressed to complete alopecia except for some hair tufts on caudal thighs. Eyelids and vibrissae were also absent. The dog was otherwise healthy.

Results: Haemogram, clinical biochemistry, serum thyroid hormones, ACTH-stimulation test and urine cortisol/creatinine ratio were within normal limits. Five skin biopsies from different regions showed a common diffuse follicular atrophic pattern and mild lymphocytic infiltration (CD3 +) involving some follicular bulbs. Differential diagnosis with other atrophic follicular diseases concluded that lesions corresponded with late stage AA causing complete alopecia.

Conclusions: We describe for the first time a case of canine AA *universalis*. This case further supports the homology between human and canine AA and the dog as a useful model to study the pathogenesis of the disease.

Poster Abstracts Other

PP-129

ACUTE ALCOHOL POISONING IN COW

Kyung-Hyun Lee*, Woo-Hee Park, Lee Hyun Kyoung, Bae You Chan, Soon-Seek yoon, Ji-youl Jung, Moon-Young Rhyoo, Young-Hwa Jean, Sun-Hee Do¹, Myoung-Heon Lee

Animal Disease Diagnosis Division, Animal and Plant Quarantine Agency, Anyangsi, Gyeonggido 430-757, Korea,

¹ *Konkuk University*

mylovehyun@korea.kr

Introduction: Acute alcohol poisoning is not uncommon in people and its consumption has given rise to serious socioeconomic problems in periods of prohibition or war and poverty stricken communities. However, it has only once been reported as a cause of death in cattle. In this case we report alcohol poisoning in hanwoo cattle.

Materials and Methods: In November 28th, and November 30th, of 2012, 20 cattle suddenly died on a cheonan hanwoo farm. After death, samples were submitted to the Animal and Plant Quarantine agency (QIA) for diagnostic investigations. After necropsy, skin samples were fixed in 10% neutral buffered formalin, embedded in paraffin wax, stained with hematoxylin and eosin (HE) for histopathology. Blood samples were submitted to the National Forensic Service to check the alcohol percentage in blood.

Results: No specific gross findings were observed from postmortem examination. However there was an intense odour of alcohol in the rumen during necropsy. Microscopic lesions were nonspecific. The test result on blood samples collected from cattle died 2~3 days ago, revealed blood alcohol concentration of 0.014-0.023%.

Discussion: This was the first case of alcohol poisoning in a cow in Korea and has been reported in the media and academia.



Poster Abstracts Other

PL-130

THE PATHOMORPHOLOGICAL PATTERN OF SODIUM CARBONATE INTOXICATION IN CHINCHILLAS – A CASE REPORT

J. Szarek, J. Wojtacka, E. Strzyżewska, I. Babińska and K. Dublan

University of Warmia and Mazury, Olsztyn, Poland

emijel@wp.pl

Introduction: Sodium carbonate is a 0.1% ingredient of feed mixes for chinchillas. The available literature does not contain any report on these animals being poisoned with sodium carbonate.

Materials and Methods: At a chinchilla farm housing 1,330 animals, losses or culling of whole herds occurred over 10 months. The cause was sodium carbonate found in a feed mix in the amount of 5.11% of the total mix. Ten chinchillas were analyzed macro- and microscopically (samples of internal organs were stained with haematoxylin and eosin).

Results: Macroscopic examination revealed cachexia, large patches of hairless skin, presence of transudate in the abdominal cavity (pH = 10) and in the pulmonary cavity (pH = 8.5), mesenteric congestion, hepatic petechiae, erosions and ulcerations (gastric mucous membrane), chronic inflammation (small intestine), congestion (lungs), adrenomegaly. Additionally, microscopic observations revealed parenchymatous degeneration (liver, kidneys), liver congestion and its adipose degeneration, necrotic foci (kidneys, sporadically liver). Damage to the apical parts of intestinal villi and their contraction were also observed. The lungs presented oedema and congestion. Skin samples sometimes showed follicular atrophy.

Conclusion: We speculate that sodium carbonate intoxication results in high levels of Na^+ , OH^- , and HCO_3^- being absorbed into blood and damaging parenchymal organs and gastrointestinal tract.

Poster Abstracts Other

PP-131

AN EOSINOPHILIC GASTROENTERITIS AND ALLERGIC ASTHMA IN A CAPTIVE CAPYBARA (HYDROCHOERUS HYDROCHAERIS)

K. Sonmez*, G. Sennazli*, A. Gurel*

**Department of Pathology, Faculty of Veterinary Medicine, Istanbul University, Istanbul, Turkey*

kivilcimsonmez@gmail.com

Introduction: A captive female adult capybara (*Hydrochoerus hydrochaeris*) with clinical history of lethargy, loss of appetite, tremors, balance disorder and sudden death was brought to Istanbul University, Veterinary Faculty, Pathology Department for necropsy. The purpose of this report is to record the presence of Allergic Eosinophilic gastroenteritis and asthma.

Materials Methods: A systemic autopsy was performed to the animal and samples from organs were collected and fixed with 10% buffered formalin solution. Samples were processed routinely and embedded in paraffin wax. 3-4µm sections were taken from each organ, stained with hematoxylin-eosin and examined under light microscope.

Results: Macroscopically edema and emphysema in the lungs and ulcers in stomach and intestines were detected. Content of the intestines was pink-reddish and sassy. Intestinal walls were thickened and the Peyer's patches were distinctive. Histopathologically eosinophilic gastroenteritis characterized with necrosis, hemorrhages and eosinophilic infiltrations and allergic asthma characterized with eosinophilic and lymphocytic infiltrations were observed.

Conclusion: The cause of death was determined as asphyxia and dehydration due to allergic asthma and necrohaemorrhagic enteritis caused by an irritation or hypersensitivity.

Poster Abstracts Other

PP-132

A CASE OF SUSPECTED STEROID RESPONSIVE MENINGITIS-ARTERITIS IN A GREYHOUND

K. E. Soerensen*, E. Karlstam* and D. Gavier-Widén*

**SVA, Department of Pathology and Wildlife Diseases, Uppsala, Sweden*

elisabeth.sorensen@sva.se

Introduction: Steroid responsive meningitis-arteritis (SRMA) is an immune-mediated disorder of unknown etiopathogenesis. It is primarily observed in juvenile dogs, however; cases in dogs as old as seven years have been reported. Affected dogs are presented with pyrexia, reluctance to move the head, severe cervical and thoracolumbal pain. Clinical signs result from combined leptomeningitis and arteritis. Furthermore, involvement of the arteries in the heart, mediastinum and thyroid glands often occurs. No specific disease markers exist for SRMA and the diagnosis is therefore presumptive.

Materials and Methods: An 8-year-old female Greyhound was euthanized due to hemiparesis and severe cervical and thoracolumbal pain. The dog was previously treated with NSAID and antibiotics for suspected myositis in the neck muscles.

Results: The main findings at necropsy were multiple firm white nodular processes on the epicardium associated to the vascular branching. Similar processes were observed in the intercostal muscles and diaphragm. Submeningeal bleedings were noted around the spinal cord primarily at the cervicothoracic transition. Histological examination revealed a necrotizing fibrinoid arteritis with severe perivascular neutrophil infiltration in the leptomeninges of the spinal cord and in the arteries of the heart, diaphragm and intercostal muscles. No causative agent could be detected by bacterial cultivation, Gram or PAS-staining.

Conclusion: On the basis of the histopathological findings and their location, negative bacteriology and clinical symptoms, a diagnosis of SRMA was suspected.

Poster Abstracts Wildlife

PP-133

PATHOLOGY OF LOGGERHEAD TURTLES (*CARETTA CARETTA*) EMBRYOS ON THE ISLAND OF LINOSA (ITALY)

S. Appino^{*}, E. Longato^{*}, M. Piria[°], E. Bollo^{*}, A. Capobianco Dondona[§], A. De Lucia[†], S. Nannarelli[†], F.E. Scaglione^{*}

^{*}Dipartimento di Scienze Veterinarie, Torino, Italy, [°]Dipartimento di Medicina Veterinaria, Sassari, Italy, [§]Istituto Zooprofilattico Sperimentale, Teramo, Italy, [†]Centro Recupero Tartarughe Marine-Hydrosphera, Lampedusa, Italy

enrico.bollo@unito.it

Introduction: The purpose of this work is to evaluate the causes of death of not hatched specimens of *Caretta caretta* from Linosa Island, Italy.

Materials and Methods: Forty-seven Loggerhead Sea Turtles (*Caretta caretta*) found dead at the opening of the nests on Linosa Island beach (Italy) in summer 2006 were examined. Biometrical measures and depth of the eggs were recorded. Samples were submitted to histological examination. July and August temperatures of Linosa Island from 2004 to 2008 were registered. Statistical analysis were performed using Fisher's exact, chi-squared and Kruskal-Wallis tests.

Results: A focal non-suppurative infiltration of the heart was observed. An increasing amount of melanomacrophages, haemorrhages and vacuolar degeneration were present in the liver. Edema was observed in the lung, as well as glomerular and tubular calcium carbonate calculosis of renal parenchyma. Statistical analysis revealed an association between nest and renal calculosis and between differences of the average temperature of July and August and the other considered years.

Conclusion: Vacuolar degeneration of the liver associated with increased melanomacrophages is indicative of a chronic inflammatory process probably due to toxicosis. The presence of calcium oxalate crystals in the kidney is believed to be linked to egg dehydration.

Poster Abstracts Wildlife

PP-134

STUDY OF LUNG STRUCTURAL DAMAGE IN WILD BOAR (*SUS SCROFA*) BY HISTOPATHOLOGICAL SCORING

J.M. Cuesta^{ab}, D. Risco^a, P. Gonçalves^a, R. Martínez^a, W.L. García^a, S. Fernández^b, J. Hermoso de Mendoza^a, P. Fernández-Llario^a, R. Velarde^c, L. Gómez^{ab}.

^aRed de Grupos de Investigación "Recursos Faunísticos" and ^bHistology and Pathological Anatomy Unit, Faculty of Veterinary Medicine, University of Extremadura, Cáceres, Spain and ^cServei d'Ecopatologia de Fauna Salvatge, Faculty of Veterinary Medicine, University of Barcelona, Barcelona, Spain

jesus.cuesta.gerveno@gmail.com

Introduction: There are many respiratory diseases that affect wild boar. This study aimed to determine structural damage in the lungs and associate this with host factors and infectious agents.

Materials and Methods: 60 wild boars were sampled during the 2011-2012 harvest season to be microbiologically tested by ELISA and PCR methods. Age and sex were also recorded. Lung tissue was microscopically studied to determine pathological score of each structure, divided in: Bronchus (Range 0-7), BALT (Range 0-4), Alveoli (Range 0-5), Interstitium (Range 0-4) and Pleura (Range 0-4). Ranges are determined by possible pathological findings affecting each structure. Statistical analysis was performed to compare the results.

Results: No statistical relationships were discovered, except for affection of the bronchus associated to age and the affection of the pleura associated to sex. However, there was a tendency to increased structural damage scores among younger animals.

Conclusions: Younger animals usually present higher pathological scores than older animals. Pleural damage is statistically significant and higher in males, probably due to behavioral factors such as aggressive behavior.

Poster Abstracts Wildlife

PP-135

STUDY OF PULMONARY INFLAMMATION IN WILD BOAR (*SUS SCROFA*) BY HISTOPATHOLOGICAL SCORING

J.M. Cuesta^{ab}, D. Risco^a, P. Gonçalves^a, R. Martínez^a, W.L. García^a, S. Fernández^b, J. Hermoso de Mendoza^a, P. Fernández-Llario^a, R. Velarde^c, L. Gómez^{ab}.

^aRed de Grupos de Investigación "Recursos Faunísticos" and ^bHistology and Pathological Anatomy Unit, Faculty of Veterinary Medicine, University of Extremadura, Cáceres, Spain and ^cServei d'Ecopatologia de Fauna Salvatge, Faculty of Veterinary Medicine, University of Barcelona, Barcelona, Spain

jesus.cuesta.gerveno@gmail.com

Introduction: Wild boar are an important reservoir of disease in wildlife populations. Lung pathology, associated with inflammation, is common in this species.

Materials and Methods: 60 wild boar were sampled during the 2011-2012 hunting season to be microbiologically tested by ELISA and PCR methods. Age and sex were also recorded. Lung tissue samples were microscopically studied for each inflammatory process (Interstitial pneumonia, broncopneumonia, bronchitis, peribronchitis and pleuritis) establishing a score depending on severity and extension of lesions (0, absent; 1, mild multifocal; 2, mild diffuse; 3, moderate multifocal; 4, moderate diffuse; 5, severe multifocal; 6, severe diffuse). Statistical analysis was performed to compare the results.

Results: No statistical relationships were discovered, except for peribronchitis associated to age. However, there was a tendency to increased inflammation score among younger animals.

Conclusions: Histopathological score is useful to study inflammatory processes in lung tissue, independently of microbiological findings. However, further information is required to determine exact relationships between wild boar pathogens, animal characteristics and pathological findings in lung inflammatory processes.

Poster Abstracts Wildlife

PL-136

ACUTE LEAD POISONING IN A GRIFFON VULTURE SECONDARY TO BULLET INGESTION

M. Carneiro*, R. Nieto[§], B. Colaço*, R. Brandão[†], R.M. Gil da Costa[‡], A. Colaço*, M. Pires*, P.A. Oliveira*, S. Lavin[§]

*University of Trás-os-Montes and Alto Douro, Vila Real, Portugal, §Universidad Autónoma de Barcelona, Barcelona, Spain, ‡Faculty of Engineering, University of Porto, Porto, Portugal, †CERVAS/ALDEIA, Gouveia, Portugal

rmcosta@fe.up.pt

Introduction: Vultures are often exposed to spent lead ammunition from carcasses of game. Exposure may have increased after the ban on abandoning carcasses of domestic ruminants in the field, because vultures consume hunting residues more frequently and because malnutrition may induce mobilization of lead stores.

Materials and Methods: An adult female griffon vulture (*Gyps fulvus*) was found in Freixo-de-Espada-à-Cinta, Portugal, showing extreme weakness, anorexia, depression and green-stained faeces, having died 24h after admittance. A blood sample was taken and, during necropsy, liver and kidney were also collected for histopathological analysis and lead detection by inductively coupled plasma mass spectrometry.

Results: Necropsy revealed crop impaction, gall-bladder and stomach distension, and right lung aspiration pneumonia. Nine lead bullets were found in the stomach. Histopathology revealed hepatocellular cytoplasmic hemosiderin accumulation. Blood, liver and kidney presented lead concentrations of 1384.4µg/dl w.w, 308.6µg/g d.w. and 34.6µg/g d.w. respectively.

Conclusions: The low gastric pH of raptors promotes the rapid dissolution and subsequent absorption of lead. Acute lead poisoning is one of the most important causes of mortality in raptors and, since the conservation status of this species in Portugal is near threatened, effective measures are needed to prevent it.



Poster Abstracts

Wildlife

PP-137

HISTOPATHOLOGICAL AND IMMUNOHISTOCHEMICAL DIFFERENCES IN GRANULOMAS PRODUCED BY *Mycobacterium bovis* IN FALLOW DEER MALES AND FEMALES NATURALLY INFECTED

W.L. García-Jiménez*, F. J. Salguero**, P. Fernández-Llario*, J. Cuesta†, P. Gonçalves*, D. Risco*, T.S. Strickland**, J. Hermoso-de-Mendoza* and L. Gómez†.

*Red de Grupos de Investigación Recusos Faunísticos, University of Extremadura, Cáceres **Animal Health and Veterinary Laboratories Agency, Weybridge, United Kingdom

†Unidad de Anatomía Patológica, Facultad de Veterinaria, University of Extremadura, Cáceres

walgarjim@unex.es

Introduction: The marked sexual dimorphism in some species of cervids, such as fallow deer (*Dama dama*), seems to have an effect on susceptibility to *M. bovis*, as evidenced by the higher prevalence found in males of this species. The aim of this study was to characterize the lesions caused by *M. bovis* in fallow deer males and females naturally infected by histopathology and immunohistochemistry.

Materials and Methods: Samples from mandibular lymph nodes and lungs of 20 wild fallow deer (10 males and 10 females) from a large hunting state in Central Spain were fixed in buffered formalin. For histopathology, H&E, von Kossa and ZN stains were used to characterize the developmental stage of the granuloma (I, II, III and IV), the number of multinucleated giant cells (MNGCs), the presence of calcium and the number of acid fast bacilli (AFBs). For immunohistochemistry, MAC387 and iNOS immune markers were used in lymph nodes samples to evaluate the role of the macrophages in males and females.

Results: Male fallow deer lesions showed higher number of granulomas with a high percentage of calcium, but less MNGCs and AFBs than females. There was not an important difference in number of MAC387+ stained cells between males and females granulomas, but the iNOS expression was higher in male's granulomas.

Conclusions: Male fallow deer have different granuloma morphology than female fallow deer.

Poster Abstracts

Wildlife

PL-138

OTOLITHIASIS IN AFRICAN LIONS (*Panthera leo*)

E. Mozos*, P. Ginel,†A. Diz*, B. Blanco†J. Negrini*, R. Guerra‡, M. Novales†

*Department of Anatomy and Comparative Pathology and †Department of Medicine and Surgery. University of Córdoba. ‡Zoological Garden of Córdoba. Spain

an1momoe@uco.es

Introduction: Otoliths are osseous concretions found in the middle ear. They have been described in dogs associated with otitis media and vestibular disease but also as incidental findings. They have not been recorded in cats and others felines (Paterson & Tobias 2013). The aim of this study was to describe otolithiasis in captive African lions.

Materials and Methods: five skulls from deceased adult African lions (three males and two females), donated to the Museum of Anatomy of the Department of Comparative Anatomy and Pathology of the University of Córdoba, were used for radiographic (X-ray), computerized tomography (CT), gross and histopathology study.

Results: X-ray study of the 5 skulls revealed mineralized structures compatible with middle ear otoliths in 4 ears; a further CT scan evidenced that middle ear otoliths were present in 7 of the 10 ears examined. Grossly, they appeared as rounded or spicular bone-like structures attached to the tympanic bullae walls, variable in number and size. Microscopically, otoliths were composed by a matrix of cancellous bone which was continuous with the tympanic bulla bone.

Conclusions: Postmortem unilateral or bilateral otolithiasis was incidentally observed in the majority of the captive lion studied. CT scanning provided better diagnostic sensitivity than radiography. Otoliths were composed of mature osteoid tissue produced from the bone lining the tympanic bulla.

Poster Abstracts

Wildlife

PP-139

CONGENITAL NERVOUS SYSTEM MALFORMATION IN A STILLBORN BROWN BEAR (URSUS ARCTOS)

J. F. García Marín[‡], L. Polledo[‡], C. Zapico[‡], A. Balseiro^{*}

[‡] Animal Health Department, University of León,, Spain, [‡]Fundacion Oso Pardo Asturias, Spain and ^{*}SERIDA, Asturias, Spain

jfgarm@unileon.es

Introduction: Malformations in the development of neural tube have been described associated with different causes, such as genetic factor, toxic plants, chemical products or viral agents. Moreover, the advanced age of the mother increased the risk of these congenital anomalies.

Materials and Methods: A 24-years-old female brown bear that had always lived in captivity and been kept under food and management control, gave birth to a stillborn cub at the end of gestation. Necropsy and histopathological studies were carried out.

Results: Severe lesions in CNS and skull were found characterized by anencephaly with cranium bifidum. Likewise spinal cord showed mielodysplasia with segmental aplasia in cervical and thoracic segment, hypoplasia and central canal defect such as absence, atresia and multiple canals.

Conclusions: Various malformations resulting from an anomalous development of the neural tube in a bear not previously reported to our knowledge in this species are described here. The very advanced age of the mother was more than likely the main cause.

Poster Abstracts Wildlife

PP-140

***CLOSTRIDIUM SORDELLII* MYOSITIS AND SEPTICEMIA IN A BROWN BEAR (*URSUS ARCTOS*)**

A. Balseiro*, A. Oleaga[†], L. Polledo[‡], G. Aduriz[§], R. Atxaerandio[§], N. Cortabarria[§], J. F. García Marín[‡]

*SERIDA, Asturias, Spain and [†]SERPA, Asturias, Spain and [‡]Pathological Anatomy Section, Animal Health Department, University of León, Spain and [§]NEIKER Tecnalia, Bizkaia, Spain

jfgarm@unileon.es

Introduction: *Clostridium sordellii* is a species found in the environment and occasionally in animal and human intestine, which causes myonecrosis and large outbreaks of enterotoxemia. There are very few case descriptions of fatal clostridial infection in bear species worldwide, none of them being attributed to *C. sordellii*.

Materials and Methods: An adult male brown bear was trapped in an illegal trap by left front paw. The animal showed depression and died. At necropsy, samples were taken from different organs for histopathology, bacteriological and molecular studies (PCR).

Results: Acute gangrenous myositis was the main lesion present. Hemorrhages were also observed in heart, stomach, intestine, liver, spleen and kidney. Microscopically, lesions consisted mainly of myonecrosis and vascular damage with presence of clostridial-like bacilli. *C. sordellii* was identified in cultures from liver, muscle, stomach and intestine. Sequences obtained showed a homology of >99% with the 16S rRNA gene sequence of *C. sordellii*.

Conclusions: Development, speed and seriousness of effects triggered off by *C. sordellii* reported in the bear studied reveal the importance of this pathogenic agent as a sanitary risk, and the need to take it into account in any management entailing immobilization, stress or severe muscular activity of wild brown bears.

Poster Abstracts Other

PP-141

Safety Study of a Convertase-armed Oncolytic Measles Virus in Transgenic Mice and Rhesus Macaques

Iris M. Völker*, Patricia Bach*, Ulrich Lauer[¶], Christian J. Buchholz*

* Paul-Ehrlich-Institut, Division of Medical Biotechnology, Langen, Germany

[¶] Uni-Klinik Tübingen, Department of Internal Medicine, Tübingen, Germany

Introduction: Genetically engineered measles viruses (MV) have the ability to destroy human liver cancer cells (oncolysis), but their safety profile has to be determined. In this study a convertase-armed vaccine MV was tested in two animal models for intrahepatic application.

Materials and Methods: IFNAR^{-/-}CD46TM mice express the human MV receptor and rhesus macaques are a well characterized model for research on MV. Both species were injected with a convertase armed MV and its corresponding prodrug. Subsequently samplings were performed till study end day 93. MV biodistribution was monitored via qRT-PCR, antibodies by ELISA and toxic effects by blood count, clinical chemistry and histology.

Results: After injection MV RNA was detected in every tested organ of mice or in spleen of rhesus macaques. Both species developed antibodies against viral antigens and the convertase. Single dose was well tolerated, whereas repeated injections induced hemolysis in mice.

Conclusions: A single dose of convertase-armed measles virus was safe in both species tested. However, repeated injections caused adverse effects and have to be clarified.

ISVD Mystery Slide Session

MYSTERY CASE #1:

Judith Nimmo, ASAP Pathology, Victoria, Australia

A 4 year old male Maltese-cross dog had a > 2 year history of pruritic skin disease that had been treated with antibiotics, topical antifungal drugs, prednisolone and for the past 2 months with Atopica (cyclosporin A). The dog presented with a severe, progressive liquefactive cellulitis of the right foreleg. Despite aggressive antibiotic therapy the leg had to be amputated 2 weeks later.

MYSTERY CASE #2:

Christina McCowan, University of Melbourne, Werribee, and Environment and Primary Industries, Bundoora, Australia

A common ringtail possum (*Pseudocheirus peregrinus*, Boddaert 1785) was trapped in the course of a surveillance project in south eastern Australia. The animal was lethargic and had scabbed and ulcerative lesions on face, feet and tail, with swelling of the nasal bridge, one hand, wrist and hock. The possum was euthanased and submitted for autopsy.

The swollen hock yielded yellowish mucoid discharge; no bacteria were found on routine culture. Viscera were grossly unremarkable.

The section provided is from the swollen hand, not at the site of ulceration.

MYSTERY CASE #3:

Dominique Wiener, Vetsuisse-Faculty, University of Bern, Switzerland

“Noblesse”, a 5 year old male, neutered domestic cat was presented with erythema, crusts and ulcerations around the left eye. In addition high grade pruritus and a severe conjunctivitis were present. Systemic treatment with corticosteroids and antibiotics was not helpful. The animal was reported to be frequently involved in fights with animals and was treated for fighting wounds and abscesses for several times in the past.

ISVD Mystery Slide Session

MYSTERY CASE #4:

Judith Nimmo, ASAP Pathology, Victoria, Australia

A 10 year old spayed female Labrador retriever was presented with an ulcerative lesion on nasal planum on the dorsal aspect of left naris that been present about a month. There had been no response to a week of antibiotics. There was no nasal discharge and the nasal mucous membranes looked normal on scoping. The nasal planum also appeared hyperplastic and dry.

MYSTERY CASE #5:

Monika Welle, Vetsuisse Faculty, University of Bern, Switzerland

An otherwise bright bull calf presented with extensive epidermal loss at all four fetlocks directly after birth. The skin defects extended rapidly and subsequently involved the entire distal limbs, the muzzle, the periocular area, the base of the ears and the oral cavity. The calf developed dysungulation affecting two claws during the first hours of life. Eight hours after birth the calf was recumbent and unable to stand up. It was euthanized on humane grounds due to the severity, extent and progression of the lesions.

MYSTERY CASE #6:

Nadine Meertens, Animal Health Service, Deventer, The Netherlands

Cato is a 1-year-old dog, female, Labrador x Belgian shepherd cross breed. She had a well-circumscribed raised lesion, partly bullous, hemorrhagic, covered by an adherent crust, measuring 5 x 10 cm on the bridge of the nose, which was more or less bilaterally symmetrical. According to the owner, the lesion appeared suddenly and progressed rapidly.

MYSTERY CASE #7:

Verena Affolter, University of California, Davis, USA

Nine-year-old Hanoverian gelding presented with bilateral non-symmetric alopecia on shoulder, elbow and neck. Lesions were not pruritic. For the most part, skin surface of the alopecic areas appeared normal and skin scrapings were negative. Very few small papules were noted within haired and non-haired areas. Lesions extended to other body areas and mane and tail became progressively alopecic.

ISVD Mystery Slide Session

MYSTERY CASE #8:

Emily Walder, Independent Slide Consultation Service, Venice, CA, USA

Jacob is a 4-year-old, neutered male Chihuahua with a 4 month history of a nonpruritic, alopecic patch on the top of the head. More recently, a similar lesion with mild erythema and scale developed near the base of the right pinna. DTM and skin scrapes were negative. There was no response to Revolution or ivermectin.

MYSTERY CASE #9:

Emily Walder, Independent Slide Consultation Service, Venice, CA, USA

Sadie is a 7-year-old, neutered female Pomeranian with a history of moderate pruritus, partial to complete alopecia and scale on dorsal neck and trunk. She has polyuria/polydipsia and low T4. Low-dose dexamethasone suppression and ACTH stimulation tests were within normal limits.



Providing veterinary pathologists with consistent, reproducible H&E staining and high-quality, efficient ePathology solutions.

With the Leica ST Infinity System consistently delivering high quality stains, in the detail that veterinary pathologists demand and the Aperio® AT2 increasing collaboration and multi-site productivity, why look any further?



Aperio® AT2

- 400 slide capacity, low footprint scanner
- Fewer slide rescans
- Capture eSlides of an entire carousel in under 7 hours
- Affordable, high quality, high throughout scanning



Leica ST Infinity H&E Staining System

- High quality, high definition H&E staining
- Consistent staining from slide 1 to 2,000
- Unique chemistry and reagent stability
- Reduce staining costs and increase throughput



2nd Joint European Congress of the ESVP, ESTP and ECVP



32nd meeting of the ESVP
12th meeting of the ESTP
25th meeting of the ECVP

27th - 30th August 2014
Berlin, Germany

ESTP TOPIC

*TOXICOPATHOLOGY OF THE ENDOCRINE
AND ENDOCRINE REGULATED ORGANS*

JOINT KEYNOTE LECTURES

- ANIMAL DISEASE CONTROL – DO WE STILL NEED PATHOLOGISTS?
- PREDICTING DISEASE OUTCOME AND THERAPY RESPONSE IN ANIMAL CANCER: MORPHOLOGY, IMMUNOHISTO-CHEMICAL MARKERS OR MOLECULAR SIGNATURES - WHAT TO CHOOSE?
- PATHOLOGY OF THE SPINAL CORD
- NANOPATHOLOGY: REVOLUTION IN MATERIAL AND DRUG SCIENCE AND ITS IMPACT ON VETERINARY PATHOLOGY
- ENDOCRINE AND ENDOCRINE REGULATED ORGANS

www.cuttingedgepathology.net
cuttingedge2014@fu-berlin.de